

Case Report

Chang-Hwan Kim, M.D.

Seong Ho Kim, M.D.

Min-Soo Kim, M.D.

Chul-Hoon Chang, M.D.

Department of Neurosurgery
College of Medicine
Yeungnam University
Daegu, Korea

Cubital Tunnel Syndrome, Associated With Synovial Chondromatosis

A 62-year-old female patient suffered from numbness and resting pain in the right ring and little fingers for 3 years. We confirmed cubital tunnel syndrome with electrodiagnostic study and performed the operation. We found seven firm consistent nodules, compressing the overlying the ulnar nerve, proximal to the medial epicondyle in the operation field. Histological finding showed synovial chondromatosis. We report a rare case of a patient with cubital tunnel syndrome caused by synovial chondromatosis.

KEY WORDS : Cubital tunnel syndrome · Synovial chondromatosis.

INTRODUCTION

Synovial chondromatosis is a rare, non-neoplastic, mono-articular, and uncommon benign condition of unknown origin. The knee is the most commonly affected joint, and followed by the elbow, hip, and shoulder, although any other joint may be involved. We present a rare case of synovial chondromatosis, associated with cubital tunnel syndrome.

CASE REPORT

A 62-years-old female patient suffered from numbness and resting pain in the right ring and little fingers for 3 years. She had a positive Tinel's sign on the posterior area of right medial epicondyle in the physical examination. On the electrodiagnostic study, nerve-conduction velocity of the ulnar nerve was delayed around the cubital tunnel compatible with cubital tunnel syndrome. Preoperative radiograph of the elbow showed osteophyte formation in the medial epicondyle (Fig. 1).

In the operative field, we released the aponeurosis between two heads of flexor carpi ulnaris and performed mini-medial epicondylectomy for slightly hypertrophied medial epicondyle. Although anterior transposition of ulnar nerve was tried after the release of tunnel, the ulnar nerve was still under tension at the proximal portion of the elbow. Further proximal dissection revealed seven firm and white-to-yellowish nodules, compressing the overlying the ulnar nerve, proximal to the medial epicondyle (Fig. 2). Histological finding was that the nodule is composed with hyaline cartilage covered by synovial cells, and ossifications (Fig. 3). The tension of ulnar nerve was relieved after removal of these masses. The patient's symptom was improved throughout 15 months following that operation.

DISCUSSION

Synovial chondromatosis is a rare, non-neoplastic, mono-articular and cartilaginous metaplasia of synovial membrane of joints, bursae and tendon sheaths. The most commonly affected site is the knee joint³, though it has been observed in nearly all peripheral joints including the elbow^{7,9,11}, wrist, knee³, spinal facet joint^{2,5}, hip^{4,8}, and temporo-mandibular joint^{1,6}.

Cubital tunnel syndrome is caused by compression with cubital tunnel component like an aponeurosis of

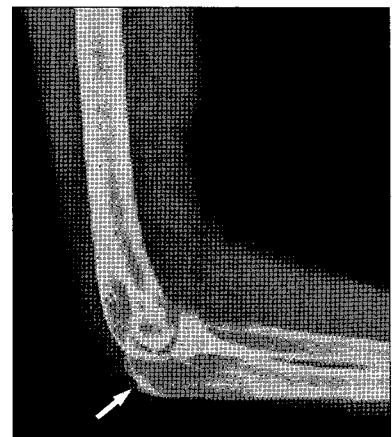


Fig. 1. Preoperative simple radiograph of the right elbow shows osteophyte formation.

- Received : November 5, 2007
- Accepted : February 11, 2008
- Address for reprints :
Seong Ho Kim, M.D.
Department of Neurosurgery
College of Medicine
Yeungnam University
317-1 Daemyeong-dong
Nam-gu, Daegu 705-717, Korea
Tel : +82-53-620-3790
Fax : +82-53-620-3770
E-mail : shkim@medical.yu.ac.kr

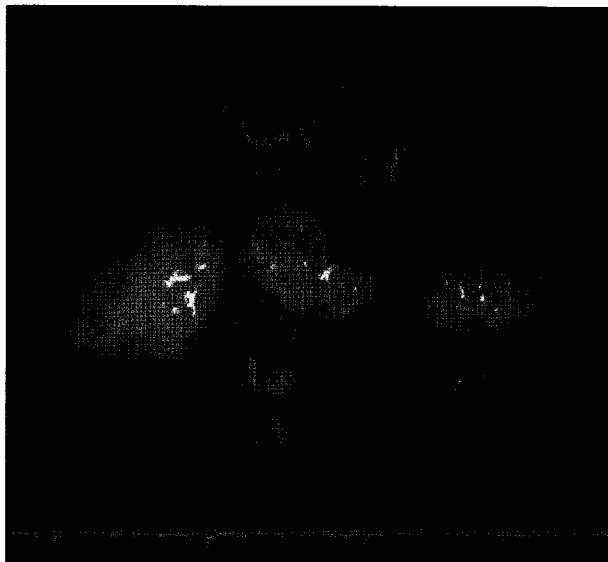


Fig. 2. The specimen consists of seven white to yellowish, firm nodules, measuring 1.0×0.7 cm in largest one.

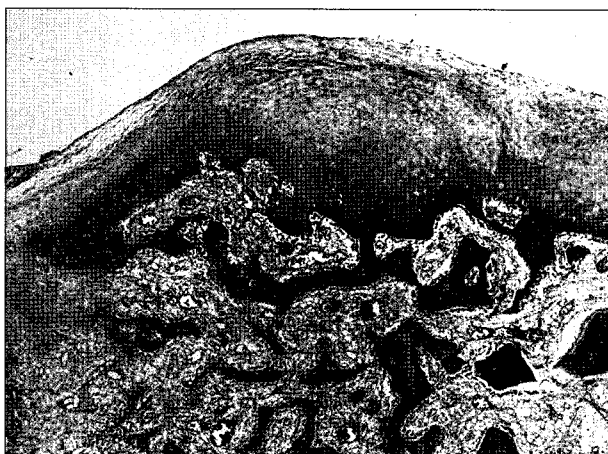

Fig. 3. The nodules show hyaline cartilage covered by synovial cells, and ossifications ($\times 200$).

flexor carpi ulnaris and a medial epicondyle, but several authors reported that cubital tunnel syndrome is unusually caused by a mass compressing ulnar nerve⁷. Kato et al.⁷ reported that medial elbow ganglia are associated with osteoarthritis of the elbow and can also cause acute onset of cubital tunnel syndrome and the prevalence of this lesion among patients with cubital tunnel syndrome is about 3 to 19%. Other report have shown that the compressive ulnar neuropathy is caused by synovial chondromatosis like this report⁹. Most masses causing cubital tunnel syndrome are found on the operative fields, though a rare synovial chondromatosis is detected on the preoperative simple X-ray⁹.

Magnetic resonance (MR) images can be used to diagnose synovial chondromatosis⁸. MR images show intra-articular bodies of low focal signal intensity at all pulse sequences, with areas of isointensity at T1 and hyperintensity at T2-weighted images. This preoperative diagnostic method helps to identify pathology and to make a precise diagnosis. However, MR imaging is not a usual diagnostic method for cubital tunnel syndrome although it helps in making a plan for operation if synovial chondromatosis is preoperatively detected.

CONCLUSION

Primary synovial chondromatosis is one of the causes for cubital tunnel syndrome. It is not usually identified by electrodiagnostic study and simple radiography. More sensitive diagnostic modalities such as magnetic resonance images is considered for precise preoperative diagnosis and for complete removal.

References

1. Araneidan L, Faquir W, Trollies mP, Kazan LB, August M : Synovial chondromatosis of the temporomandibular joint : Report and analysis of eleven cases. *J Oral Maxillofac Surg* 63 : 941-947, 2005
2. Chiba S, Koge N, Oda M, Yamauchi R, Imai T, Matsumoto H, et al : Synovial chondromatosis presenting with cervical radiculopathy. *Spine* 28 : E396-E400, 2003
3. Church JS, Bredahl WH, Janes GC : Recurrent synovial chondromatosis of the knee after radical synovectomy and arthrodesis. *J Bone Joint Surg* 88 : 673-675, 2006
4. David AD, Megan L, Troxell, Michael F : Synovial chondromatosis in an elite cyclist : A case report. *Arch Phys Med Rehabil* 87 : 860-865, 2006
5. Gallia GL, Weiss N, Campbell JN, McCarthy EF, Tufaro AP, Gokaslan ZL : Vertebral synovial chondromatosis. Report of two cases and review of the literature. *J Neurosurg Spine* 1 : 211-218, 2004
6. Holmlund AB, Eriksson L, Reinholt FP : Synovial chondromatosis of the temporomandibular joint : Clinical, surgical and histological aspects. *Int J Oral Maxillofac Surg* 32 : 143-147, 2003
7. Kato H, Hirayama T, Minami A, Iwasaki N, Hirachi K : Cubital tunnel syndrome associated with medial elbow ganglia and osteoarthritis of the elbow. *J Bone Joint Surg* 84 : 1413-1419, 2002
8. Kim SH, Hong SJ, Park JS, Cho JM, Kim EY, Ahn JM, et al : Idiopathic synovial osteochondromatosis of the hip : Radiographic and MR appearances in 15 patients. *Korean J Radio* 3 : 254-259, 2002
9. Mueller T, Barthel T, Cramer A, Werner A, Gohlke F : Primary synovial chondromatosis of the elbow. *J Shoulder Elbow Surg* 9 : 319-322, 2000
10. Osterman AL, Davis CA : Subcutaneous transposition of the ulnar nerve for treatment of cubital tunnel syndrome. *Hand Clin* 12 : 421-433, 1996
11. Sharma RR, Pawar SJ, Delmento A, Mahaparta AK : Symptomatic epineural ganglion cyst of the ulnar nerve in the cubital tunnel : a case report and brief review of the literature. *J Clin Neurosci* 7 : 542-543, 2000