

## Case Report

Hai-Ong Lee, M.D.  
Eun-Jeong Koh, M.D.  
Young-Min Oh, M.D.  
Ha-Young Choi, M.D.

Department of Neurosurgery  
Research Institute for Clinical  
Medicine, Chonbuk National  
University Medical School/  
Hospital, Jeonju, Korea

## Midline Glioblastoma Multiforme With Bilateral Symmetric Cysts

Cystic glioblastoma multiforme (GBM) is a rare disease. Its exact prevalence has not yet been reported. Also, the mechanism of cyst formation remains to be elucidated. We report a case of GBM with a large peripheral cyst. A 43-year-old woman visited our clinic with a 3-month history of severe headache, memory impairment and general weakness. T1-weighted gadolinium-enhanced magnetic resonance (MR) image revealed a midline enhanced solid mass and bilateral symmetric banana-shaped peripheral cysts. A centrally enhanced mass was measured  $2 \times 4$  cm in size and both mass and cysts as  $7 \times 7$  cm. Both the frontal lobe and the frontal horn were severely compressed inferiorly and posteriorly. We resected a midline solid tumor and cysts via the bilateral interhemispheric transcortical approach. Histopathologic examination revealed GBM. The patient was subsequently treated with fractionated conventional brain radiation therapy, followed by temozolomide chemotherapy. Eighteen months later, there was no tumor recurrence and no neurological deficits were noted. Our patient showed no tumor recurrence and a long survival at a long follow-up.

**KEY WORDS :** Glioblastoma multiforme · Cyst · Prognosis.

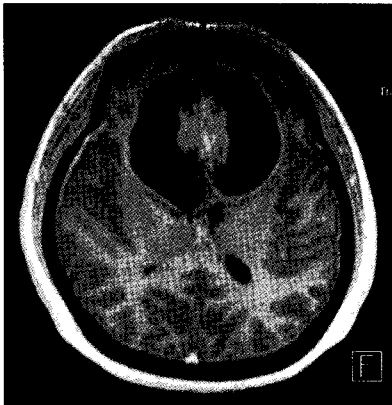
### INTRODUCTION

Glioblastoma multiforme (GBM) usually occurs as a unilateral solitary tumor in the cerebral hemisphere. The presence of associated cysts is rare and the prevalence of cystic GBM has not yet been reported. Maldaun and his colleagues have reported that patients with a GBM that contains a large cyst survive longer and have a longer time to recurrence than those who lack such a cyst<sup>4</sup>. Several reports have indicated that cystic GBM is less infiltrative than non-cystic GBM with a better prognosis<sup>1,3,6</sup>. However, the mechanism of cyst formation remains to be elucidated. The hypotheses of cyst formation include necrotic degeneration of the tumor tissue, central hemorrhage with subsequent liquefaction, entrapment of adjacent cerebrospinal fluid (CSF) and plasma fluid leaking from a local disruption of the blood-brain barrier<sup>2,6,7</sup>. We report a case of cystic GBM which showed no tumor recurrence at a long follow-up.

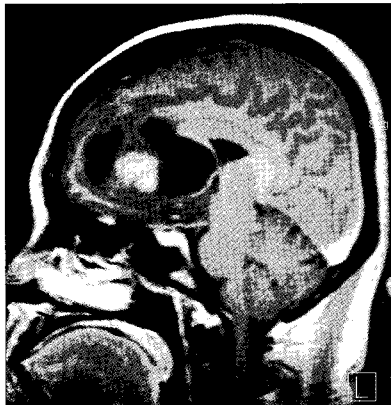### CASE REPORT

A 43-year-old woman presented with a 3-month history of severe headache, memory disturbance and general weakness. Neurological deficits were not noted on neurological examination. Computed tomography (CT) revealed a homogeneously enhanced mass in the midline and lesions with peripheral low density in the bilateral frontal areas. MR imaging revealed a moderately enhanced interhemispheric mass and bilateral symmetric banana-shaped peripheral cysts. The enhanced mass was measured  $2 \times 4$  cm in size and the solid portion and bilateral cysts measured as  $7 \times 7$  cm (Fig. 1). The cystic wall was not enhanced. Both frontal lobe and frontal horn were severely compressed laterally and posteriorly (Fig. 2). Peritumoral edema was observed diffusely at the base of the frontal bone and pericystic area had an edema measuring several millimeters (Fig. 3). Transfemoral carotid angiography (TFCA) did not show any tumor blushing. We performed gross total surgical resection of the tumor mass and cystic walls via the bilateral interhemispheric transcortical approach. Cystic fluid was clear and brown. No tumor cells were found in the cystic fluid and its chemical components were similar to those of CSF except that it had a high protein level (260 mg/dl). Since the cystic wall showed no tumor cell infiltrations, it was left undisturbed. The tumor was gray-purple and friable. Histopathological findings were suggestive of GBM (mitosis with nuclear atypia, microvascular proliferation and ischemic necrosis) (Fig. 4). After operation,

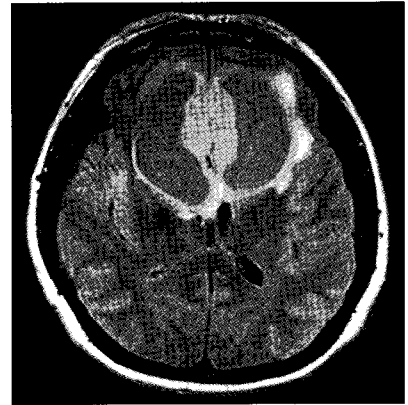
- Received : October 23, 2007
- Accepted : January 16, 2008
- Address for reprints :  
Eun-Jeong Koh, M.D.  
Department of Neurosurgery  
Research Institute for Clinical  
Medicine, Chonbuk National  
University Medical School/Hospital  
634-18 Geumam-dong, Deokjin-gu  
Jeonju 561-712, Korea  
Tel : +82-63-250-1870  
Fax : +82-63-277-3273  
E-mail : dmsqfms@paran.com



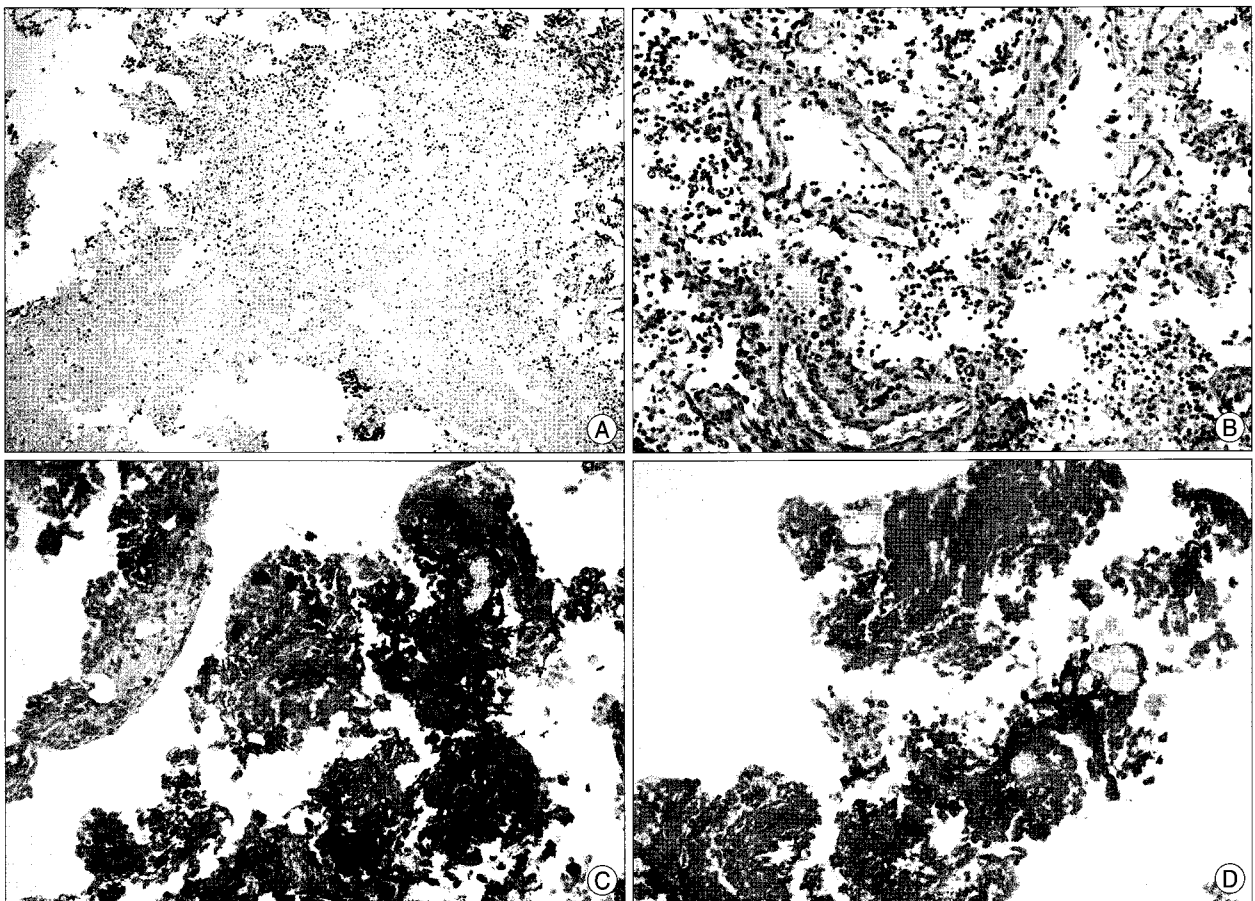
**Fig. 1.** Axial T1-weighted magnetic resonance imaging with gadolinium enhancement demonstrates a 2×4 cm interhemispheric mass and 7×7 cm bilateral symmetric banana-shaped peripheral cysts.



**Fig. 2.** Sagittal T1-weighted magnetic resonance imaging with gadolinium enhancement displays a tumor compressing bilateral frontal lobes and bilateral frontal horns laterally and posteriorly.



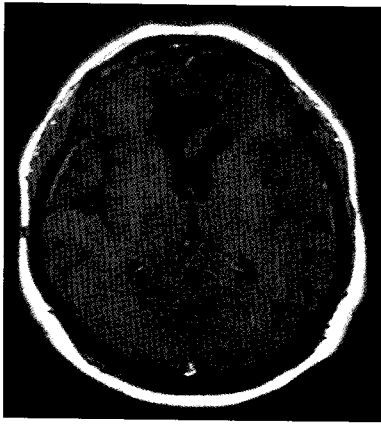
**Fig. 3.** Magnetic resonance FLAIR imaging shows peritumoral and pericystic edema.



**Fig. 4.** Photomicrography of the tumor discloses aggregations of ischemic necrosis (A) and microvascular proliferation (B). Immunohistochemical stains for vimentin (C) and GFAP (D) reveal positive reactions (A-D, H&E, original magnification ×200).

her symptoms improved and these were no neurological deficits. One month after operation, MR imaging revealed disappearance of preoperative edematous area of the frontal lobe and the pericystic area showed no abnormal signals. The patient was subsequently treated with fractionated

conventional brain radiation therapy (LINAC). Twenty-five fractionations of 200 cGy were administered once daily, and followed by four cycles of temozolomide chemotherapy (200 mg/m<sup>2</sup>). There was no tumor recurrence on the follow-up brain MR images which was obtained 18 months after



**Fig. 5.** Follow-up axial T1-weighted magnetic resonance imaging with gadolinium enhancement reveals no tumor recurrence.

operation (Fig. 5). She had no neurological deficits.

## DISCUSSION

Cysts are commonly found in low-grade astrocytomas (>50% of the cases) and in most pilocytic astrocytomas. In these low-grade tumors, cysts correlate with

a better prognosis. Cysts may develop in high-grade tumors but the presence of cysts in GBMs is extremely rare. The cause of cyst formation is unknown. Satoshi et al.<sup>6</sup> have suggested pathophysiologic mechanisms for cyst formation in glioma are peritumoral vasogenic brain edema, ischemia, tumor necrosis and fluid resorption. One hypothesis regarding cyst formation is that GBM is a malignant transformation of a previously undiagnosed cystic low-grade glioma<sup>2,6</sup>. GBMs have been reported to arise from low-grade astrocytomas in approximately 20% of the cases. These “secondary” GBMs tend to occur in younger patients (median age, 45 years) who have a long history of seizures and have genetic and molecular patterns different from those of so-called “primary” or de novo GBMs. Secondary GBMs sequentially show p53 mutation, PDGF-A and PDGFR- $\alpha$  overexpression, LOH 19q and RB alteration, and loss of LOH 10 and DCC expression. In primary GBM, overexpression and amplification of EGFR and MDM2, PTEN mutation, and p16 deletion developed simultaneously<sup>2</sup>. Our patient had no history of chronic seizure and a short duration of symptoms. She was clinically diagnosed with primary GBM. Since we did not perform chromosome analysis, we could not determine whether this tumor was primary or secondary GBM. Other hypotheses have been suggested to explain the presence of cysts in GBMs. These include necrotic degeneration of the tumor tissue (extensive necrosis of the central part of the tumor or necrosis along with the surrounding pseudopalisading structures of the tumor), central hemorrhage with subsequent liquefaction, entrapment of the adjacent cerebrospinal space, and a blood-brain barrier disruption<sup>2,6,7</sup>. In our case, since MR imaging showed a central tumor and bilateral peripheral cysts, we postulated that the cysts occurred through necrosis with the surrounding pseudopalisading structures of the tumor or entrapment of the adjacent cerebrospinal space, not through central tumor necrosis or central hemorrhage.

MR findings in our case showed that the cystic wall was not enhanced and had a narrow peritumoral edema. This supports the hypothesis of entrapment of the adjacent cerebrospinal space. Chemical components of the cystic fluid similar to those of CSF except for a high protein level support the hypothesis of CSF entrapment. The propensity of glial tumors that invade the normal brain is one of their hallmarks. GBMs typically invade the adjacent brain tissue. This invasion frequently occurs in the white fiber tracts, along the blood vessels, by subependymal dissemination, or through the subpial space<sup>7</sup>. Tumor infiltration is thought to cause early postoperative recurrence and disease progression despite aggressive resection<sup>1,3,5,7</sup>. Previous histological studies in which the relationship of the cyst wall with the brain was analyzed have demonstrated that cystic GBMs appear to have a relatively narrow pericystic rim of the glioma, with limited infiltration of the surrounding neutrophils. This result indicates that cystic GBMs may be less infiltrative than non-cystic ones<sup>6</sup>. Such histological changes may be related to a proposition for lower recurrence of the tumor and a longer overall survival after surgery in patients with cystic GBMs. Our patient also showed a narrow pericystic edema with a sharp margin.

The extent of surgical resection is also a significant prognostic factor for GBM. The larger the peritumoral edema region is, the poorer the prognosis is. Since peritumoral edema extends in three dimensions, surgical removal is difficult and involves a high risk of creating new neurologic deficits. Although resection of the peritumoral edematous region improves treatment outcomes of GBM, complete resection of the edematous region is extremely difficult to perform<sup>1,3,5</sup>. In our patient, she had a narrow pericystic edema and a cystic wall which provided the boundary for tumor resection, thus resulting in complete resection and good surgical outcomes. Maldaun et al. estimated that the median survival time after surgery was 18.2 months in patients with cystic GBM, whereas it was 14.3 months in patients with non-cystic GBM<sup>4</sup>. They also showed that no recurrence was observed in 45% of the patients at 1 year after surgery and 38% of patients at 2 years after surgery, whereas the corresponding numbers for patients with non-cystic GBM was 14% and 9%, respectively<sup>4</sup>. At follow-up, our patient showed no recurrence 18 months after surgery.

## CONCLUSION

We report a patient with a central GBM mass containing a large peritumoral cyst with narrow pericystic edema. The definite cystic wall and scanty pericystic edema provided the boundary of tumor resection and allowed complete resection

of the tumor. Postoperatively, recurrence-free survival time was longer in our case than that of non-cystic GBMs.

### References

1. Hulshof MC, Koot RW, Schimmel EC, Dekker F, Bosch DA, Gonzalez D : Prognostic factors in glioblastoma multiforme : 10 years experience of a single institution. *Strahlenther Onkol* 177 : 283-290, 2001
2. Kleihues P, Ohgaki H : Primary and secondary glioblastomas : From concept to clinical diagnosis. *Neuro-oncol* 1 : 44-51, 1999
3. Lacroix M, Abi-Said D, Fourney DR, Gokaslan ZL, Shi W, DeMonte F, et al : A multivariate analysis of 416 patients with glioblastoma multiforme : prognosis, extent of resection, and survival. *J Neurosurg* 95 : 190-198, 2001
4. Maldaun MV, Suki D, Lang FF, Prabhu S, Shi W, Fuller GN, et al : Cystic glioblastoma multiforme : survival outcomes in 22 cases. *J Neurosurg* 100 : 61-67, 2004
5. Park JW, Hwang JH : The long-term survival in patients with anaplastic astrocytoma or glioblastoma. *J Korean Neurosurg Soc* 34 : 514-520, 2003
6. Satoshi U, Hidehiro O, Sachio S, Satoru S, Yoshinori T, Koji K, et al : Pathological and clinical features of cystic and noncystic glioblastomas. *Brain Tumor Pathol* 23 : 29-34, 2006
7. Thorsen F, Tysnes BB : Brain tumor cell invasion, anatomical and biological considerations. *Anticancer Res* 17 : 4121-4126, 1997