

Review Article

Young Il Jeon, M.D.¹Do Hoon Kwon, M.D.²

Department of Neurosurgery¹
 Gil Hospital, Gachon University
 of Science and Medicine
 Incheon, Korea

Department of Neurosurgery²
 Asan Medical Center
 College of Medicine
 University of Ulsan
 Seoul, Korea

Current Status and Future Prospect of Endovascular Neurosurgery

Recently, due to the evolution of technology, the field of neurosurgery is receiving spotlight. In particular endovascular neurosurgery has gained a great interest along with the advancement of the modern neurosurgery. The most remarkable advances were made in embolization of the cerebral aneurysms, arteriovenous malformations and intracranial stenosis during the past 10 years. These advances will further change the role of neurosurgeons in treating cerebrovascular disease. Because interventional neuroradiologists have performed most of procedures in the past, neurosurgeons have been deprived of chances to learn endovascular procedure. This article discusses the development of technological aspect of endovascular neurosurgery in chronological order. By understanding the history and current status of the endovascular surgery, the future of neurosurgery will be promising.

KEY WORDS : Endovascular surgery · Embolization · Aneurysm · Arteriovenous malformation · Intracranial stenosis.

INTRODUCTION

Endovascular treatment of cerebrovascular disease has been evolving over decades. Recent advances of science and technology, especially introduction of the detachable coil system in early 1990's, turned this restrictive tool into the most noticeable and promising technology in modern neurosurgical field. The progression of technology has been too fast with overwhelming amount of information on the treatment method making it very difficult to keep updated.

This article provides the basic principles and technologies that have not been changed during past decades in spite of the technological advances. It also provides comprehension of new technologies and materials, which have been recently introduced in the field of endovascular neurosurgery.

General Idea of Endovascular Neurosurgery

Endovascular surgery is a minimally invasive surgery, because it requires very small incision and exposure. It is also a remote surgery because the materials are manipulated through microcatheter and wire outside the body far from the target. In the future, endovascular surgery can be performed by robots operated by remote control and connect. Endovascular technique is less invasive than other neurosurgical techniques.

However, endovascular neurosurgery becomes more complicated as the technology advances. In the early stage, single microcatheter was required to deliver the coil into aneurysms. But, these days, the artery is usually congested with multiple catheters, balloon or stent for the treatment of challenging aneurysms. Thus, procedure does not seem to be 'simple and safe' anymore. However it is becoming better with advanced products and techniques.

To be a revolutionary diagnostic method, safety was required for the percutaneous carotid arteriogram since it was introduced by Moniz in early 1920's⁶³. Use of Iodine and catheter navigation through the femoral artery established fundamental safety and thereafter every efforts have been made to more improve the safety of the materials and technology⁸³.

Safety of the endovascular procedure is also based on the safe angiography. Endovascular products, like angiographic products, have been improved to be less traumatic to the arterial wall, less thrombogenic, and more controllable to navigate the arterial system easily.

Endovascular treatment of cerebrovascular disease includes occlusion of the lesion; aneurysm, arteriovenous malformations (AVMs), arteriovenous fistulas (AVFs), and preoperative embolization

- Received : September 12, 2007
- Accepted : January 21, 2008
- Address for reprints :
 Do Hoon Kwon, M.D.
 Department of Neurosurgery
 Asan Medical Center
 College of Medicine
 University of Ulsan
 388-1 Pungnap2-dong
 Songpa-gu, Seoul 138-736, Korea
 Tel : +82-2-3010-3550
 Fax : +82-2-476-6738
 E-mail : ykwon@amc.seoul.kr

Table 1. Classification of endovascular procedure

Method	Procedure	Materials*	Comment
Occlusion	Aneurysm	Detachable coils	
	AVMs	nBCA	Onyx [†]
	AVFs	Coils, balloon	
	Tumors	PVA particles	
Opening	Atherosclerotic stenosis	Stent	Intracranial stent [†]
	Acute thrombosis	tPA, urokinase, platelet GP IIb/IIIa inhibitors	Stent or balloon for mechanical opening
	Vasospasm	Balloon	
Delivery	Vasospasm	Papaverin	Calcium channel blockers
	Chemotherapy ^{20,24,50)}	ACNU, etc.	Various chemotherapeutic agents with osmotic BBB disruption
	Stem cell implantation ²⁾		Experimental

*Commonly used materials, † Currently not available in Korea

of head and neck tumors, opening of the lesion; atherosclerotic stenosis, acute thrombogenic occlusion, angioplasty for vasospasm, delivery to the target; chemical angioplasty for vasospasm, delivery of anticancer drugs, delivery of stem cells, etc. (Table 1)

Endovascular neurosurgery has been evolving along with improving endovascular materials and advancement in techniques to apply these materials to the target. Introduction of new materials have led improvement of treatment result. For example, detachable coil system has been substituted for detachable balloon in treatment of cerebral aneurysm and n-Butyl-Cyanoacrylate (nBCA) for Polyvinyl Alcohol (PVA) particles in cerebral arteriovenous malformation. Improvement of clinical results encouraged people to expand indications of endovascular neurosurgery from proximal to distal arteries and from simple to complex lesions.

Several terms describing these procedures have been used without distinction : intervention, endovascular surgery, endovascular treatment, intravascular treatment. Although interventional neuroradiology had an initiative in this field, endovascular neurosurgery is a more comprehensive term in the point of neurosurgeon's view because many neurosurgeons do these procedures by themselves instead of consulting to interventional neuroradiologist for intervention. Actually, the idea of intervention includes all therapeutic procedures using X-ray and percutaneous access as well as intravascular approach. There are many similar procedures in neurosurgery such as spinal nerve or vertebral facet block, epidural injection, vertebroplasty and kyphoplasty, balloon compression of trigeminal ganglion, etc. These procedures and other stereotactic neurosurgical procedures are not called as intervention in neurosurgical field. Therefore, it is better to use 'endovascular neurosurgery' rather than 'neurointervention' for the neurosurgeon's procedure performed through the vascular system.

SCIENCE AND TECHNOLOGY

Endovascular products include coils, liquid embolic materials, stents, and balloons as well as catheters and wires for access and delivery. Successful treatment needs both selection of adequate materials for the target and working safely and effectively with them. Coils are useful to occlude aneurysms immediately and to induce endothelialization over the neck. This could not be achieved with other embolic materials. In contrast, glue is the most effective material to penetrate

the nidus of the AVM and to maintain permanent occlusion. This propensity had been settled by repeated process of selection, test, and discard.

From 1991, Guglielmi Detachable Coil system (Target/Boston Scientific, Fremont, CA) rapidly substituted the detachable balloon system which had been widely used in the treatment of cerebral aneurysms since its first introduction by Serbinenko at the end of 1960's^{28-31,84)}. The balloon had limitations of size and shape and occasional shrinking associated with recurrence or distal embolism. Liquid embolic materials such as cyanoacrylate, which have no limitation in size and shape were tested as a solution of these problems^{19,47,69)}. But, in the absence of appropriate methods to control rapid polymeric reaction and to protect parent artery from leakage of the glue and adhesiveness, these experimental techniques did not attain much of clinical attention. Recently, liquid embolization of cerebral aneurysms using nonadhesive high viscosity material (Onyx), has been performed in some European centers. Although Onyx (Micro Therapeutics, Irvine, CA, USA) is more controllable with balloon or stent than cyanoacrylate, it is not comparable to detachable coils in technical confidence, complication, and recurrence^{12,13,62,67,89,101)}.

Not selected frequently in the treatment of the aneurysm, detachable balloon and glue are still useful in other endovascular procedure. Detachable balloon is the first choice for treatment of traumatic carotid artery cavernous sinus fistula (CCF) and therapeutic occlusion of the internal carotid artery. Glue is a principal material to embolize the arteriovenous malformation. Several problems of cyanoacrylate such as catheter gluing, difficulty in nidus penetration, and inhomogeneity of the glue cast are almost resolved in Onyx.

Intracranial angioplasty, with stent insertion, has been a challenge for a long time because the coronary stent is too stiff to overcome tortuosity of intracranial artery. Two types of stents have been developed for intracranial use. One is

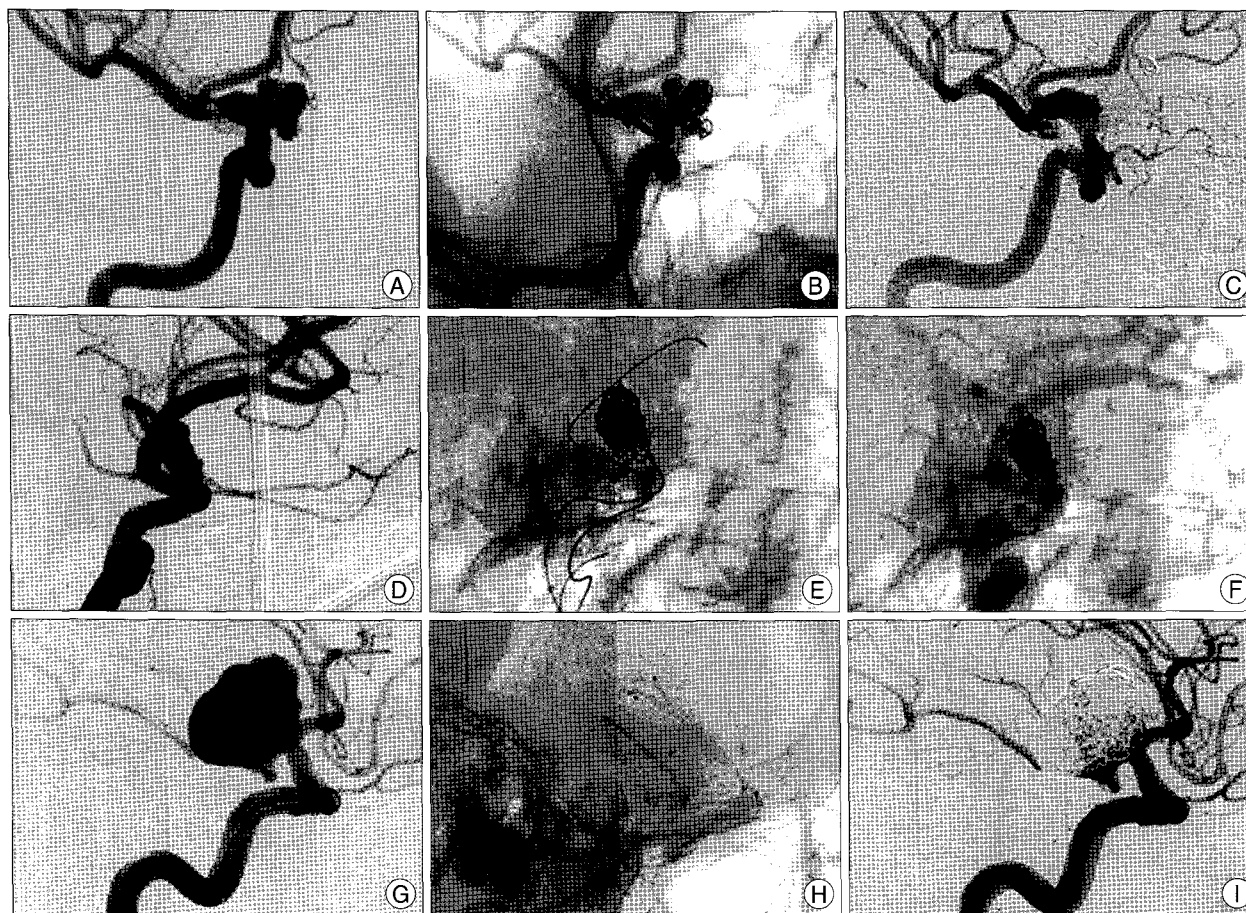


Fig. 1. Detachable coil embolization of complex aneurysms. Stent assisted embolization (A, B, C). A : Before treatment. Previously, posterior communicating artery (PcoA) aneurysm clipped, B : After treatment with Neuroform stent. C : 6 months follow up. Balloon assisted embolization (D, E, F). D : Before treatment. E : During treatment, a balloon was placed across the neck. F : After treatment, a stent also deployed to reinforce the neck area. Multiple catheter technique (G, H, I). G : Before treatment. PcoA arises from the aneurysm sac. H : Three catheters in the sac with different direction. I : Subtotal occlusion to preserve PcoA.

for neck remodeling technique of broad neck aneurysm and the other is for angioplasty of atherosclerotic stenosis. Finally, endovascular neurosurgery is equipped with all line-ups of proper products for neurovascular application and the newest materials such as Onyx and intracranial stents are expected to be available between 2007 and 2008 in Korea. Prospects of endovascular neurosurgery can be discussed from viewpoints of materials, skills and techniques, and clinical results.

In spite of repeated modification and development of new products, the platinum has been the principal material consisting detachable coil through the endovascular history. Early platinum coils, which had variations only in diameter and length have advanced and branched into complex-shaped three-dimensional coils to improve aneurysm packing and expand application to wide neck aneurysm. At the same time, 'neck remodeling techniques' using balloons or stents applied to broad neck complex aneurysm. But, this advancement, by contraries, brought out the weakness of coil embolization. Coil compaction and recanalization of completely occluded

aneurysm has been a main problem of embolization and increased case of embolization also increased the absolute number of compaction or regrowth. To solve these problems, coils were modified with polymers to add more therapeutic effect on platinum coil. These modifications include enhancing endothelialization, increasing packing density, and promoting thrombosis in the aneurysm.

Neck remodeling techniques had been performed exclusively by several highly experienced experts because controlling non-neurovascular balloons or stents was very difficult. Fatal complications during learning curve made these techniques unapproachable. But, introduction of neurovascular balloons and stents that were more easy to use and less dangerous made this technique more popular.

Currently, the advancement of technology lowered degree of difficulty of the procedure as well as improved clinical result. With numerous better materials, creative combination of several materials could be tested.

Multiple catheter technique delivering several coils

simultaneously can make a complex frame that is useful in wide neck or complex shaped aneurysm. This technique provides stability of coil mesh in wide neck aneurysm because multiple catheters uphold the coil and prevent herniation. It also decreases the incomplete packing by placing an additional catheter in the corner of the aneurysm to where coil packing is difficult with single catheter. The balloon and stent, which have been used separately, can be applied synergically because the balloon increases packing density and the stents enhances neck healing. So, diversity of application can improve the results or make a demand on manufacturer to develop new materials (Fig. 1).

Endovascular neurosurgery highly depends on technology as well as surgeon's skill. Creative idea also contributes evolution of technology.

In overall, endovascular environment changes rapidly and the most remarkable progresses have been made in treatment of cerebral aneurysms, arteriovenous malformations, and intracranial atherosclerotic stenosis.

CEREBRAL ANEURYSMS

Until 1990's, detachable balloon embolization of cerebral aneurysm had contributed significantly to complications. Higashida et al.³⁷⁾ reported that among 215 aneurysms treated with detachable balloons, only 40.9% of the aneurysms could be occluded selectively and the rest was treated with parent artery occlusion. The report concluded that this procedure was useful for surgically difficult aneurysms in spite of their surgical mortality of 9.8% and stroke incidence of 7.4%.

In 1991, Guglielmi Detachable Coil system introduced and changed the paradigm of the embolization. With this system, almost every parent artery could be preserved while occluding aneurysm sac more comfortably. The idea of selective aneurysm embolization was finally realized after 30 years of vigorous exertion. Once the idea was translated, this procedure has advanced rapidly by support of technology.

Detach coil embolization, like balloon embolization, was also an intravascular procedure however with has risks of stroke or vascular injury. The risk of stroke, especially thromboembolism, moved from large arteries such as internal carotid or vertebrobasilar artery to smaller branches by use of coils. Defects in products and poor skills were the reason for vascular injury and aneurysm rupture during the procedure. But, in selected aneurysm groups, coil embolization showed and maintained superiority compared to microsurgery. Naturally, with improvement of the products, applications of endovascular procedure began to expand. Therefore, until late 1990's, one of the major concerns for endovascular surgery was the relationship between geometry of the aneurysm

and success of the embolization. Complex-shaped three-dimensional coils were better than simple helical shaped coil in treating wide neck or complex aneurysm. But, the inherent limitation of the coils resulted in the increased use of stents or balloons. At that time, navigating intracranial arteries with stents or balloons was very difficult and dangerous because those products were hard and stiff only suitable for coronary artery. But, because the idea of stent or balloon assisted neck remodelling was the only solution for complex and wide neck aneurysm, manufacturer finally developed new type of stents and balloons for only this purpose. The 2000's were the era of balloon and stents that had expanded indications of aneurysm embolization.

The international Subarachnoid Hemorrhage Aneurysm Trial (ISAT) was the largest prospective randomized study which had compared coiling with clipping. In spite of criticism, this study verified that the coil embolization could be a primary method to treat cerebral aneurysm regardless of its location⁶¹⁾. Several studies, which had followed ISAT to insist superiority of each method, could not reach an agreement because these studies also, like ISAT, had shortness of patient selection bias, small cases, unequal numbers of each procedure, or different experiences of participators^{26,38,44)}. In 2007, Campi et al.¹¹⁾ compared retreatment rate of patients enrolled in ISAT. In 1096 coiled patients, retreatment rate was 17.4% in mean 20.7 month and rebleeding rate was 0.6%. On the contrary, among 1012 clipped patients, only 3.8% of them were retreated in mean 5.7 months and rebleeding rate was 0.3%. Young age, large parent artery, and incomplete occlusion were considered to be contributing factors that predispose retreatment.

Pandey et al.⁷³⁾ reported procedure related mortality and morbidity 5.1% in their 10 years experience of 275 patients from 1995. Complete or near complete occlusion more than 95% were achieved in 87.8% of the aneurysms and recanalization occurred in 24.5% of whom 4.9% required retreatment. In another series of van Rooji et al.,⁹⁸⁾ morbidity 2.6%, 1.3% mortality, 94.5% of >90% occlusion rate, recanalization rate of 16.2% and 14.3% retreatment. Higashida et al.³⁸⁾ analysed 2535 patients treated by clipping or coiling in 429 hospitals in United States from 1998 to 2000. They concluded endovascular surgery has advantages of shorter inpatient course as well as lower costs, furthermore mortality and morbidity were 0.9% and 6.6% that lower than 2.5% and 13.2% of clipping cases (Table 2).

Studies comparing usefulness of coiling and clipping may not be very useful because the prospective randomized studies don't necessarily represent all cases equally and its significance is not widely accepted. Moreover, endovascular environment may already been changed with newer products when the

Table 2. Results of aneurysm embolization

Author	Mortality	Morbidity	Rebleeding	Retreatment
Campi et al.			0.6%	17.4%
			0.3%*	3.8%*
Pandey et al.				4.9%
Van Rooji et al.	1.3%	2.6%		14.3%
Higashida et al.	0.9%	6.6%		
	2.5%*	13.2%*		

*Results of clipping

randomized study has completed because progression of technology was very rapid in endovascular field. Endovascular surgery is no more competitor of microsurgery. Neurosurgeons should regard endovascular surgery as a new tool helping them to treat aneurysms safely and easily since the advantages and disadvantages of the coiling and the clipping have been witnessed. Judicious application of these treatment options will improve the clinical outcome.

Debates on endovascular surgery of cerebral aneurysms include natural course and long term effect of completely or incompletely occluded aneurysms, effectiveness of coiling of giant or very small aneurysm, endovascular treatment of aneurysms having mass effect or cranial nerve symptoms, and usefulness of modified coil.

One of the key issues of coil embolization is how many aneurysms recur after complete occlusion and how many aneurysms rupture due to recurrence. Healing of the aneurysm completed when the aneurysm excluded from the parent artery by endothelialization across the neck⁵⁹. But, this endothelialization may occur incompletely as a thin membrane on the surface of the coil^{78,79}. This effect based on animal study and human case was rarely reported⁴⁰. Incomplete endothelialization across the neck may pose weakness to continuous hemodynamic forces and prone to compaction of coil mesh or recurrence of the aneurysm. Bleedings after complete occlusion were usually related to coil compaction, migration, and dislocation³.

With high coil packing density, coil compaction rarely occurs and the aneurysm immediately occluded completely⁹⁷. The lowest packing density to prevent coil compaction has been reported as about 24%^{46,85,88}. On the contrary, the maximum coil packing density was reported as 37% and packing more coils above this level is very difficult⁷⁵. The difference between minimum and maximum coil packing density is so small that the effort to increase the coil packing density by more coil insertion may not be always successful. This situation requires modified coils to prevent compaction and enhance aneurysm healing with same coil packing density.

Matrix coil system (Boston Scientific, Fremont, CA) was the first modified coil of which the platinum coil surface was coated with polyglycolic/lactide copolymer. This copolymer

promotes clot organization in the aneurysm sac and eventually enhances aneurysm fibrosis and endothelialization over the neck^{65,66}. Cerecyte coil system (Micrus Endovascular, San Jose, CA) was similar to Matrix in composition but the copolymer was loaded inside the platinum coil loop.

Hydrogel is the another type of copolymer, which was adopted in Hydrocoil (MicroVention, Aliso Viejo, CA). This polymer was also coated on the surface of platinum coil and expands more than twofold in the blood increasing packing density^{18,25}.

These modified coils have not been used widely in spite of several positive results because handling of these coils were not easy as bare platinum coils and the polymers sometimes caused chemical reaction such as aseptic meningitis when different type of copolymers were used in combination^{17,45,48}.

On the contrary to recanalization of completely occluded aneurysm, incompletely treated aneurysms having residual sac or residual neck often show progressive thrombosis and complete occlusion especially in very small aneurysms or aneurysms treated with modified coils^{17,34,45,48}.

Rebleeding rate after embolization with bare platinum coils reported from 0.45% to 1.27% and the modified coils assumed to have similar rate^{11,51,64,87}. Therefore, image follow up is necessary to detect recanalization, compaction, and regrowth early before rebleeding.

Giant aneurysm has been treated by selective coil occlusion of the aneurysm sac or parent artery occlusion with or without aneurysm occlusion. Proximal artery occlusion reverses the flow direction and decreases the stress to the aneurysm sac. These hemodynamic changes finally induce shrinkage of the sac or cease further growth or rupture of the aneurysm⁵⁴. Sometimes, severe stroke occurs after proximal occlusion in spite of negative balloon occlusion test. Rarely, rapid thrombosis in the sac after blood flow disruption aggravates mass effect of giant aneurysm⁹.

Selective coil occlusion of the giant aneurysm usually resulted coil compaction with the rate up to 70%^{27,86}. Some giant aneurysms located distal to the circle of Willis show good results in occlusion, decreasing mass effect, and less recurrence⁶. But, in general, coil embolization of giant aneurysm is less effective in decreasing mass effect and instead may aggravate the mass effect especially in vertebrobasilar system. Proximal occlusion of giant aneurysm in vertebrobasilar system is effective in decreasing mass effect, but rebleeding may occur unless the aneurysm is trapped⁵⁵. Trapping is the most effective method to decrease mass effect and prevent rebleeding because it completely excludes a aneurysm from blood flow⁷².

Temporary balloon occlusion of parent artery during microsurgery may be useful as an adjunct of clipping⁸⁰.

Stent graft has shown good result in some cases of giant aneurysm but still experimental^{41,74}.

Early detection of very small aneurysms has been increased due to advancement of non-invasive imaging development but treatment of these aneurysms is still controversial. Coil embolization of small aneurysms less than 3 mm in diameter is technically difficult. It is often difficult to achieve complete occlusion because only one or two short coils can be inserted in these aneurysms. But, progressive thrombosis and complete occlusion have been reported with low recurrences^{34,52,92}.

Oculomotor nerve palsy by posterior communicating artery aneurysm usually recovers after successful embolization. Some of them recover incompletely, but there is no difference with clipping in recovery rate. Incomplete occlusion of the aneurysm is the main reason of incomplete or no recovery. Reappearance of resolved symptom indicates aneurysm regrowth^{1,5,8,14,39,91,103}. Visual field deficit caused by optic nerve compression by the aneurysm did not recover well whatever the treatment is. These aneurysms are usually very large; therefore coil embolization may not decrease the mass effect^{70,71}.

Balloon assisted neck remodeling techniques is frequently used after introduction of low profile balloon^{58,81}. This technique is useful in embolization of wide neck or complex neck aneurysms, and also can avoid life-long use of antiplatelet agents. Stenting after balloon assisted coiling was reported to provide better long-term occlusion rate than only stent assisted coil embolization^{21,57,68,82,93}.

CEREBRAL ARTERIOVENOUS MALFORMATIONS

Embolization of cerebral AVMs is now in transition due to development of non-adhesive liquid embolic system. There always have been significant complications related to this procedure since when Luessenhop introduced AVM embolization using spheres in 1960. Old data show high morbidity varying from 1.4% to 50% and mortality from 0.9% to 4%. But, recent experiences using nBCA show decreased morbidity from 6.5% to 18.3% and mortality from 0.7% to 2%^{32,33,49,53,56,60,76,95}.

These are still high because increasing complication rate by this treatment in multidisciplinary treatment is rarely tolerable (Table 3).

The nBCA, which has been the most useful liquid embolic agent for a long time despite its awkward adhesiveness, is now being replaced by non-adhesive liquid embolic materials, the Onyx¹⁶.

Non-adhesiveness of the Onyx can be explained by its precipitation reaction rather than polymerization of nBCA.

Table 3. Results of AVM embolization

Period	Materials	Morbidity*	Mortality	
Old	Before Mid 80' s and Early 90' s	Various	1.4-50%	0.9-4%
Recent	After Mid 80' s	nBCA	6.5-18.3%	0.7-2%
New	After 2000	Onyx	4-14.2%	0-2.3%

*Usually means permanent neurological deficits excluding transient deficit and product related complications such as catheter gluing

When the Onyx contacts with blood or arterial wall, outer layer harden but the center still remains to be gel state for a significant time. Therefore, it can be injected with time without severe catheter gluing. It also solidifies like a sponge to make a uniform cast in the artery, so it makes less recurrence and is easy to cut with microsurgical instrument. The Ethylen-co-Vinyl Alcohol (EVAL or EVOH), which is the main material composing the Onyx, was first introduced in cerebral AVM embolization in 1990 by Taki et al.⁹⁴ EVAL requires Dimethyl Sulfoxide (DMSO) as a solvent to solve copolymer. DMSO has significant toxicity and induces severe vasospasm when injected in artery. This toxicity can be prevented when the DMSO injected less than the rate of 0.1 ml/min. FDA approved the Onyx, which is composed of EVAL in DMSO solution and Tantalum powder for radiopacity for treatment of cerebral AVMs in 2005.

The Onyx still has a significant procedure related complication rate similar to nBCA^{23,35,42,99,100}. But, it could decrease the total number of procedures per a patient and increase nidus occlusion rate significantly. The Onyx may increase the number of AVMs that could be cured by embolization only and may improve the result of postembolization microsurgery and radiosurgery. Although the Onyx is close to the ideal liquid embolic material, the risks related to the use of DMSO should be improved.

Partial embolization of cerebral AVMs may increase or decrease bleeding or rebleeding rate^{7,96}. Rebleeding rate after embolization varies from 2.0% to 8.7% and the volume reduction less than two third or 90% was pointed as a cause of rebleeding^{33,36,77,102}. But these reports were based on the nBCA experiences, and the Onyx is expected to decrease rebleeding.

INTRACRANIAL STENOSIS

In Comparison of Warfarin and Aspirin for Symptomatic Intracranial Arterial Stenosis (WASID) study, 19.7% patients who had more than 50% of intracranial artery stenosis and had been treated with aspirin had recurrent ischemic stroke within 2 years¹⁵. As an alternative treatment for these patients, warfarin had no superiority to aspirin. Clopidogrel for High Atherothrombotic Risk and Ischemic Stabilization,

Management and Avoidance (CHARISMA) study also showed that combination of aspirin and clopidogrel did not significantly decrease ischemic stroke than aspirin only⁴⁾. Therefore, medically intractable patients need more effective treatment. The intracranial arterial stenting with antiplatelet agents can be another solution.

Intracranial stents have been applied to the medically intractable intracranial artery stenosis in foreign country for several years. There are many kinds of intracranial stents and they are divided into two types; self-expandable, and balloon-expandable.

The advantages of these stents have improved the safety and stent delivery success rate.

The Gateway Balloon-Wingspan Stent System (Boston Scientific, Natick, MA) deploys self-expandable stent after predilatation with balloon. Procedure success rate has been reported be 98.8% and the procedure related major complication and death rate 6.1% in US multicenter experiences, in 82 lesions of 78 patients²²⁾. The 6 month follow up results shows, ipsilateral stroke/death rates of 4.5%, 7% at 30 day, 6 month respectively, and overall mortality 2.3%¹⁰⁾.

Apollo stent (MicroPort Medical, Shanghai, China) is a balloon expandable intracranial stent and showed 91.7% procedure success rate, 6.5% 30-day stroke rate, and 25% restenosis⁴³⁾.

Stenting of Symptomatic Atherosclerotic Lesions in the Vertebral or Intracranial Arteries (SSYLVA) study enrolled 61 patients and treated their intracranial artery and extracranial vertebral artery stenosis with balloon expandable NEUROLINK intracranial stent system (Guidant, Santa Clara, CA). SSYLVA showed 95% procedure success rate, 6.6% and 7.3% of recurrent stroke rate at 30 days and 1 year respectively, and 32.4% of restenosis of intracranial artery (>50% stenosis)⁹⁰⁾.

Some of these intracranial stents will be available in Korea by 2008.

ENDOASCULAR NEUROSURGERY IN KOREA

Currently, over 80 centers in Korea run endovascular team for cerebrovascular disease. However, interventional neuroradiology is still being dominant, despite increasing number of neurosurgeons in their activities. About 10 hospitals run neurosurgical teams and in about 20 hospitals, neurosurgical teams work with interventional neuroradiology. Seven hospitals have endovascular fellowship program for neurosurgeons and 6 neurosurgeons are currently in the training course. The ratio of interventional neuroradiologist to endovascular neurosurgeon is about 2.5 : 1. Out of 80 centers, 10% are not associated with universities. This ratio

will be increased because angiography equipment is now easily available and properly trained physicians are increasing.

At the beginning of 1996, less than 100 cerebral aneurysms were treated with coils, but this number increased to 2, 200 by 2006, more than 20 times increase within 10 years. Considering procedures performed to other cerebrovascular disease, endovascular treatment has significantly contributed to the modern neurosurgery.

The Korean Intravascular Neurosurgery Study Group met in 1995 and later changed its name to KSIN (Korean Society of Intravascular Neurosurgery). It hosts monthly and annual scientific meetings. It also publishes the biannual magazine "The Journal of Korean Society of Intravascular Neurosurgery" (April and October).

References

1. Ahn JY, Han IB, Yoon PH, Kim SH, Kim NK, Kim S, et al : Clipping vs coiling of posterior communicating artery aneurysms with third nerve palsy. *Neurology* 66 : 121-123, 2006
2. Amar AP, Zlokovic BV, Apuzzo ML : Endovascular restorative neurosurgery : a novel concept for molecular and cellular therapy of the nervous system. *Neurosurgery* 52 : 402-412; discussion 412-403, 2003
3. Asgari S, Wanke I, Schoch B, Stolke D : Recurrent hemorrhage after initially complete occlusion of intracranial aneurysms. *Neurosurg Rev* 26 : 269-274, 2003
4. Bhatt DL, Fox KA, Hacke W, Berger PB, Black HR, Boden WE, et al : Clopidogrel and aspirin versus aspirin alone for the prevention of atherothrombotic events. *N Engl J Med* 354 : 1706-1717, 2006
5. Bhatti MT, Peters KR, Firment C, Mericle RA : Delayed exacerbation of third nerve palsy due to aneurysmal regrowth after endovascular coil embolization. *J Neuroophthalmol* 24 : 3-10, 2004
6. Biondi A, Jean B, Vivas E, Le Jean L, Boch AL, Chiras J, et al : Giant and large peripheral cerebral aneurysms : etiopathologic considerations, endovascular treatment, and long-term follow-up. *AJNR Am J Neuroradiol* 27 : 1685-1692, 2006
7. Biondi A, Le Jean L, Capelle L, Duffau H, Marsault C : Fatal hemorrhagic complication following endovascular treatment of a cerebral arteriovenous malformation. Case report and review of the literature. *J Neurooradiol* 33 : 96-104, 2006
8. Birchall D, Khangure MS, McAuliffe W : Resolution of third nerve palsy after endovascular management of aneurysms of the posterior communicating artery. *AJNR Am J Neuroradiol* 20 : 411-413, 1999
9. Blanc R, Weill A, Piotin M, Ross JB, Moret J : Delayed stroke secondary to increasing mass effect after endovascular treatment of a giant aneurysm by parent vessel occlusion. *AJNR Am J Neuroradiol* 22 : 1841-1843, 2001
10. Bose A, Hartmann M, Henkes H, Liu HM, Teng MM, Szikora I, et al : A novel, self-expanding, nitinol stent in medically refractory intracranial atherosclerotic stenoses : the Wingspan study. *Stroke* 38 : 1531-1537, 2007
11. Campi A, Ramzi N, Molyneux AJ, Summers PE, Kerr RS, Sneade M, et al : Retreatment of ruptured cerebral aneurysms in patients randomized by coiling or clipping in the International Subarachnoid Aneurysm Trial (ISAT). *Stroke* 38 : 1538-1544, 2007
12. Cekirge HS, Saatci I, Geyik S, Yavuz K, Ozturk H, Pamuk G : Intracranial combination of metallic coils and onyx liquid embolic agent for the endovascular treatment of cerebral aneurysms. *J Neurosurg* 105 : 706-712, 2006
13. Cekirge HS, Saatci I, Ozturk MH, Cil B, Arat A, Mawad M, et al : Late angiographic and clinical follow-up results of 100 consecutive aneurysms treated with Onyx reconstruction : largest single-center experience. *Neuroradiology* 48 : 113-126, 2006
14. Chen PR, Amin-Hanjani S, Albuquerque FC, McDougall C, Zabramski JM, Spetzler RF : Outcome of oculomotor nerve palsy

- from posterior communicating artery aneurysms : comparison of clipping and coiling. *Neurosurgery* 58 : 1040-1046; discussion 1040-1046, 2006
15. Chimowitz MI, Lynn MJ, Howlett-Smith H, Stern BJ, Hertzberg VS, Frankel MR, et al : Comparison of warfarin and aspirin for symptomatic intracranial arterial stenosis. *N Engl J Med* 352 : 1305-1316, 2005
 16. Chun YI : Embolization of Cerebral Arteriovenous Malformations; An update. *J Korean Society Endovascular Neurosurgery* 2 : 26-36, 2007
 17. Cloft HJ : HydroCoil for Endovascular Aneurysm Occlusion (HEAL) study : 3-6 month angiographic follow-up results. *AJNR Am J Neuroradiol* 28 : 152-154, 2007
 18. Cloft HJ, Kallmes DF : Aneurysm packing with HydroCoil Embolic System versus platinum coils : initial clinical experience. *AJNR Am J Neuroradiol* 25 : 60-62, 2004
 19. Debrun GM, Varsos V, Liszczak TM, Davis KR, Heros RS, Zervas NT : Obliteration of experimental aneurysms in dogs with isobutylcyanoacrylate. *J Neurosurg* 61 : 37-43, 1984
 20. Doolittle ND, Miner ME, Hall WA, Siegal T, Jerome E, Osztic E, et al : Safety and efficacy of a multicenter study using intraarterial chemotherapy in conjunction with osmotic opening of the blood-brain barrier for the treatment of patients with malignant brain tumors. *Cancer* 88 : 637-647, 2000
 21. Fiorella D, Albuquerque FC, Deshmukh VR, McDougall CG : Usefulness of the Neuroform stent for the treatment of cerebral aneurysms : results at initial (3-6-mo) follow-up. *Neurosurgery* 56 : 1191-1201; discussion 1201-1202, 2005
 22. Fiorella D, Levy EI, Turk AS, Albuquerque FC, Niemann DB, Aagaard-Kienitz B, et al : US multicenter experience with the wingspan stent system for the treatment of intracranial atheromatous disease : periprocedural results. *Stroke* 38 : 881-887, 2007
 23. Florio F, Lauriola W, Nardella M, Strizzi V, Vallone S, Trossello MP : Endovascular treatment of intracranial arterio-venous malformations with Onyx embolization : preliminary experience. *Radiol Med (Torino)* 106 : 512-520, 2003
 24. Fortin D, Gendron C, Boudrias M, Garant MP : Enhanced chemotherapy delivery by intraarterial infusion and blood-brain barrier disruption in the treatment of cerebral metastasis. *Cancer* 109 : 751-760, 2007
 25. Gaba RC, Ansari SA, Roy SS, Marden FA, Viana MA, Malisch TW : Embolization of intracranial aneurysms with hydrogel-coated coils versus inert platinum coils : effects on packing density, coil length and quantity, procedure performance, cost, length of hospital stay, and durability of therapy. *Stroke* 37 : 1443-1450, 2006
 26. Gerlach R, Beck J, Setzer M, Vatter H, Berkefeld J, Du Mesnil de Rchemont R, et al : Treatment related morbidity of unruptured intracranial aneurysms - Results of a prospective single centre series with an interdisciplinary approach during a 6 year period (1999-2005). *J Neurol Neurosurg Psychiatry*, 2007
 27. Gruber A, Killer M, Bavinzski G, Richling B : Clinical and angiographic results of endosaccular coiling treatment of giant and very large intracranial aneurysms : a 7-year, single-center experience. *Neurosurgery* 45 : 793-803; discussion 803-804, 1999
 28. Guglielmi G, Vinuela F, Briganti F, Duckwiler G : Carotid-cavernous fistula caused by a ruptured intracavernous aneurysm : endovascular treatment by electrothrombosis with detachable coils. *Neurosurgery* 31 : 591-596; discussion 596-597, 1992
 29. Guglielmi G, Vinuela F, Dion J, Duckwiler G : Electrothrombosis of saccular aneurysms via endovascular approach. Part 2 : Preliminary clinical experience. *J Neurosurg* 75 : 8-14, 1991
 30. Guglielmi G, Vinuela F, Duckwiler G, Dion J, Lylyk P, Berenstein A, et al : Endovascular treatment of posterior circulation aneurysms by electrothrombosis using electrically detachable coils. *J Neurosurg* 77 : 515-524, 1992
 31. Guglielmi G, Vinuela F, Sepetka I, Macellari V : Electrothrombosis of saccular aneurysms via endovascular approach. Part 1 : Electrochemical basis, technique, and experimental results. *J Neurosurg* 75 : 1-7, 1991
 32. Hartmann A, Pile-Spellman J, Stapf C, Sciacca RR, Faulstich A, Mohr JP, et al : Risk of endovascular treatment of brain arteriovenous malformations. *Stroke* 33 : 1816-1820, 2002
 33. Haw CS, terBrugge K, Willinsky R, Tomlinson G : Complications of embolization of arteriovenous malformations of the brain. *J Neurosurg* 104 : 226-232, 2006
 34. Hayakawa M, Murayama Y, Duckwiler GR, Gobin YP, Guglielmi G, Vinuela F : Natural history of the neck remnant of a cerebral aneurysm treated with the Guglielmi detachable coil system. *J Neurosurg* 93 : 561-568, 2000
 35. He HW, Jiang CH, Liu HB, Li YX, Zhang JB, Wu ZX : Endovascular treatment of cerebral arteriovenous malformations with Onyx embolization. *Chin Med J (Engl)* 118 : 2041-2045, 2005
 36. Heidenreich JO, Hartlieb S, Stendel R, Pietila TA, Schlattmann P, Wolf KJ, et al : Bleeding complications after endovascular therapy of cerebral arteriovenous malformations. *AJNR Am J Neuroradiol* 27 : 313-316, 2006
 37. Higashida RT, Halbach VV, Dowd CF, Barnwell SL, Hieshima GB : Intracranial aneurysms : interventional neurovascular treatment with detachable balloons--results in 215 cases. *Radiology* 178 : 663-670, 1991
 38. Higashida RT, Lahue BJ, Torbey MT, Hopkins LN, Leip E, Hanley DF : Treatment of unruptured intracranial aneurysms : a nationwide assessment of effectiveness. *AJNR Am J Neuroradiol* 28 : 146-151, 2007
 39. Inamasu J, Nakamura Y, Saito R, Kuroshima Y, Ohba S, Ichikizaki K : Early resolution of third nerve palsy following endovascular treatment of a posterior communicating artery aneurysm. *J Neuroophthalmol* 22 : 12-14, 2002
 40. Ishihara S, Mawad ME, Ogata K, Suzuki C, Tsuzuki N, Katoh H, et al : Histopathologic findings in human cerebral aneurysms embolized with platinum coils : report of two cases and review of the literature. *AJNR Am J Neuroradiol* 23 : 970-974, 2002
 41. Islak C, Kocer N, Albayram S, Kizilkilic O, Uzma O, Cokyuksel O : Bare stent-graft technique : a new method of endoluminal vascular reconstruction for the treatment of giant and fusiform aneurysms. *AJNR Am J Neuroradiol* 23 : 1589-1595, 2002
 42. Jahan R, Murayama Y, Gobin YP, Duckwiler GR, Vinters HV, Vinuela F : Embolization of arteriovenous malformations with Onyx : clinicopathological experience in 23 patients. *Neurosurgery* 48 : 984-995; discussion 995-997, 2001
 43. Jiang WJ, Xu XT, Jin M, Du B, Dong KH, Dai JP : Apollo stent for symptomatic atherosclerotic intracranial stenosis : study results. *AJNR Am J Neuroradiol* 28 : 830-834, 2007
 44. Kato Y, Sano H, Dong PT, Panji N, Itezawa Y, Hayashi J, et al : The effect of clipping and coiling in acute severe subarachnoid hemorrhage after international subarachnoid aneurysm trial (ISAT) results. *Minim Invasive Neurosurg* 48 : 224-227, 2005
 45. Katsaridis V, Papagiannaki C, Violaris C : Guglielmi detachable coils versus matrix coils : a comparison of the immediate posttreatment results of the embolization of 364 cerebral aneurysms in 307 patients : a single-center, single-surgeon experience. *AJNR Am J Neuroradiol* 27 : 1841-1848, 2006
 46. Kawanabe Y, Sadato A, Taki W, Hashimoto N : Endovascular occlusion of intracranial aneurysms with Guglielmi detachable coils : correlation between coil packing density and coil compaction. *Acta Neurochir (Wien)* 143 : 451-455, 2001
 47. Kerber CW, Cromwell LD, Zanetti PH : Experimental carotid aneurysms : Part 2. Endovascular treatment with cyanoacrylate. *Neurosurgery* 16 : 13-17, 1985
 48. Kim IC, Chun YI, Park CW, Lee U : Angiographic Follow-up Result of Cerebral Aneurysms Treated with Coils Covered with Polyglycolic-Polylactic Acid Copolymer. *J Korean Neurosurg Soc* 39 : 286-291, 2006
 49. Kim LJ, Albuquerque FC, Spetzler RF, McDougall CG : Postembolization neurological deficits in cerebral arteriovenous malformations : stratification by arteriovenous malformation grade. *Neurosurgery* 59 : 53-59; discussion 53-59, 2006
 50. Kochii M, Kitamura I, Goto T, Nishi T, Takeshima H, Saito Y, et al : Randomized comparison of intra-arterial versus intravenous infusion of ACNU for newly diagnosed patients with glioblastoma. *J Neurooncol* 49 : 63-70, 2000
 51. Kole MK, Pelz DM, Kalapos P, Lee DH, Gulka IB, Lownie SP : Endovascular coil embolization of intracranial aneurysms : important factors related to rates and outcomes of incomplete occlusion. *J*

- Neurosurg** 102 : 607-615, 2005
52. Kwon HJ, Park JB, Kwon Y, Ahn JS, Kwun BD : Long-term clinical and radiologic results of small cerebral aneurysms embolized with 1 or 2 detachable coils. **Surg Neurol** 66 : 507-512, 2006
 53. Ledezma CJ, Hoh BL, Carter BS, Pryor JC, Putman CM, Ogilvy CS : Complications of cerebral arteriovenous malformation embolization : multivariate analysis of predictive factors. **Neurosurgery** 58 : 602-611; discussion 602-611, 2006
 54. Lubicz B, Gauvrit JY, Leclerc X, Lejeune JP, Pruvo JP : Giant aneurysms of the internal carotid artery : endovascular treatment and long-term follow-up. **Neuroradiology** 45 : 650-655, 2003
 55. Lubicz B, Leclerc X, Gauvrit JY, Lejeune JP, Pruvo JP : Giant vertebrobasilar aneurysms : endovascular treatment and long-term follow-up. **Neurosurgery** 55 : 316-323; discussion 323-326, 2004
 56. Luessenhop AJ, Spence WT : Artificial embolization of cerebral arteries. Report of use in a case of arteriovenous malformation. **Jama** 172 : 1153-1155, 1960
 57. Lylyk P, Ferrario A, Pasbon B, Miranda C, Doroszuk G : Buenos Aires experience with the Neuroform self-expanding stent for the treatment of intracranial aneurysms. **J Neurosurg** 102 : 235-241, 2005
 58. Malek AM, Halbach VV, Phatouros CC, Lempert TE, Meyers PM, Dowd CF, et al : Balloon-assist technique for endovascular coil embolization of geometrically difficult intracranial aneurysms. **Neurosurgery** 46 : 1397-1406; discussion 1406-1407, 2000
 59. Mawad ME, Mawad JK, Cartwright J Jr, Gokaslan Z : Long-term histopathologic changes in canine aneurysms embolized with Guglielmi detachable coils. **AJNR Am J Neuroradiol** 16 : 7-13, 1995
 60. Meisel HJ, Mansmann U, Alvarez H, Rodesch G, Brock M, Lasjaunias P : Effect of partial targeted N-butyl-cyano-acrylate embolization in brain AVM. **Acta Neurochir (Wien)** 144 : 879-887; discussion 888, 2002
 61. Molyneux A, Kerr R, Stratton I, Sandercock P, Clarke M, Shrimpton J, et al : International Subarachnoid Aneurysm Trial (ISAT) of neurosurgical clipping versus endovascular coiling in 2143 patients with ruptured intracranial aneurysms : a randomised trial. **Lancet** 360 : 1267-1274, 2002
 62. Molyneux AJ, Cekirge S, Saatci I, Gal G : Cerebral Aneurysm Multicenter European Onyx (CAMEO) trial : results of a prospective observational study in 20 European centers. **AJNR Am J Neuroradiol** 25 : 39-51, 2004
 63. Moniz E : L'encéphalographie artérielle, son importance dans la localisation des tumeurs cérébrales. **Revue Neurologique** 2 : 72-90, 1927
 64. Murayama Y, Nien YL, Duckwiler G, Gobin YP, Jahan R, Frazee J, et al : Guglielmi detachable coil embolization of cerebral aneurysms : 11 years' experience. **J Neurosurg** 98 : 959-966, 2003
 65. Murayama Y, Tateshima S, Gonzalez NR, Vinuela F : Matrix and bioabsorbable polymeric coils accelerate healing of intracranial aneurysms : long-term experimental study. **Stroke** 34 : 2031-2037, 2003
 66. Murayama Y, Vinuela F, Tateshima S, Song JK, Gonzalez NR, Wallace MP : Bioabsorbable polymeric material coils for embolization of intracranial aneurysms : a preliminary experimental study. **J Neurosurg** 94 : 454-463, 2001
 67. Murayama Y, Vinuela F, Tateshima S, Vinuela F Jr, Akiba Y : Endovascular treatment of experimental aneurysms by use of a combination of liquid embolic agents and protective devices. **AJNR Am J Neuroradiol** 21 : 1726-1735, 2000
 68. Nelson PK, Sahlein D, Shapiro M, Becske T, Fitzsimmons BF, Huang P, et al : Recent steps toward a reconstructive endovascular solution for the orphaned, complex-neck aneurysm. **Neurosurgery** 59 : S77-92; discussion S3-13, 2006
 69. Nishimoto A, Kuyama H, Nagao S, Kinugasa K, Kunishio K : Artificial embolization with isobutyl-2-cyanoacrylate for the treatment of carotid-ophthalmic aneurysm. **Surg Neurol** 28 : 46-50, 1987
 70. Nishino A, Sakurai Y, Arai H, Nishimura S, Suzuki S, Uenohara H : Clinical manifestations, character of aneurysms, and surgical results for unruptured cerebral aneurysms presenting with ophthalmic symptoms. **Acta Neurochir Suppl** 82 : 47-49, 2002
 71. Nonaka T, Haraguchi K, Baba T, Koyanagi I, Houkin K : Clinical manifestations and surgical results for paraclinoid cerebral aneurysms presenting with visual symptoms. **Surg Neurol** 67 : 612-619; discussion 619, 2007
 72. Otsuka G, Miyachi S, Handa T, Negoro M, Okamoto T, Suzuki O, et al : Endovascular trapping of giant serpentine aneurysms by using Guglielmi detachable coils : successful reduction of mass effect. Report of two cases. **J Neurosurg** 94 : 836-840, 2001
 73. Pandey AS, Koebbe C, Rosenwasser RH, Veznedaroglu E : Endovascular coil embolization of ruptured and unruptured posterior circulation aneurysms : review of a 10-year experience. **Neurosurgery** 60 : 626-636; discussion 636-637, 2007
 74. Pero G, Denegri F, Valvassori L, Boccardi E, Scialfa G : Treatment of a middle cerebral artery giant aneurysm using a covered stent. Case report. **J Neurosurg** 104 : 965-968, 2006
 75. Piotin M, Mandai S, Murphy KJ, Sugiu K, Gailloud P, Martin JB, et al : Dense packing of cerebral aneurysms : an in vitro study with detachable platinum coils. **AJNR Am J Neuroradiol** 21 : 757-760, 2000
 76. Raja AI, Ausman JI : Time-line for the treatment of cerebral AVMS : surgery. **Surg Neurol** 53 : 552-553, 2000
 77. Raupp EF, Fernandes J : Does treatment with N-butyl cyanoacrylate embolization protect against hemorrhage in cerebral arteriovenous malformations? **Arq Neuropsiquiatr** 63 : 34-39, 2005
 78. Reul J, Spetzger U, Weis J, Sure U, Gilsbach JM, Thron A : Endovascular occlusion of experimental aneurysms with detachable coils : influence of packing density and perioperative anticoagulation. **Neurosurgery** 41 : 1160-1165; discussion 1165-1168, 1997
 79. Reul J, Weis J, Spetzger U, Konert T, Fricke C, Thron A : Long-term angiographic and histopathologic findings in experimental aneurysms of the carotid bifurcation embolized with platinum and tungsten coils. **AJNR Am J Neuroradiol** 18 : 35-42, 1997
 80. Ricci G, Ricci A, Gallucci M, Zotta U, Scogna A, Costagliola C, et al : Combined endovascular and microsurgical approach in the treatment of giant paraclinoid and vertebrobasilar aneurysms. **J Neurosurg Sci** 49 : 1-6, 2005
 81. Ross JB, Dhillon GS : Balloon assistance as a routine adjunct to the endovascular treatment of cerebral aneurysms. **Surg Neurol** 66 : 593-601; discussion 601-602, 2006
 82. Sani S, Jobe KW, Lopes DK : Treatment of wide-necked cerebral aneurysms with the Neuroform2 Treo stent. A prospective 6-month study. **Neurosurg Focus** 18 : E4, 2005
 83. Seldinger SI : Catheter replacement of the needle in percutaneous arteriography; a new technique. **Acta radiol** 39 : 368-376, 1953
 84. Serbinenko FA : Six hundred endovascular neurosurgical procedures in vascular pathology. A ten-year experience. **Acta Neurochir Suppl (Wien)** 28 : 310-311, 1979
 85. Slob MJ, Sluzewski M, van Rooij WJ : The relation between packing and reopening in coiled intracranial aneurysms : a prospective study. **Neuroradiology** 47 : 942-945, 2005
 86. Sluzewski M, Menovsky T, van Rooij WJ, Wijnalda D : Coiling of very large or giant cerebral aneurysms : long-term clinical and serial angiographic results. **AJNR Am J Neuroradiol** 24 : 257-262, 2003
 87. Sluzewski M, van Rooij WJ, Beute GN, Nijssen PC : Late rebleeding of ruptured intracranial aneurysms treated with detachable coils. **AJNR Am J Neuroradiol** 26 : 2542-2549, 2005
 88. Sluzewski M, van Rooij WJ, Slob MJ, Bescos JO, Slump CH, Wijnalda D : Relation between aneurysm volume, packing, and compaction in 145 cerebral aneurysms treated with coils. **Radiology** 231 : 653-658, 2004
 89. Song DL, Leng B, Zhou LF, Gu YX, Chen XC : Onyx in treatment of large and giant cerebral aneurysms and arteriovenous malformations. **Chin Med J (Engl)** 117 : 1869-1872, 2004
 90. SSYLIVIA Study Investigators : Stenting of Symptomatic Atherosclerotic Lesions in the Vertebral or Intracranial Arteries (SSYLIVIA) : study results. **Stroke** 35 : 1388-1392, 2004
 91. Striebel-Kalish H, Maimon S, Amsalem J, Erlich R, Kalish Y, Rappaport HZ : Evolution of oculomotor nerve paresis after endovascular coiling of posterior communicating artery aneurysms : a neuro-ophthalmological perspective. **Neurosurgery** 53 : 1268-1273; discussion 1273-1274, 2003
 92. Suzuki S, Kurata A, Ohmomo T, Sagiuchi T, Niki J, Yamada M, et al : Endovascular surgery for very small ruptured intracranial aneurysms. Technical note. **J Neurosurg** 105 : 777-780, 2006
 93. Szikora I, Berentei Z, Kulcsar Z, Barath K, Berez A, Bose A, et al :

- Endovascular treatment of intracranial aneurysms with parent vessel reconstruction using balloon and self expandable stents. *Acta Neurochir (Wien)* 148 : 711-723; discussion 723, 2006
94. Taki W, Yonekawa Y, Iwata H, Uno A, Yamashita K, Amemiya H : A new liquid material for embolization of arteriovenous malformations. *AJNR Am J Neuroradiol* 11 : 163-168, 1990
95. Taylor CL, Dutton K, Rappard G, Pride GL, Replogle R, Purdy PD, et al : Complications of preoperative embolization of cerebral arteriovenous malformations. *J Neurosurg* 100 : 810-812, 2004
96. Uno M, Satoh K, Matsubara S, Satomi J, Nakajima N, Nagahiro S : Does multimodality therapy of arteriovenous malformations improve patient outcome? *Neurol Res* 26 : 50-54, 2004
97. Vallee JN, Pierot L, Bonafe A, Turjman F, Flandroy P, Berge J, et al : Endovascular treatment of intracranial wide-necked aneurysms using three-dimensional coils : predictors of immediate anatomic and clinical results. *AJNR Am J Neuroradiol* 25 : 298-306, 2004
98. van Rooij WJ, Sluzewski M : Procedural morbidity and mortality of elective coil treatment of unruptured intracranial aneurysms. *AJNR Am J Neuroradiol* 27 : 1678-1680, 2006
99. van Rooij WJ, Sluzewski M, Beute GN : Brain AVM embolization with Onyx. *AJNR Am J Neuroradiol* 28 : 172-177; discussion 178, 2007
100. Weber W, Kis B, Siekmann R, Kuehne D : Endovascular treatment of intracranial arteriovenous malformations with onyx : technical aspects. *AJNR Am J Neuroradiol* 28 : 371-377, 2007
101. Weber W, Siekmann R, Kis B, Kuehne D : Treatment and follow-up of 22 unruptured wide-necked intracranial aneurysms of the internal carotid artery with Onyx HD 500. *AJNR Am J Neuroradiol* 26 : 1909-1915, 2005
102. Wikholm G, Lundqvist C, Svendsen P : The Goteborg cohort of embolized cerebral arteriovenous malformations : a 6-year follow-up. *Neurosurgery* 49 : 799-805; discussion 805-806, 2001
103. Yanaka K, Matsumaru Y, Mashiko R, Hyodo A, Sugimoto K, Nose T : Small unruptured cerebral aneurysms presenting with oculomotor nerve palsy. *Neurosurgery* 52 : 553-557; discussion 556-557, 2003