

## Reflex seizures induced by micturition : A pediatric case and ictal EEG finding

Young Il Rho, M.D.

*Department of Pediatrics, College of Medicine, Chosun University, Gwangju, Korea*

### = Abstract =

Reflex seizures induced by micturition are rare, and there have been few reports on ictal electroencephalogram (EEG) findings. Here, we report a 7-year-old boy with secondarily generalized partial seizures induced by micturition. The seizures occurred every time he urinated. A few seconds after micturition begun, he toppled down with hand automatism followed by a secondarily generalized tonic posture and loss of consciousness. Ictal video-EEG recording during urination was performed. An ictal EEG demonstrated a polyspike wave discharge onset from the left frontotemporal region, with rapid spread to the right frontotemporal region. He was treated with the antiepileptic drug valproate sodium, which improved seizure control. He remained seizure-free until the last followup for a period of 2 years. (*Korean J Pediatr* 2008 51:1346-1349)

**Key Words :** Reflex Seizures, Micturition, Ictal EEG

### Introduction

Reflex seizures are those which are predominantly or exclusively triggered by a specific stimuli. They arise from areas of cortical hyperexcitability that overlap with regions normally activated during specific cognitive, motor and sensory stimulation<sup>1</sup>. Micturition is a complex event coordinated by multiple levels of the central and peripheral nervous systems. Reflex seizure induced by micturition was first described by Zivin and Rowley in 1964<sup>2</sup>. These are extremely rare, with only eight cases in the literature<sup>2-9</sup>. Reflex seizures may occur as an isolated entity or as a part a focal or generalized epilepsy syndrome. We report a child case of secondarily generalized partial seizures induced by micturition with an ictal EEG recording was obtained.

### Case report

The patient was a 7 year-old right-hand dominant boy with moderate mental retardation. He had a past history of generalized tonic-clonic seizure of unknown etiology at 2

years of age and treated with antiepileptic medication during only one month. He had been seizure-free in the last 5 years without medication. At 7 years of age, he had a relapse of the seizure. The seizures occurred every time when he urinated. On the day of admission, he has microcephaly (head circumference 37 cm, <3 percentile). Neurologic examination was normal. His complete blood count was normal (Hb 12.5 g/dL, Hct 37.1%, WBC 7,130/mm<sup>3</sup>, platelet 360,000/mm<sup>3</sup>). The blood biochemical analysis showed blood sugar 80 mg/dL, Na 144 mEq/L, K 4.8 mEq/L, AST/ALT 25/10 U/L, ammonia 77 ug/dL and LDH/CK 667/87 U/L. Thyroid function test was normal. A cerebrospinal fluid examination was normal. Brain MRI was normal. Interictal EEG showed generalized burst of spike and slow waves complex, predominantly on both frontocentral area (Fig. 1). Ictal video-EEG recording during urination was performed. A few seconds after micturition begun, he toppled down with hand automatism followed by a secondarily generalized tonic posture and loss of consciousness. Ictal EEG demonstrated a polyspike wave discharges onset from the left frontotemporal region, with rapid spread to the right frontotemporal region (Fig. 2). This video and EEG recordings confirmed that micturition preceded and precipitated seizures, thus ruling out more common phenomena such as micturition syncope. His chosen antiepileptic drug was valproate sodium, which led to a improvement in seizure control. He remained seizure free for 2 years until the last follow-up.

Received : 25 August 2008, Revised : 22 September 2008,

Accepted : 10 October 2008

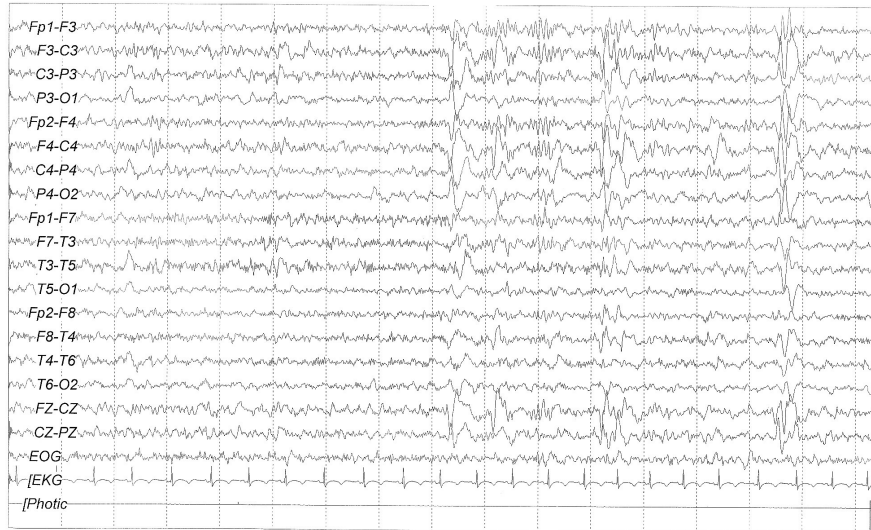Address for correspondence : Young Il Rho, M.D.

Department of Pediatrics, College of Medicine, Chosun University

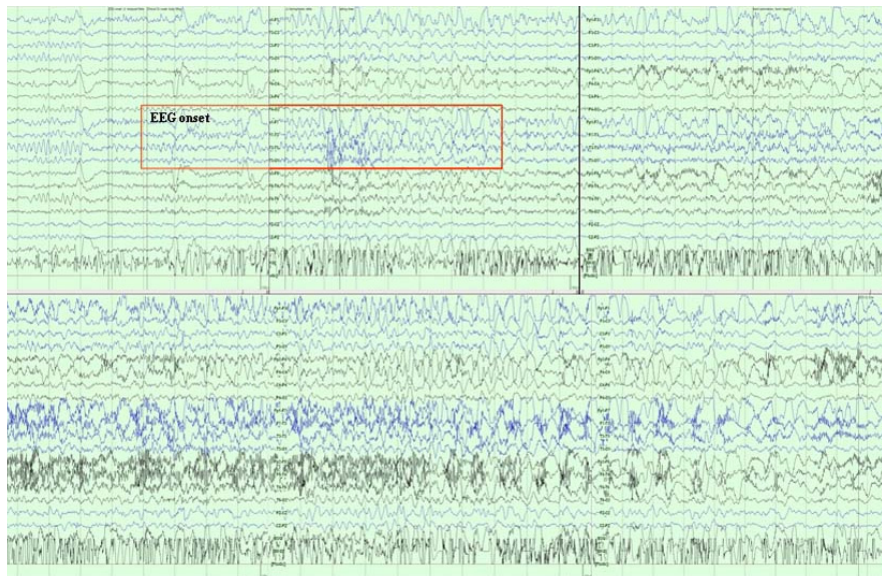
588 Suhsuk-dong, Dong-gu, Gwangju 501-717, Korea

Tel : +82.62-220-3040, Fax : +82.62-227-2904

Email : ryoung@chosun.ac.kr



**Fig. 1.** Interictal EEG showed a generalized burst of spikes and slow complex waves, predominantly on both frontocentral areas.



**Fig. 2.** Ictal EEG demonstrated a polyspike wave discharge onset from the left frontotemporal region, with rapid spread to the right frontotemporal region.

## Discussion

Reflex seizures are epileptic events triggered by specific stimuli. Pediatric reflex frontal lobe epilepsies are most often generated in the premotor or motor cortex and are usually triggered by somesthetic, auditory, or visual stimuli<sup>10</sup>. Micturition is coordinated by multiple levels of the central and peripheral nervous system. The cortical control of micturition

comes from superomedial portion of the frontal lobe and the anterior aspect of the cingulate gyrus. Positron emission tomography (PET) studies show that the right-sided micturition centers are more active than those on the left<sup>11</sup>.

Viscerosensory stimuli caused by micturition itself were most likely to have provoked seizures. Micturition induced seizures have been several reports on ictal EEG findings<sup>2-9</sup>. The age of those patients ranged from 5 to 15 years. Their seizure manifestations were different among patients. Three

patients had preserved consciousness, whereas the others had loss of consciousness. Motor components were tonic or clonic, involving unilateral or bilateral extremities.

Although micturition-induced reflex epilepsy is poorly understood, published cases suggest a midline or right frontal focus. Spinnler and Valli<sup>3)</sup> described a 16-year-old girl with mental retardation and reflex seizures occurring toward the end of micturition. The EEG showed a spike-wave pattern arising from the central anterior leads, possibly from the right frontal lobe. Pradhan and Kalita<sup>5)</sup> reported a 15-year-old with micturition-induced secondarily generalized tonic-clonic seizures due to a calcified granuloma in the right frontal lobe. Interictal EEG showed right frontal spikes; ictal EEG was not recorded. Bourgeois<sup>7)</sup> reported a boy with mental retardation due to a chromosomal anomaly with reflex seizures triggered by two different stimuli; micturition and immersion of his feet in tepid or hot water. Ictal VTR-EEG recording of a seizure triggered by immersion in hot water showed that the seizure onset was at Cz and possibly F4. Glass et al<sup>8)</sup> reported a 12-year old girl with moderate developmental delay and reflex epilepsy induced by both micturition and the emotional response to prayer. Single photon emission computed tomography (SPECT) and EEG suggested seizure onset from the anterior cingulate, with rapid spread to the right anterolateral frontal lobe. It is suggested that this patient has a region of cortical hyperexcitability in the “affect” component of the anterior cingulate cortex. Okumura, et al<sup>9)</sup> reported micturition induced seizures with ictal EEG and subtraction ictal SPECT findings. Ictal EEG showed low voltage fast waves without clear focal features followed by frontal dominant rhythmic multiple spikes. Ictal SPECT revealed a significant increase in blood flow in the mesial frontal area. The origin of seizures of this patient would be the supplementary sensorimotor areas is also compatible with several reports on supplementary sensorimotor area seizures induced by various stimuli other than micturition<sup>12, 13)</sup>. Most of ictal EEGs of such seizures displayed low amplitude fast activities or widespread flattening at the beginning of the seizures. In order to clarify the precise origin of the epileptogenic activity leading to micturition induced seizures, ictal recordings with invasive electrodes might be helpful. We present a case of reflex epilepsy induced by micturition. Ictal EEG suggested seizure onset from the left frontotemporal area with spread to the right anterolateral frontal lobe.

Reflex seizures may occur as an isolated entity or as a

part a focal or generalized epilepsy syndrome. Okumura et al<sup>9)</sup> reported focal epilepsy induced exclusively by micturition. In our patient, he had secondarily generalized partial seizures induced exclusively by micturition.

Seizures induced by micturition must be differentiated from more-common conditions, including micturition syncope, urinary incontinence due to sphincter relaxation during generalized seizures, and the ictal urinary urge of nondominant temporal lobe epilepsy<sup>14, 15)</sup>. The patients with micturition syncope usually falls to the ground, may display tonic-clonic movements lasting only a few seconds, and has a prompt return to consciousness.

Therapy of reflex seizures involves limiting exposure to the provoking stimulus, as well as standard epilepsy medications. Antiepileptic medications are selected on the basis of electroclinical seizure type. But, antiepileptic drugs should be selected to meet individual's need since effects can vary. Focal epilepsy controlled with phenytoin, whereas carbamazepine and clonazepam were unhelpful<sup>9)</sup>. Refractory partial seizure was reported<sup>8)</sup>. The seizures remained refractory to adequate trials of phenobarbital, valproic acid, clonazepam, topiramate, lamotrigine, clobazam, and a ketogenic diet. Our patients treated with valproate sodium, which led to an improvement in seizure control and remained seizure free until the last follow-up during 2 years.

## 한글 요약

### 배뇨 유발 반사 발작: 소아에서 발작시 뇌파를 시행한 1예

조선대학교 의과대학 소아과학교실

#### 노영일

배뇨 유발 반사발작은 매우 드물며, 문헌상에서 단지 8례가 보고되었으며, 발작기 뇌파로 진단한 예는 국내에서 보고된 바 없다. 7세 남아가 이차전신화 부분발작을 주소로 내원하였다. 발작은 단지 배뇨 수초 후에 시작되었으며 손의 자동증과 함께 비틀거리며 쓰러지면서 의식소실과 함께 이차적으로 전신 강직 발작을 하였다. 발작기 뇌파에서 왼쪽 전두부와 측두부에서 다극서파가 보이다가 오른쪽 전두부와 측두부로 퍼져나가는 소견을 보여 배뇨 유발성 이차 전신화 부분발작으로 진단되어 보고하는 바이다.

## References

- 1) Ferlazzo E, Zifkin BG, Andermann E, Andermann F. Cor-

- tical triggers in generalized reflex seizures and epilepsies. *Brain* 2005;128:700-10.
- 2) Zivin I, Rowley W. Psychomotor epilepsy with micturition. *Arch Intern Med* 1964;113:8-13.
  - 3) Spinnler H, Valli G. Micturition "reflex" epilepsy: presentation of a clinical case. *Rivista di Patologia Nervosa e Mentale* 1969;90:212-20.
  - 4) Yamatani M, Murakami M, Konda M, Konishi T, Suzuki Y, Okada T, et al. An 8-year-old girl of micturition induced epilepsy (in Japanese). *No To Hattatsu* 1987;19:58-62.
  - 5) Pradhan S, Kalita J. Micturition induced reflex epilepsy. *Neurology India* 1993;41:221-3.
  - 6) Ikeno T, Morikawa A, Kimura I. A case of epileptic seizure evoked by micturition (in Japanese). *Rinsho Nouha* 1998; 40:205-8.
  - 7) Bourgeois BF. A retarded boy with seizures precipitated by stepping into the bath water. *Semin Pediatr Neurol* 1999;6: 151-6.
  - 8) Glass HC, Prieur B, Molnar C, Hamiwka L, Wirrell E. Micturition and emotion-induced reflex epilepsy: case report and review of the literature. *Epilepsia* 2006;47:2180-2.
  - 9) Okumura A, Kondo Y, Tsuji T, Ikuta T, Negoro T, Kato K, et al. Micturition induced seizure: ictal EEG and subtraction ictal SPECT findings. *Epilepsy Research* 2007;73:119-21.
  - 10) Vignal JP, Maillard L. Reflex frontal lobe epilepsies. In: Beaumanoir A, Andermann F, Chauvel P, Mira L, Zifkin B (Eds). *Frontal lobe seizures and epilepsies in children*. John Libbey Eurotext, Montrouge, 2003:93-106.
  - 11) Blok BF, Willemsen AT, Holstege G. A PET study on brain control of micturition in humans. *Brain* 1997;120:111-21.
  - 12) Pierelli F, Di Gennaro G, Gherardi M, Spanedda F, Marciani MG. Movement-induced seizures: a case report. *Epilepsia* 1997;38:941-4.
  - 13) Kanemoto K, Watanabe Y, Tsuji T, Fukami M, Kawasaki J. Rub epilepsy: a somatosensory evoked reflex epilepsy induced by prolonged cutaneous stimulation. *J Neurol Neurosurg Psychiatr* 2001;70:541-3.
  - 14) Kasperek S, Bury W. Micturition syncope: a peculiar cause of diagnostic doubt. *Neurol Neurochir Pol* 1998;32:1289-93.
  - 15) Baumgartner C, Groppel G, Leutmezer F, Aull-Watschinger S, Patariaia E, Feucht M, et al. Ictal urinary urge indicates seizure onset in the nondominant temporal lobe. *Neurology* 2000;55:432-4.