

Detection of *Gnathostoma spinigerum* Third-Stage Larvae in Snakeheads Purchased from a Central Part of Myanmar

Bong-Kwang Jung¹, Jin-Ju Lee¹, Kyoung-Ho Pyo¹, Hyeong-Jin Kim¹, Hoo-Gn Jeong², Cheong-Ha Yoon²,
Soon-Hyung Lee^{1,2}, Eun-Hee Shin^{1,3} and Jong-Yil Chai^{1,*}

¹Department of Parasitology and Tropical Medicine, Seoul National University College of Medicine, and Institute of Endemic Diseases, Seoul National University Medical Research Center, Seoul 110-799, Korea; ²Korea Association of Health Promotion, Seoul 157-704, Korea; ³Seoul National University Bundang Hospital, Gyeonggi-do 463-707, Korea

Abstract: To examine the infection status of freshwater fish with *Gnathostoma* spp. larvae in Myanmar, we purchased 15 snakeheads, *Channa striatus*, from a local market in a suburban area of Naypyidaw, the new capital city. Two larval gnathostomes were collected using an artificial digestion technique, and observed by a light microscope and a scanning electron microscope. The size of an intact larva was 2.65 mm long and 0.32 mm wide. The characteristic morphology of the larvae included the presence of a long esophagus (0.80 mm long), 2 pairs of cervical sacs (0.43 mm long), and a characteristic head bulb with 4 rows of hooklets. The number of hooklets in the 1st, 2nd, 3rd, and 4th row was 45, 48, 50, and 52, respectively. Based on these morphological characters, the larvae were identified as the advanced 3rd-stage larvae of *Gnathostoma spinigerum*. This is the first report of detection of *G. spinigerum* 3rd-stage larvae in the central part of Myanmar. Our study suggests that intake of raw meat of snakehead fish in Myanmar may result in human gnathostomiasis.

Key words: *Gnathostoma spinigerum*, advanced 3rd-stage larva, snakehead, Myanmar

Several species of the genus *Gnathostoma* are clinically important, causing food-borne parasitic zoonoses in humans [1]. More than 10 *Gnathostoma* species have been reported in various parts of Southeast Asia, including Japan and Thailand, Europe, Oceania, and Americas [1]. A human infection with *Gnathostoma spinigerum* was first documented in 1836 in Thailand [1,2], and then *Gnathostoma hispidum*, *Gnathostoma nipponicum*, and *Gnathostoma doloresi* infections have been added to the species that are able to cause human infections [3-7]. The infection is clinically characterized by creeping eruption in subcutaneous tissues due to migrating larvae [3]. However, the larvae are also known to invade the lungs, eyes, and even the brain, occasionally causing death [3].

The adult worms of *Gnathostoma* are found in the stomach or esophageal wall of definitive hosts including cats and dogs [1]. When the feces of definitive hosts containing eggs are deposited in freshwater, free-swimming first-stage larvae are liberated and ingested by cyclops in which they molt twice to become early 3rd-stage larvae (L3). They then develop into advanced L3 in the second intermediate hosts, namely freshwater fish and amphibia. They are passed to a wide spectrum of paratenic hosts

including reptiles, birds, and mammals including humans. The principal mode of human infection by *Gnathostoma* is consumption of raw or undercooked flesh of second intermediate hosts containing 3rd-stage larvae [4].

Human gnathostomiasis has been known to be prevalent in Thailand and Japan [1]. However, in Myanmar, a neighboring country of Thailand, only a few reports have been available [8-10]. It is of particular note that recently there was an outbreak of human gnathostomiasis due to *G. spinigerum* around Yangon area, the former capital of Myanmar, among 60 Korean immigrants who consumed raw freshwater fish [8]. Human subcutaneous tissue infections possibly by *Gnathostoma malaysiae* were also reported in 2 Japanese men who visited Myanmar and had eaten raw freshwater shrimps [11]. However, studies on the occurrence of larval infections in fish or amphibian hosts are scarce. Thus, the present study was carried out to determine the presence of *Gnathostoma* larvae in a species of snakehead fish purchased in a central part of Myanmar.

A total of 15 snakeheads, *Channa striatus* (Fig. 1), 15-20 cm in length, were purchased from a local market in a suburban area of Naypyidaw, the new capital located in the central part of Myanmar. To examine *Gnathostoma* larvae, the flesh of snakeheads was ground in a meat grinder, and incubated with an artificial digestive juice containing 0.6% pepsin and 0.08% HCl

• Received 5 August 2008, accepted after revision 5 September 2008.

* Corresponding author (cyj@snu.ac.kr)

at 37°C for 2-3 hr. The larvae were collected from the digested material, washed twice with 0.85% saline, and examined using a stereomicroscope [8]. In order to identify the species, one par-

tially broken larva with an intact head part was washed 3 times with physiological saline (pH 7.2) and fixed in 2.5% glutaraldehyde at 4°C. After 3 washings with this buffer, the larva was

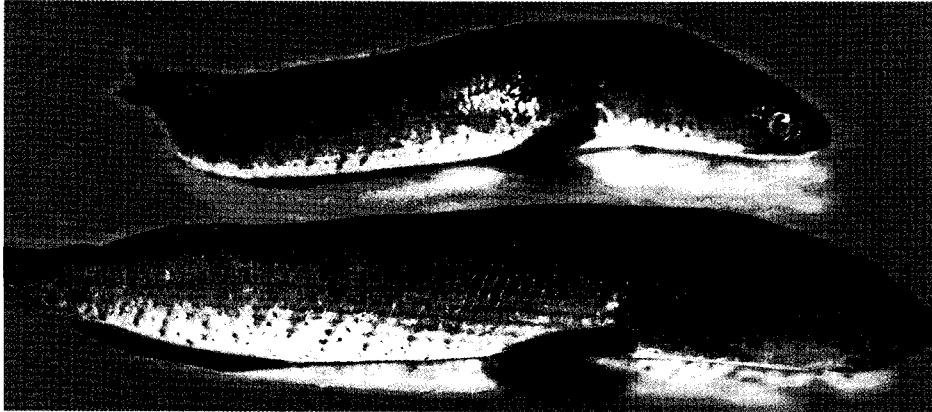

Fig. 1. The snakehead fish (15-20 cm long), *Channa striatus*, purchased from a central part of Myanmar.

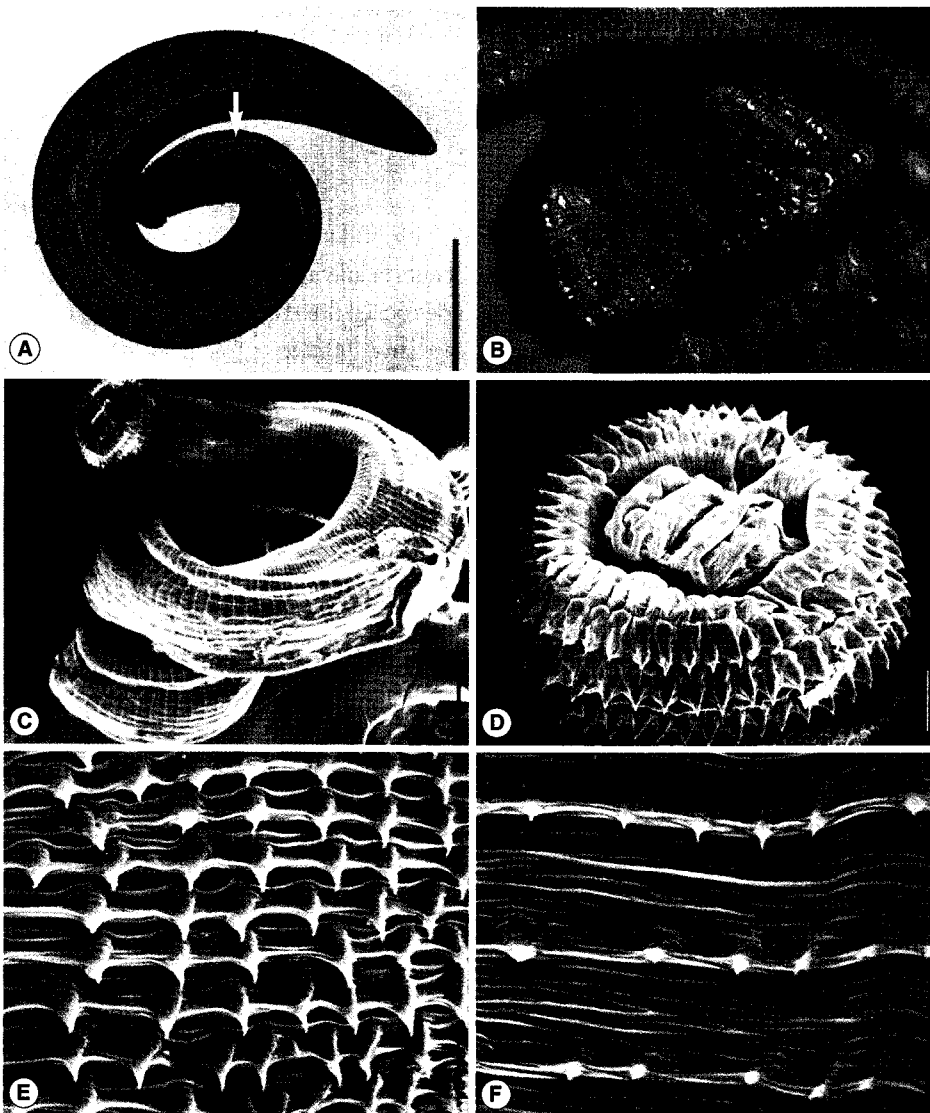


Fig. 2. An advanced 3rd-stage larva of *G. spinigerum* recovered from the muscle of a snakehead fish. Light microscopic (LM) (A, B) and scanning electron microscopic (SEM) (C-F) views. (A) LM view of a whole larva showing the head bulb, esophagus, and cervical sacs (arrow) (Bar = 500 μm). (B) The head bulb showing 4 rows of hooklets, 45, 48, 50, and 52, from the anterior to posterior rows (Bar = 100 μm). (C) SEM view of a whole larva (Bar = 50 μm). (D) SEM view of the head bulb showing 4 rows of hooklets and a pair of lips protruded on the anterior end of the body (Bar = 20 μm). (E, F) SEM views of the body surface of the anterior end part (E) and middle part (F) of the larva (Bar = 5 μm).

Table 1. Infection status of snakeheads with advanced L3 of *Gnathostoma spinigerum*

Species of snakehead	No. of fish examined	No. (%) of fish infected	No. of larvae detected	
			Total	Average per infected fish
<i>Channa striatus</i>	15	2 (13.3)	2	1.0

dehydrated in a graded ethanol series (50%, 70%, 80%, 90%, 95%, and absolute alcohol), dried in a critical point dryer, coated with gold, and observed using a scanning electron microscope (SEM) (ISI DS-130C, Akashi Co., Tokyo, Japan) with an accelerating voltage of 10 kV.

Two larval gnathostomes were harvested from 2 (13.3%) of 15 snakeheads examined (Table 1). One larva was morphologically intact, and the other was destroyed a little. The body of the intact larva was short, thick, coiled, and 2.65 mm long and 0.32 mm wide (Fig. 2A). It had a characteristic head bulb with 4 rows of hooklets (Fig. 2A-D). The number of hooklets in the 1st, 2nd, 3rd, and 4th row was 45, 48, 50, and 52, respectively. A pair of lips was located at the anterior end of the body and 4 ballonets around them (Fig. 2D). The spines were densely distributed on the body surface of the anterior part and gradually decreased in the size and number toward the middle portion and then increased at the posterior end portion, as revealed by SEM (Fig. 2C, E, F). The muscular esophagus was large, long (0.80 mm long), and connected to the intestine (Fig. 2A). Two pairs of cervical sacs (0.43 mm long) were observed around the esophagus (Fig. 2A).

Different species of larval gnathostomes can be discriminated by the morphology of the head bulb [1,2]. The larvae of *G. nipponicum* have a head bulb with 3 rows of hooklets, whereas the larvae of *G. spinigerum* have 4 rows of hooklets, to which our specimens are compatible. The larvae of *G. hispidum* also have 4 rows of hooklets [12]; however, the number of hooklets on each row is smaller than that in *G. spinigerum*. Based on the above morphological characters, we identified our larvae as the advanced L3 of *G. spinigerum*.

The second intermediate hosts of *G. spinigerum* are known to include various species of freshwater fish and amphibia [4]. Species of freshwater fish reported in Japan include *Channa argus argus* (snakehead), *Channa maculate* (blotched snakehead), *Parasilurus asotus* (= *Silurus asotus*; amur catfish), *Misgurnus anguillicaudatus* (loach), *Acanthogobius hasta* (goby), and *Cyprinus auratus* (= *Carassius auratus*; carp) [1]. Fish hosts reported from Thailand include *Anabas testudineus* (climbing perch), *Channa striata* (snake-

head murrel), *Channa micropeltes* (giant snakehead), *Channa lucius*, *Clarias batrachus* (walking catfish), and *Monopterus albus* (swamp eel) [13]. In the Republic of Korea, 2 third-stage larvae of *G. spinigerum* were detected in the abdominal muscle of a snakehead, *Channa argus argus* [14]. The outbreak of human gnathostomiasis among Korean immigrants in Yangon area, Myanmar, was suggested to be due to consumption of raw catfish or snakehead, containing 3rd-stage larvae of *G. spinigerum* [8].

The present study first confirmed the presence of a *G. spinigerum* life cycle by detecting the advanced L3 in freshwater fish in the central part of Myanmar. Based on our results there is a potential risk of human gnathostomiasis in the central part of Myanmar if improperly cooked snakeheads are consumed.

REFERENCES

- Miyazaki I. Section III. Nematode Zoonoses. 33. Gnathostomiasis. An Illustrated Book of Helminthic Zoonoses. Tokyo, Japan. International Medical Foundation of Japan. 1991, p 368-409.
- Han ET, Lee JH, Choi SY, Park JH, Shin EH, Chai JY. Surface ultrastructure of the advanced third-stage larvae of *Gnathostoma nipponicum*. J Parasitol 2003; 89: 1245-1248.
- Rusnak JM, Lucey DR. Clinical gnathostomiasis: case report and review of the English-language literature. Clin Infect Dis 1993; 16: 33-50.
- McCarthy J, Moore TA. Emerging helminth zoonoses. Int J Parasitol 2000; 30: 1351-1360.
- Nawa Y, Imai J, Ogata K, Otsuka K. The first record of a confirmed human case of *Gnathostoma doloresi* infection. J Parasitol 1989; 75: 166-169.
- Morishita K. A pig nematode, *Gnathostoma hispidum* Fedtschenko, as a human parasite. Ann Trop Med Parasitol 1924; 18: 23-26.
- Ando K, Tanaka H, Taniguchi Y, Shimizu M, Kondo K. Two human cases of gnathostomiasis and discovery of a second intermediate host of *Gnathostoma nipponicum* in Japan. J Parasitol 1988; 74: 623-627.
- Chai JY, Han ET, Shin EH, Park JH, Chu JP, Hirota M, Nakamura E, Nawa Y. An outbreak of gnathostomiasis among Korean emigrants in Myanmar. Am J Trop Med Hyg 2003; 69: 67-73.
- Gyi K. Intra-ocular gnathostomiasis. Br J Ophthalmol 1960; 44: 42-45.
- Khin T. Intra-ocular gnathostomiasis. Br J Ophthalmol 1968; 52: 57-60.
- Nomura Y, Nagakura K, Kagei N, Tsutsumi Y, Araki K, Sugawara M. Gnathostomiasis possibly caused by *Gnathostoma malaysiae*. Tokai J Exp Clin Med 2000; 25: 1-6.
- Cho SH, Kim TS, Kong Y, Na BK, Shon WM. Larval *Gnathostoma hispidum* detected in the red banded odd-tooth snake, *Dinodon rufozonatum rufozonatum*, from China. Korean J Parasitol 2007; 45: 191-198.

13. Rojekittikhun W. Gnathostomiasis in Thailand. In *Asian Parasitology*, Vol. 1. Arizono N, Chai JY, Nawa Y, Takahashi eds, Food-borne Helminthiasis in Asia. Chiba, Japan. AAA Committee, Federation of Asian Parasitologists. 2005, p 241-259.
14. Kim YK. A study on *Gnathostoma*. (1) An investigation into the geographical distribution of larvae on the second and third stage in Gyeongsang Nam do. *Bull Pusan Nat Univ (Natur Sci)* 1973; 15: 111-116 (in Korean).