

Reemergence of the bedbug *Cimex lectularius* in Seoul, Korea

In-Yong Lee¹, Han-Il Ree¹, Song-Jun An², John Alderman Linton² and Tai-Soon Yong^{1,*}

¹Department of Environmental Medical Biology and Institute of Tropical Medicine, ²International Clinic, Yonsei University College of Medicine, Seoul 120-752, Korea

Abstract: A healthy 30-yr-old woman carrying an insect that had been caught in her living room visited the International Clinic at Severance Hospital, Seoul, in December 2007. The insect she brought was identified to be a nymph of a bedbug, *Cimex lectularius*, and her skin rashes looked typical bedbug's bites. Her apartment was investigated, and a dead body of a bedbug, cast skins, and hatched eggs were found in her rooms and neighbors' rooms in the same building. She was living in that apartment in Seoul for 9 months since she had moved from New Jersey, USA. We assume that the bedbugs were introduced from abroad, since there had been no report on bedbugs in Seoul for more than 2 decades at least. This is a report of a reemergence of the common bedbug, *C. lectularius* in Seoul, Korea.

Key words: *Cimex lectularius*, bedbug, reemergence, Seoul, Korea

INTRODUCTION

Bedbugs are well known nocturnal hematophagous insects. The common human bedbug, *Cimex lectularius*, is distributed worldwide [1,2]. The bedbug bite is painless and the skin reaction varies from small macules to significant bullous eruptions [3-5].

Bedbug infestations are common in the developing world, occurring in settings of unsanitary living conditions and overcrowding. Bedbug infestations became rare during the second half of the 20th century and have been viewed as a condition that occurs in travelers returning from developing countries [4]. However, an increasing incidence of bedbug infestations has been widely reported in the recent medical literature, for example, in Germany [5], USA [6-9], Canada [10], Italy [11], and Australia [12]. The increased prevalence has been attributed to an increased international travel and trade, and a use of less noxious pesticides [6].

In Korea, the prevalence of bedbugs is believed to be dramatically decreased after the New Village Movement which was started in the 1960's (Saemaul Undong) due to the social and economic development and wide use of pesticides. It is generally believed that bedbugs have disappeared completely in Seoul.

CASE RECORD

A healthy 30-yr-old woman visited the International Clinic at Severance Hospital, Seoul, in December 2007 with a chief complaint of reddish itchy skin rashes on her arms and legs for 10 days. She also brought a dead insect that had been caught in her living room 2 days before she visited the hospital.

The insect she brought was observed using a stereomicroscope. The insect was found to be a wingless, flat, and light reddish-brown colored, ranging 4 mm, so that it was identified to be a nymph of the bedbug, *C. lectularius*, showing the prominent lateral protuberance of the pronotum (Fig. 1).

Physical examinations of the patient revealed skin rashes looking like typical bedbug's bites, which were distributed in a linear arrangement with small rashes and itching (Fig. 2). A few discrete papules were found along the neck, trunk, arms, and legs. We were allowed to investigate her apartment and 3 neighbors' apartments in the same building. We found a dead body and a cast of an egg-ball of the bedbug (Figs. 3, 4). One of her neighborhood also showed dozens of itchy skin rashes in her arms, legs, back, and abdomen. She complained that she was unable to sleep at night because of the insect bites. No dogs, cats, or other pets were found in any apartment. Disinfestation was achieved by treatment with insecticides (deltamethrin and dichlorvos) to the rooms. Three days after investigation, fumigation treatment was done to eliminate bedbugs from the apartment with a success.

• Received 8 August 2008, accepted after revision 5 November 2008.

* Corresponding author (tsyong212@yuhs.ac)

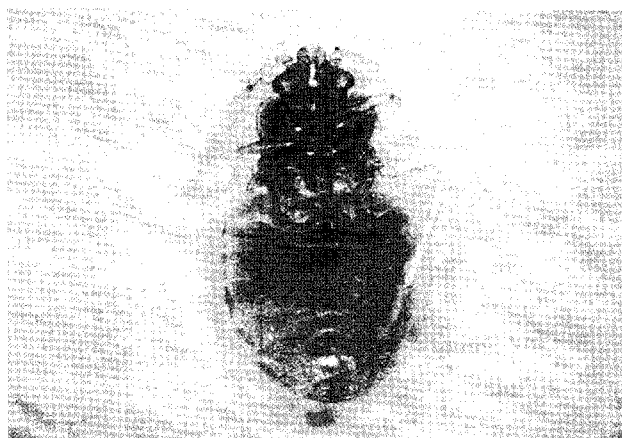


Fig. 1. A nymph of a bedbug *Cimex lectularius* brought by the patient ($\times 16$).

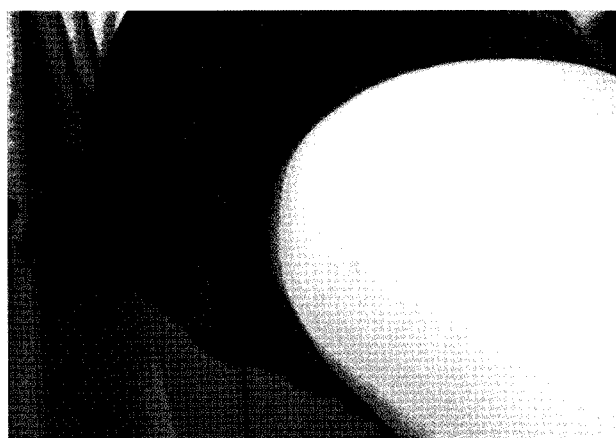

Fig. 2. Skin rashes of the patient due to bedbug bites.

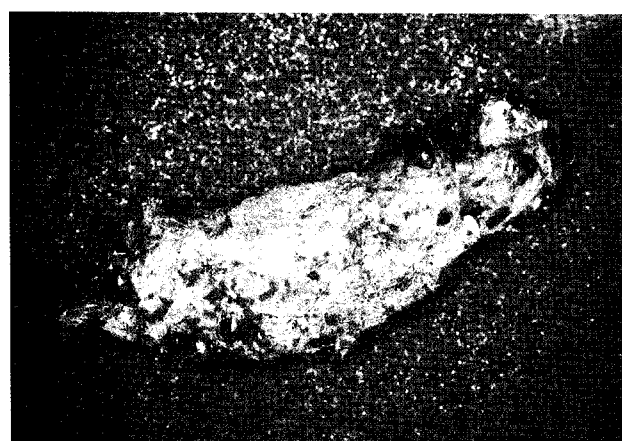


Fig. 3. Bedbug cast skins and hatched eggs ($\times 15$).

As far as we know, there had been no official report on bedbugs in Seoul for more than 2 decades. She lived in that apartment in Seoul for the last 9 months since she had moved from New Jersey, USA. Several outbreaks of bedbug infestations were reported recently in the vicinity of New York City, USA, where these cases and previous residents in the building had lived [9]. Although we cannot completely eliminate the possibility that the bedbugs we detected were not recently introduced, we assume that the bedbugs were introduced from abroad, maybe from USA.

DISCUSSION

The bedbug is one of the medically important insects. Confirming the diagnosis of a bedbug bite is sometimes difficult unless to obtain a detailed history of the home environment. However, bedbugs are not considered a serious disease threat.

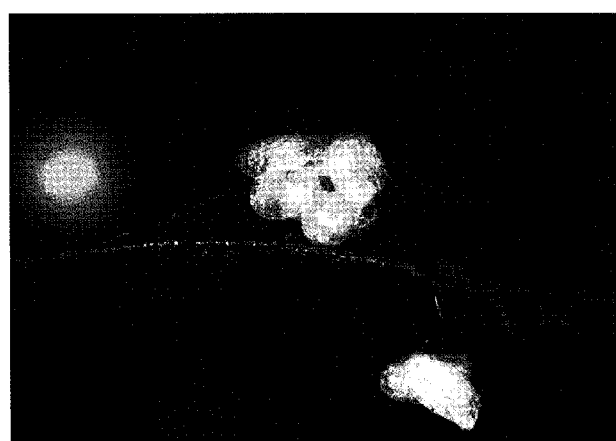

Fig. 4. Bedbug eggs ($\times 80$).

Their medical significance is mainly limited to itching and inflammation from their bites. Localized but occasionally systemic cutaneous reactions such as erythema, wheals, and vesicle formation are brought. Bedbug bites can also create considerable anxiety. The bedbug is perhaps a vector for hepatitis B, and also for american trypanosomiasis (Chagas' disease) in endemic areas [9,10,13].

There are 2 main species that bite humans. The common bedbug, *C. lectularius*, has the most widespread and worldwide distribution; the other species, *C. hemipterus*, is usually confined to tropical regions. The tropical bedbug bites mostly humans, whereas the common bedbug also attacks domestic animals and bats [1,2,14].

Bedbug infestations may go a long time unnoticed, and can become quite large before being detected. Bedbugs are one of the great travelers of the world and are readily transported via clothing, baggage, bedding, and furniture. This infestation is a

common and worldwide problem, particularly in poor regions of the world.

An increasing incidence of bedbug infestations has been widely reported recently in the popular press. Infestations of the bedbug seem to be increasing around the world at an alarming rate. Infestations have been reported in North America, Western Europe, and Australia [4,9].

Bedbug infestations were common in USA before the World War II. But with improvements in hygiene, and especially the widespread use of DDT during the 1940s-1950s, the bugs all but vanished. In recent years, bedbugs have also made a comeback in USA. They are increasingly being encountered in homes, apartments, hotels, motels, dormitories, shelters, and modes of transport. International travel and immigration have undoubtedly contributed to the resurgence of bedbugs in USA [6,9].

In Korea, for some 30 yr ago bedbugs were considered a minor public health pest. However, no single case of bedbug bites was diagnosed at the hospitals in Korea recently. In the present case there was circumstantial evidence for an association with international travels.

REFERENCES

1. Cho BK, Lee IY, Lee WK. Dermatoses by Hazardous Animals. Seoul, Korea. Seoheung Press. 2008; 158-161 (in Korean).
2. Reinhardt K, Siva-Jothy MT. Biology of the bed bugs (Cimicidae). *Ann Rev Entomol* 2007; 52: 351-374.
3. Elston DM, Stockwell S. What's eating you? Bedbugs. *Cutis* 2000; 65: 262-264.
4. Scarupa MD, Economides A. Bedbug bites masquerading as urticaria. *J Allergy Clin Immunol* 2006; 117: 1508-1509.
5. Liebold K, Schliemann-Willers S, Wollina U. Disseminated bullous eruption with systemic reaction caused by *Cimex lectularius*. *J Eur Acad Dermatol Venereol* 2003; 17: 461-463.
6. Ter Porten MC, Prose NS. The return of the common bedbug. *Pediatr Dermatol* 2005; 22: 183-187.
7. Cleary CJ, Buchanan D. Diagnosis and management of bedbugs: an emerging U.S. infestation. *Nurse Pract* 2004; 29: 46-48.
8. Krueger L. Don't get bitten by the resurgence of bed bugs. *Pest Control* 2000; 68: 58-64.
9. Anderson AL, Leffler K. Bedbug infestations in the news: a picture of an emerging public health in the United States. *J Environ Health* 2008; 70: 24-27.
10. Hwang SW, Sovoboda TJ, De Jong IJ, Kabasele KJ, Gogosis E. Bedbug infestations in an urban environment. *Emerg Infect Dis* 2005; 11: 533-538.
11. Masetti M, Bruschi F. Bedbug infestations recorded in Central Italy. *Parasitol Int* 2007; 56: 81-83.
12. Ryan ET, Wilson ME, Kain KC. Illness after international travel. *N Engl J Med* 2002; 347: 505-516.
13. Silverman AL, Qu LH, Blow J, Zitron IM, Gordon SC, Walker ED. Assessment of hepatitis B virus DNA and hepatitis C virus RNA in common bedbug (*Cimex lectularius* L.) and kissing bug (*Rodnius prolixus*). *Am J Gastroenterol* 2001; 96: 2194-2198.
14. Thomas I, Kihiczak GG, Schwartz RA. Bedbug bites: a review. *Int J Dermatol* 2004; 43: 430-433.