

# MARGINAL TISSUE RESPONSE TO DIFFERENT IMPLANT NECK DESIGN

Hanna Eun Kyong Bae<sup>1</sup>, BDS, MDS, Moon-Kyu Chung<sup>1</sup>, DDS, PhD,

In-Ho Cha<sup>2</sup>, DDS, PhD, Dong-Hoo Han<sup>1\*</sup>, DDS, PhD

<sup>1</sup>Department of Prosthodontics, Yonsei University College of Dentistry, Seoul, South Korea

<sup>2</sup>Department of Oral and Maxillofacial Surgery, Yonsei University College of Dentistry, Seoul, South Korea

## INTRODUCTION

Early clinical reports on osseointegration of dental implants have reported success rates of 81% in maxilla and 91% in mandible after 15 years, with marginal bone loss of 1.5 mm in the first year and approximately 0.1 mm annually from there after.<sup>1</sup> This satisfied the success criteria which were published in the years to follow; they were clinical stability, in function without any symptoms and with minimal bone resorption of less than 0.2 mm annually after the first year of the implantation.<sup>2,3</sup> The success of osseointegration of dental implant has been repeatedly demonstrated by numerous clinical studies in different implant designs, prosthodontic design and clinical situations which the implants have been applied.<sup>4,6</sup> The improvements in longevity of dental implants need to review on the success criteria of the marginal bone loss, of approximately 0.2 mm annually after the first year. The United States National Institutes of health consensus conference in 1988 have shown their concern of stable marginal bone level and advised clinical studies to have longitudinal evaluation of bone level measurements for an accurate implant evaluation.<sup>7</sup>

Aesthetics, as much as function, play an important role in patient satisfaction of implant dentistry.<sup>8</sup> The expected demands have led the clinician to increase their understanding and skill in implantation and restoration of the implant prosthesis.<sup>9,10</sup> In conjunction with these attempts, improvements in the design, texture and surface chemistry

of the implants have been made. Many of these are commercially available although some may only have had a short history of commercial life.<sup>11,12</sup>

The implant neck design is one of these areas of development. Micro-textured and the macro-textured surfaces were explored. These designs mainly aimed to enhance the stability of interface for both soft and hard tissue and minimise the marginal bone reduction in the first year of implantation.<sup>13</sup>

An animal study by Abrahamsson *et al.* has shown the marginal bone level differences between three different implant designs had no statistical significance. However, all three implant designs had turned surface at hard and soft tissue interface.<sup>14</sup> Astrand and his colleagues compared rough neck surfaced neck implant and turned surface over 5 years.<sup>15</sup> The measurements were better in the rough surfaced neck implant but there was no statistical significance.

Despite after these results, finite element studies have shown that the retentive form at the coronal portion of fixture have favourably reduced the peak interfacial shear stress at the margin and more stresses were present at the lower part of the implant.<sup>16</sup> On the micro texture implant, retention of hard tissues with the micro-textured surfaces was observed.<sup>17</sup>

The aim of the present study was to investigate the influence of three different implant neck designs on bone and soft tissue interface region in dogs at 8 and 12 weeks after implantation.

Corresponding Author: **Dong-Hoo Han**

Department of Prosthodontics, College of Dentistry, Yonsei University

134 Shinchon-dong, Seodaemoon-gu, 120-752, Seoul, South Korea +82-2-22283156: e-mail, donghoohan@yuhs.ac

Received October 23, 2008 Last Revision November 24, 2008 Accepted November 28, 2008.


## MATERIALS AND METHODS

### 2.1. Implants used

Three different implant designs have been used in this study; a turned neck (TN) implant, micro-threaded (MT) neck implant and micro-grooved (MG) neck implant. (Fig. 1) The TN implants had 1mm of turned surface at the neck of the fixture but treated by RBM (Resorbable Blasting Media) on the remaining implant surface (Avana implant system, Osstem co., Ltd., Seoul, Korea).

The coronal 2 mm of the MT implants were smaller threads of 400  $\mu\text{m}$  pitch and remaining larger square threads were treated by blasting and acid etching. (Oneplant, Warantec, Seoul, Korea)

The MG implant had finer threads at the coronal 2 mm of the neck with MG of 12 and 8  $\mu\text{m}$  pitched threads created using Excimer laser (Laser-lok, Bio-lok international Inc. Deerfield Beach, USA). It has 0.5 mm of turned surface, followed by 0.7 mm of MG with 8  $\mu\text{m}$  pitch and 0.8 mm MG at pitch of 12  $\mu\text{m}$ . The implant fixture body had a reverse threads treated with resorbable blast and acid etching.



**Fig. 1.** Three different types of implant neck designs.

A: Turned neck implants, B: Micro-threaded implants, C: Micro-grooved implants

### 2.2. Animal experiment

Four 1year old mongrel dogs with an average weight of 30 kg were used. Intravenous administered Ketamin (Ketalar, Yuhan, Seoul, Korea) 10 mg/kg with Profolol (pofol, Jeil Pharm., Seoul, Korea) 6 mg/kg were used in anesthetise the animals for the operative procedures. Further local anesthetics with lidocaine 2%, adrenaline 1/80000 (2% Lidocaine, 1 : 100,000 epinephrine, Kwangmyung Pharm., Seoul, Korea) were used.

The mandibular premolars 1, 2, 3 and 4 were extracted and left to heal for three months, before placing implant.

One of each implants types was placed randomly at the first and second premolar region in each dogs according to the manufacturers protocol and submerged. TN implants with 3.3 mm diameter and 10 mm in length, MT implant with 4.0 mm diameter and 11 mm in length and MG implant with 4 mm diameter and 11.5 mm in length were used.

Two of the dogs were sacrificed at week 8 and the remaining two dogs in week 12 after the implantation. The implant with surrounding tissue specimens were isolated and placed in 10% formaldehyde solution for fixation. After embedding the specimens in resin (Technovit 7200VLC, Kulzer, Hanau, Germany) block, sections (Exakt, Apparatebau, Norderstedt, Germany) were prepared in mesio-distal direction at thickness of approximately 60  $\mu\text{m}$  and stained for hematoxylin and eosin (H & E) for the alveolar bone pattern, morphometric measurements, and when it was possible further sections were stained with Masson's trichrome to view collagen arrangements in the soft tissue.

### 2.3. Histomorphometric examination

Use of an Olympus BH-2 microscope (Olympus, Tokyo, Japan) under normal and polarized lights for histological examination was carried out under magnification of 50 to 400.

The images were scanned and histomorphometric measurements were made using imaging analysis system (Image-Pro Plus, Media Cybernetics, Silver Spring, MD) The program was calibrated before each measurement. The morphometric measurements were measured as written in Sennerby *et al.*<sup>18</sup> and Mohammadi *et al.*<sup>19</sup> This study was interested in the tissue healing and reaction around the various implant neck designs and the measurements were only carried out on the coronal 2 mm of implants from the reference point.

## RESULTS

The bone-implant-contact (BIC) of coronal 2 mm of implants analysed in this study have shown that with increase in the healing duration, the BIC values increased. The difference between two healing duration was minimal in MT implants at 21.78% and 22.56% in week 8 and 12

**Table I.** Histomorphometric measurements of three different implants

Implant type Weeks	TN		MT		MG	
	8	12	8	12	8	12
BIC / %	22.28	30.49	21.78	22.56	35.51	41.02
Marginal bone loss / mm	1.61	1.63	0.79	0.56	0.4	0.26
Bone area in threads / %	-	-	64.74	56.55	55.43	44.77

respectively. The values were greater in the TN and the MG implants, from 22.28% to 30.49% and 35.51% to 41.02% respectively. The BIC values were higher with the MG implants than other implant systems (Table I).

The marginal bone level was lowest in the TN implants with 1.61 mm and 1.63 mm in specimens at week 8 and week 12 respectively. The values of MT were 0.79 mm and 0.56 mm, and MG were 0.40 mm and 0.26 mm, which were near to the reference point of the neck portion than in TN implants.

As the TN implant had smooth collar at the coronal portion, no bone area in the threads could be measured. Despite the differences in the marginal bone loss, the percentages of bone filled in MT and MG were similar. The MG implants had the lower bone filled percentage values of 55.43% and 44.77% in week 8 and 12 respectively, and the values were lower in week 12 than in week 8 in both MT and MG implants.

### 3.2. Histological examination

The quantities of trabecular bones in the week 12 specimens were greater than in the week 8 specimens. The cortical bone could be seen in the former specimens than in the latter, and primary and secondary osteons could be seen adjacent to the implants. More remodelling activities could be noted at MT implant surfaces.

Under the polarised lights, clear stages of mineralization and bone remodelling could be observed. The TN implants were close to the surface of the lamella bone in both 8 and 12 weeks and with little difference between them.

In both MT and MG implants a thin layer of less organised bone adjacent to the implant could be seen and the width was greater towards the coronal portion. At the marginal bone area of MG and MT implants were non-polarizing. These areas were greater in the MT group than in the MG group but reduced in the week 12 specimens than in week 8 specimens in both groups. The observed lamella

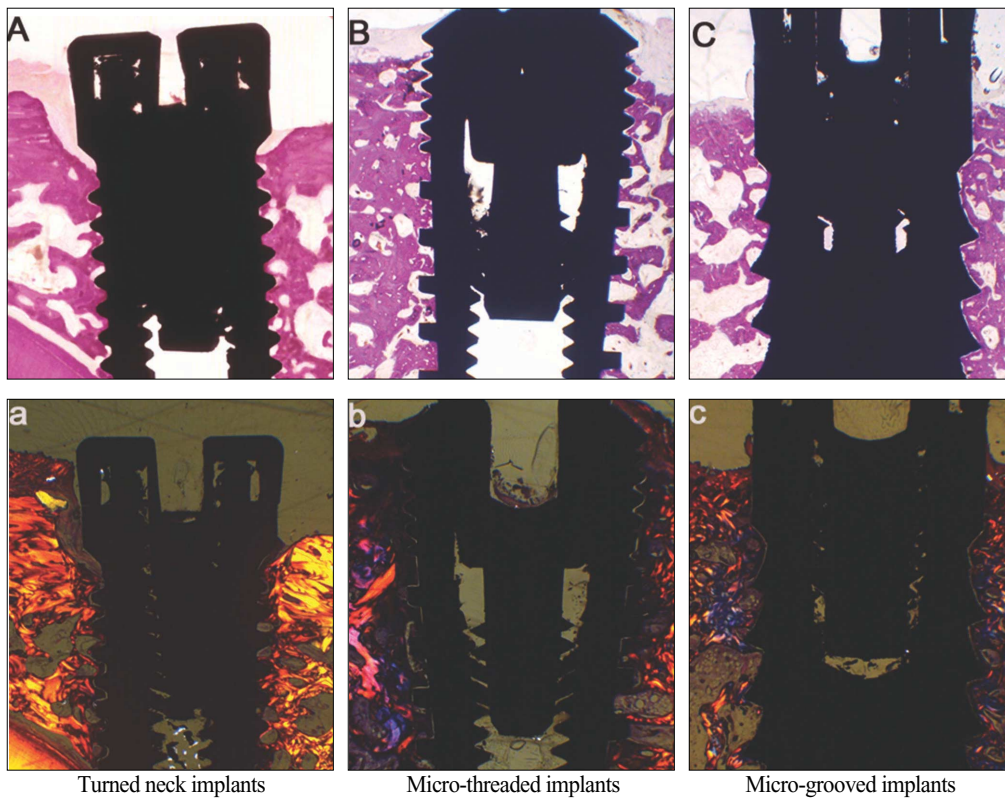
bones were positioned further away from the surface of the implants (Fig. 2).

For the observation of soft tissue Masson's trichrome staining was used. These allowed much clear examination of collagen organisation under the polarized light. In the TN, the collagens were aligned along the implant surface, creating typical parallel collagen fibres as expected.

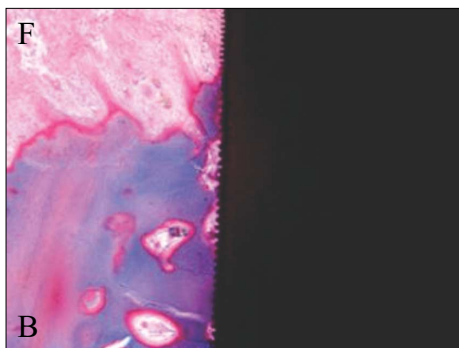
The MG implants had bone attachments to the MG surface. Some even had bone attachments to the smaller 8  $\mu$ m MG areas (Fig. 3). Nucleuses of osteoblasts have been observed in some of microgroove areas. In the soft tissue over the 8  $\mu$ m MG surfaces, the collagen organisation was 'disturbed', the organisation was not parallel to the long axis of the implant as it would normally expected and this layer was at least twice the depth of the grooves (Fig. 4). These fibroblasts had more rounded nucleus than the fibroblasts over the turned surfaces. At the junction between the micro-grooved surface and the turned surface at the neck of the MG implants had a clear distinction of the soft tissue collagen organisation was noted (Fig. 5).

## DISCUSSION

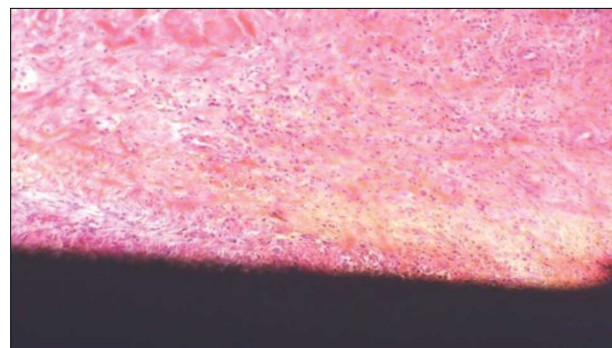
Predictable long term results could be expected from treatments with endosseous implant. Numerous researches and clinical studies have been made on creating a natural white and pink aesthetics, the successes in osseointegration, maintaining the bone level and stable soft tissue are all part of the equation.<sup>20,21</sup> Tarnow and his colleagues have shown the importance in maintaining the marginal bone height, as the response of the soft tissue height adjacent to the implant depended on the position of the bone level and the surrounding environment.<sup>22</sup> Tarnow *et al.* has shown the clinical conditions and limitations, where a maximum retention of marginal bone and the soft tissue have been described.<sup>22,23</sup> Not all clinical situations allow to follow all the criteria to meet the satisfying aesthetic result from implant dentistry. There are many clinical methods, such as



**Fig. 2.** Implant specimens in H & E staining and under polarised light.  
 A, B, C H & E staining      a, b, c MT staining under polarized light



**Fig. 3.** Bone attachment (B) over 12  $\mu\text{m}$  micro-grooved area and fibroblasts (F) attachments over 8  $\mu\text{m}$  micro-grooved area. Magnification  $\times 100$ .



**Fig. 4.** 'Disturbed' layer of soft tissue over the 8  $\mu\text{m}$  micro-grooved implant surface. Magnification  $\times 400$ .

soft and hard tissue grafting, distraction osteogenesis, combining with orthodontic treatment and, many more to create an ideal edentulous space for an implants but implant fixture design have also been developed to achieve more favourable clinical hard and soft tissue response.<sup>24-28</sup>

In this study comparisons were made between three implant designs on the hard and soft tissue responses. In

macro-structural observations on the specimens have shown that there were minimal differences between the bone developmental stages of 8 and 12 weeks of healing. This may have been due to the long healing duration. The current study was in agreement with the observation of primary and secondary osteons and marked signs of remodelling, made by Berglundh *et al.*<sup>29</sup> on bone healing in 6, 8, and 12 weeks



**Fig. 5.** The difference in the collagen organisation over the two different implant surfaces.

The surface changes from 8  $\mu\text{m}$  MG to turned surface; Note the changes in the soft tissue organization direction. Magnification  $\times 400$ .

after the implantation. Marginal bone resorption was observed from these implants but the marginal bone levels were different in each implant types. They were all submerged during healing and placed randomly in same animals but the bone level changes from the reference point varied depending on the implant type. The TN implants had shown the lowest marginal bone level than the micro-textured MG and MT implants.

Few studies have reported marginal bone losses of 1.2 to 1.9 mm in submerged and in nonsubmerged implants prior to loading but no clear reasons had been given.<sup>30,31</sup> It should however be noted that the implants used in those studies are no longer commercially available.

The bone is an active connective tissue where it continuously undergoes remodelling. The Wolff's Law states that the remodelling of the bone depends on the pressure derived from the use and disuse of the bone. The remodelling of the bone requires optimal quantity of pressure.

Under excess stimulation from occlusal loading on turned neck implants had resulted in bone resorption.<sup>32,33</sup> A loading of surrounding bone but to avoid high stress peak was suggested by Hansson *et al.*<sup>34</sup> Hansson<sup>19</sup> evaluated the level of stress on marginal bone of an implant with a retention form, using a finite element analysis. The result had shown to reduce the peak interfacial shear stress caused by a standardized axial load.<sup>16</sup>

The micro-grooves have been examined for tissue

response reactions to different surface topography. When Frenkel *et al.* had compared the bone growth over the smooth surface, micro-grooved surface and micro-grooved with growth factor, the latter two had significantly greater mechanical failure strength.<sup>17</sup> Ricci and his colleagues have looked at the both soft and hard tissue reactions in both *in vivo* and *In vitro* tests on micro textured surface created with laser.<sup>35</sup> The cell culture tests had shown a faster growth rate on the micro-grooved surfaces in the direction of grooves. With bone tissue, the scanning electron microscope had shown the orientation of the tissue was parallel to the direction of the grooves and the shear strength tests on the bone attachments to the grooves were greater than the smooth surface. In the current study the orientation of the fibroblasts and the osteoblasts were not possible to examine but MG had more bones retained near to reference point.

This favourable observation was also reflected in bone implant contact values between three implant systems. With increase in time the values increased in all three systems but the BIC values were higher in MG than others. As described above the advantage of microgrooves on cell migration may have influenced this measurement. However, the bone area measurements were less in MG than in MT implants. The small space within each thread in MG meant that the bone fill in the MG treads were either all or nothing. This may provide explanation for the lower bone area value and these methods for evaluating the osseointegration for MG implants should be taken with a caution.

Most widely accepted soft tissue healing around implant had been a scar like tissue reaction with parallel collagen fibre direction.<sup>36</sup> The soft tissue response from TN was in agreement with the previously reported observation. The MT implants was in agreement with the observation made by Buser<sup>36</sup> but at a higher magnification, macro observation may presented with limited parallel tissue organization. Abrahamsson *et al.*<sup>37</sup> looked at the soft tissue attachment between the healing abutments with turned surface or rough surface in an animal model. He and his colleagues found that the roughness had no effect on the soft tissue attachments. The soft tissue response of MG implant surface in this study was similar to observations made by Chehroudi *et al.*<sup>38</sup> Kim *et al.*<sup>39</sup> that the direction of fibroblasts was not in parallel to the implant surface. The

reaction by the soft tissue over MG seems to be more favourable than other surfaces.

Despite the efforts to improve implant design, some authors had cautioned for a greater gain may be seen with improvement in surgical routine.<sup>40</sup> The tissue reactions, however favoured implant with retention features. Further longitudinal clinical studies with connection with abutments to oral cavity and loading on micro-textured implants are recommended.

## CONCLUSION

This is an animal study which looked at the marginal bone level and the soft tissue reaction between different implant systems with various neck designs.

Within the limitation of this animal study the following statement can be concluded;

1. A clear morphometric differences in the bone area could not be noticed between MT and MG implant neck types.
2. The BIC in MG implants were slightly higher than corresponding healing times of MT and TN implants. Higher values of the BIC could be measured in week 12 specimens than in week 8 specimens.
3. In the marginal bone level, there was marked lowering with the TN implants and least with MG implants from the reference point. There were higher marginal bone levels in week 12 than week 8 in MT and MG implants specimens but with minimal differences in TN implant specimens.
4. With MT and MG implant surfaces, the collagen alignments were not parallel to the long axis of the implants.

The MT and MG implants, especially MG implants had advantageous tissue response in comparison to the turned neck implants.

## REFERENCE

1. Adell R, Lekholm U, Rockler B, Brånemark PI. A 15-year study of osseointegrated implants in the treatment of the edentulous jaw. *Int J Oral Surg* 1981;10:387-416.
2. Albrektsson T, Zarb G, Worthington P, Eriksson AR. The long-term efficacy of currently used dental implants: a review and proposed criteria of success. *Int J Oral Maxillofac Implants* 1986;1:11-25.
3. Smith DE, Zarb GA. Criteria for success of osseointegrated endosseous implants. *J Prosthet Dent* 1989;62:567-72.
4. Lekholm U, Gunne J, Henry P, Higuchi K, Lindén U, Bergström C, van Steenberghe D. Survival of the Brånemark implant in partially edentulous jaws: a 10-year prospective multicenter study. *Int J Oral Maxillofac Implants* 1999;14:639-45.
5. Buser D, Mericske-Stern R, Bernard JP, Behneke A, Behneke N, Hirt HP, Belser UC, Lang NP. Long-term evaluation of non-submerged ITI implants. Part 1: 8-year life table analysis of a prospective multi-center study with 2359 implants. *Clin Oral Implants Res* 1997;8:161-72.
6. Jemt T, Pettersson P. A 3-year follow-up study on single implant treatment. *J Dent* 1993;21:203-8.
7. Chou CT, Morris HF, Ochi S, Walker L, DesRosiers D. AICRG, Part II: Crestal bone loss associated with the Ankylos implant: loading to 36 months. *J Oral Implantol* 2004;30:134-43.
8. de Bruyn H, Collaert B, Lindén U, Björn AL. Patient's opinion and treatment outcome of fixed rehabilitation on Brånemark implants. A 3-year follow-up study in private dental practices. *Clin Oral Implants Res* 1997;8:265-71.
9. Kan JY, Rungcharassaeng K, Lozada J. Immediate placement and provisionalization of maxillary anterior single implants: 1-year prospective study. *Int J Oral Maxillofac Implants* 2003;18:31-9.
10. Tarnow DP, Cho SC, Wallace SS. The effect of inter-implant distance on the height of inter-implant bone crest. *J Periodontol* 2000;71:546-9.
11. Khang W, Feldman S, Hawley CE, Gunsolley J. A multi-center study comparing dual acid-etched and machined-surfaced implants in various bone qualities. *J Periodontol* 2001;72:1384-90.
12. Ellingsen JE, Johansson CB, Wennerberg A, Holmén A. Improved retention and bone-to-implant contact with fluoride-modified titanium implants. *Int J Oral Maxillofac Implants* 2004;19:659-66.
13. Jung YC, Han CH, Lee KW. A 1-year radiographic evaluation of marginal bone around dental implants. *Int J Oral Maxillofac Implants* 1996;11:811-8.
14. Abrahamsson I, Berglundh T, Wennström J, Lindhe J. Department of Periodontology, Göteborg University, Sweden. The peri-implant hard and soft tissues at different implant systems. A comparative study in the dog. *Clin Oral Implants Res* 1996;7:212-9.
15. Astrand P, Engquist B, Dahlgren S, Gröndahl K, Engquist E, Feldmann H. Astra Tech and Brånemark system implants: a 5-year prospective study of marginal bone reactions. *Clin Oral Implants Res* 2004;15:413-20.
16. Hansson S. The implant neck: smooth or provided with retention elements. A biomechanical approach. *Clin Oral Implants Res* 1999;10:394-405.

17. Frenkel SR, Simon J, Alexander H, Dennis M, Ricci JL. Osseointegration on metallic implant surfaces: effects of microgeometry and growth factor treatment. *J Biomed Mater Res* 2002;63:706-13.
18. Sennerby L, Ericson LE, Thomsen P, Lekholm U, Astrand P. Structure of the bone-titanium interface in retrieved clinical oral implants. *Clin Oral Implants Res* 1991;2:103-11.
19. Mohammadi S, Esposito M, Hall J, Emanuelsson L, Krozer A, Thomsen P. Long-term bone response to titanium implants coated with thin radiofrequent magnetron-sputtered hydroxyapatite in rabbits. *Int J Oral Maxillofac Implants* 2004;19:498-509.
20. Kan JY, Rungcharassaeng K, Lozada J. Immediate placement and provisionalization of maxillary anterior single implants: 1-year prospective study. *Int J Oral Maxillofac Implants* 2003;18:31-9.
21. Gotfredsen K. A 5-year prospective study of single-tooth replacements supported by the Astra Tech implant: a pilot study. *Clin Implant Dent Relat Res* 2004;6:1-8.
22. Tamow D, Elian N, Fletcher P, Froum S, Magner A, Cho SC, Salama M, Salama H, Garber DA. Vertical distance from the crest of bone to the height of the interproximal papilla between adjacent implants. *J Periodontol* 2003;74:1785-8.
23. Tamow DP, Cho SC, Wallace SS. The effect of inter-implant distance on the height of inter-implant bone crest. *J Periodontol* 2000;71:546-9.
24. Pikos MA. Block autografts for localized ridge augmentation: Part I. The posterior maxilla. *Implant Dent* 1999;8:279-85.
25. Woo I, Le BT. Maxillary sinus floor elevation: review of anatomy and two techniques. *Implant Dent* 2004;13:28-32.
26. McAllister BS. Histologic and radiographic evidence of vertical ridge augmentation utilizing distraction osteogenesis: 10 consecutively placed distractors. *J Periodontol* 2001;72:1767-79.
27. Mazzonetto R, Serra E, Silva FM, Ribeiro Torezan JF. Clinical assessment of 40 patients subjected to alveolar distraction osteogenesis. *Implant Dent* 2005;14:149-53.
28. Schwartz-Arad D, Levin L, Ashkenazi M. Treatment options of untreatable traumatized anterior maxillary teeth for future use of dental implantation. *Implant Dent* 2004;13:11-9.
29. Berglundh T, Abrahamsson I, Lang NP, Lindhe J. De novo alveolar bone formation adjacent to endosseous implants. *Clin Oral Implants Res* 2003;14:251-62.
30. Astrand P, Engquist B, Anzen B, Bergendal T, Hallman M, Karlsson U, Kvint S, Lysell L, Rundcrantz T. Nonsubmerged and submerged implants in the treatment of the partially edentulous maxilla. *Clin Implant Dent Relat Res* 2002;4:115-27.
31. Engquist B, Astrand P, Anzen B, Dahlgren S, Engquist E, Feldmann H, Karlsson U, Nord PG, Sahlholm S, Svårdström P. Simplified methods of implant treatment in the edentulous lower jaw. A controlled prospective study. Part I: one-stage versus two-stage surgery. *Clin Implant Dent Relat Res* 2002;4:93-103.
32. Quirynen M, Naert I, van Steenberghe D. Fixture design and overload influence marginal bone loss and fixture success in the Brånemark system. *Clin Oral Implants Res* 1992;3:104-11.
33. Wiskott HW, Belser UC. Lack of integration of smooth titanium surfaces: a working hypothesis based on strains generated in the surrounding bone. *Clin Oral Implants Res* 1999;10:429-44.
34. Hansson S, Werke M. The implant thread as a retention element in cortical bone: the effect of thread size and thread profile: a finite element study. *J Biomech* 2003;36:1247-58.
35. Ricci JL, Charvet J, Frenkel R, Chang P, Nadkarni P, Turner J, Alexander H. Bone response to laser microtextured surfaces. In: *Bone Engineering*, edited by JE Davies, Em2 Inc., Toronto, Ont. Canada, Chapter 25, pp 282-94, 2000.
36. Buser D, Weber HP, Donath K, Fiorellini JP, Paquette DW, Williams RC. Soft tissue reactions to non-submerged unloaded titanium implants in beagle dogs. *J Periodontol* 1992;63:225-35.
37. Abrahamsson I, Zitzmann NU, Berglundh T, Linder E, Wennerberg A, Lindhe J. The mucosal attachment to titanium implants with different surface characteristics: an experimental study in dogs. *J Clin Periodontol* 2002;29:448-55.
38. Chehroudi B, Gould TR, Brunette DM. Titanium-coated micromachined grooves of different dimensions affect epithelial and connective-tissue cells differently *in vivo*. *J Biomed Mater Res* 1990;24:1203-19.
39. Kim H, Murakami H, Chehroudi B, Textor M, Brunette DM. Effects of surface topography on the connective tissue attachment to subcutaneous implants. *Int J Oral Maxillofac Implants* 2006;21:354-65.
40. Albrektsson T. Is surgical skill more important for clinical success than changes in implant hardware? *Clin Implant Dent Relat Res* 2001;3:174-5.

## MARGINAL TISSUE RESPONSE TO DIFFERENT IMPLANT NECK DESIGN

Hanna Eun Kyong Bae<sup>1</sup>, BDS, MDS, Moon-Kyu Chung<sup>1</sup>, DDS, PhD,

In-Ho Cha<sup>2</sup>, DDS, PhD, Dong-Hoo Han<sup>1\*</sup>, DDS, PhD

<sup>1</sup>*Department of Prosthodontics, Yonsei University College of Dentistry, Seoul, South Korea*

<sup>2</sup>*Department of Oral and Maxillofacial Surgery, Yonsei University College of Dentistry, Seoul, South Korea*

**STATEMENT OF PROBLEM:** Loss of the marginal bone to the first thread have been accepted but continuous effort have been made to reduce this bone loss by varying implant design and surface texture. **PURPOSE:** This animal study has examined the histomorphometric variations between implants with micro-thread, micro-grooved and turned surfaced neck designs. **MATERIAL AND METHODS:** Four mongrel dogs have been used the premolars removed and left to heal for three months. One of each implant systems with turned neck, micro-thread and micro-grooved were placed according to the manufacturers' protocol and left submerged for 8 and 12 weeks. These were then harvested for histological examination. **RESULTS:** The histologically all samples were successfully osseointegrated and active bone remodelling adjacent to implants. With the micro-grooved implants 0.40 mm and 0.26 mm of the marginal bone level changes were observed at 8 and 12 weeks respectively. The micro-threaded implants had changes of 0.79 mm and 0.56 mm at 8 and 12 weeks respectively. The turned neck designed implants had marginal bone level changes of 1.61 mm and 1.63 mm in 8 and 12 weeks specimens. A complex soft tissue arrangement could be observed against micro-threaded and micro-grooved implant surfaces. **CONCLUSION:** Within the limitations of this study, it could be concluded that implants with micro-grooved had the least and the turned neck designed implants had the most changes in the marginal bone level. The textured implant surfaces affect soft tissue responses.

**KEY WORDS:** Micro texture, Marginal bone level, Implant design

*Corresponding Author: Dong-Hoo Han*

*Department of Prosthodontics, College of Dentistry, Yonsei University*

*134 Shinchon-dong, Seodaemoon-gu, 120-752, Seoul, South Korea +82-2-22283156: e-mail, donghooan@yuhs.ac*

*Article history*

*Received October 23, 2008 Last Revision November 24, 2008 Accepted November 28, 2008.*