

## Ectopic Migration of an Adult Heartworm in a Dog with Dirofilariasis

Hyun-Wook Oh<sup>1</sup>, Hyung-Kyou Jun<sup>1</sup>, Myung-Jo You<sup>2</sup>, Mineo Hayasaki<sup>3</sup> and Kun-Ho Song<sup>1,\*</sup>

<sup>1</sup>Laboratory of Veterinary Internal Medicine, College of Veterinary Medicine, Chungnam National University, Daejeon 305-764, Korea;

<sup>2</sup>Laboratory of Veterinary Parasitology, College of Veterinary Medicine and Biosafety Research Center, Chonbuk National University, Jeonju 561-756,

Korea; <sup>3</sup>Veterinary Clinical Center, School of Veterinary Medicine, Yamaguchi National University, Yamaguchi 753-8515, Japan

**Abstract:** A 3-yr-old female mongrel dog was referred to the Veterinary Teaching Hospital of Chungnam National University in the Republic of Korea. An adult heartworm, *Dirofilaria immitis*, was found in the abdominal cavity of the dog during spaying. Dirofilariasis in this dog was also diagnosed by modified Knott's test, ELISA test, and PCR analysis. The present case is the first report on the migration of an adult dog heartworm to the abdominal cavity of a dog in the Republic of Korea.

**Key words:** *Dirofilaria immitis*, dog, migration, abdominal cavity

### INTRODUCTION

The heartworm disease is an infectious disease of dogs with *Dirofilaria immitis* combined with cardiovascular and circulatory abnormalities. The heartworm disease can become a serious health risk when associated with a severe infection. Adult heartworms normally live in the pulmonary artery and right ventricle [1]. Much less frequently, immature 5th-stage larvae (L<sub>5</sub>) may migrate aberrantly to other sites, including the brain, spinal cord, liver, epidural space, anterior chamber of the eye, vitreous, and peritoneal cavity [1]. In Republic of Korea, Pak and Lee [2] first reported that microfilaremic rate of the canine heartworm was 21% in Chinju area, and Song et al. [3] reported that 339 (40%) of 848 samples tested with antigen detecting ELISA kits showed positive reactions for *D. immitis* in 4 different provinces. The present case is the first report on migration of an adult heartworm to the abdominal cavity of a dog nonetheless the Republic of Korea is an enzootic area with a high prevalence of dirofilariasis.

### CASE REPORT

A 3-yr-old female mongrel dog for spaying was referred to the Veterinary Teaching Hospital of Chungnam National University, Republic of Korea. The physical examination showed no abnormal clinical signs or findings. The complete blood count and serum chemistry profiles were within normal ranges, except for

aspartate transaminase 161 U/L (normal reference range; 22-84) and, creatine kinase 1,400 U/L (normal reference range; 51-485). A long slender nematode was found in the abdominal cavity of the dog during the spaying (Fig. 1). This parasite was a 12 cm long male heartworm with a coiled tail portion. Many microfilariae were detected by a direct blood smear and Modified Knott's test [4]. Electrocardiography showed a deep S wave pattern, which indicates a right ventricle hypertrophy. This was attributed to an infection of many adult worms in the right ventricle and pulmonary artery. A canine heartworm antigen detecting kit (SNAP test, IDEXX Laboratories, Westbrook, Maine, USA) was employed according to the protocol provided by the manufacturer. The ELISA kit test showed a strong positive reaction, which was attributed to a heavy infection of *D. immitis*. The worm found in the abdominal cavity was lysed in 0.1 M Tris-HCl (pH 8.0) containing 1% SDS, 0.1 M NaCl, and 10 mM EDTA. The samples were treated with proteinase K (100 µg/ml) at 55°C for 2 hr. The DNA was extracted with phenol/chloroform, precipitated by ethanol, and then dissolved in 50 µl of a TE buffer (10 mM Tris-HCl pH 8.0, 1 mM EDTA). The primers used for PCR amplification were 5'-GCATCTTAGAACTTGGT CCATCC-3' (forward), and 5'-CAAGCGTATTACCGCCGAC-3' (reverse), which have been described by Watts et al. [5] for the amplification of the 440-bp 16S rRNA gene segment. PCR was performed in 50 µl reaction mixtures, which contained 5 µl template DNA, 2 µl 20 pmol of each primer, 4 µl 200 mM of each dNTP, 1.25 U rTaq DNA polymerase (Takara, Tokyo, Japan), and 5 µl 10 × PCR buffer (10 mM Tris-HCl, 1.5 mM MgCl<sub>2</sub>, and 0.001% gelatin). The thermal cycler was set at 94°C for 3 min, to activate the poly-

• Received 8 April 2008, accepted after revision 8 July 2008.

\* Corresponding author (songkh@cnu.ac.kr)

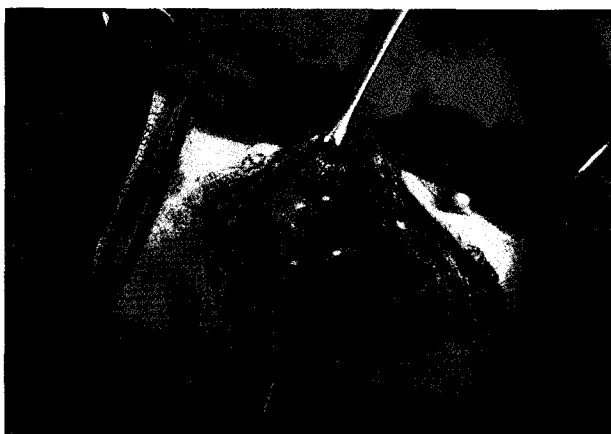

Fig. 1. An adult *Dirofilaria immitis* was found in the abdominal cavity of a dog during spaying.

merase, which was followed by 30 cycles of denaturation at 94°C for 30 sec, annealing at 55°C for 40 sec and extension at 72°C for 50 sec. A 5- $\mu$ l sample of the PCR products was then analyzed by electrophoresis in 0.8%-agarose gel followed by ethidium-bromide staining and photography. PCR analysis for an adult worm revealed a heartworm DNA-positive reaction (Fig. 2). Therefore, it was also confirmed that the worm detected in the abdominal cavity was *D. immitis* by PCR analysis.

### DISCUSSION

The Republic of Korea is one of the enzootic regions of *D. immitis*, and the prevalence in dogs appears to have increased recently [3,6]. This heartworm is transmitted by many different species of mosquitoes [1]. Lee et al. [7] reported the detection of heartworm DNA in mosquitoes, such as *Anopheles sinensis*, *Aedes vexans nipponii* and *Culex pipiens* in Gyeonggi-do and Gangwon-do, the Republic of Korea. Dogs with aberrantly located adult heartworms have been reported since 1856, and Tada et al. [8] reported a human case of *D. immitis* infection occurring in the abdominal cavity. Heartworms have been found in many body sites; however, the mechanism for the aberrant location of heartworms has not been determined [9]. Dibbell [10] first reported the detection of a female *D. immitis* in the abdominal cavity, but no microfilariae were observed in the blood. Often there is no evidence of heartworms present, and the aberrant worm is not discharging microfilariae. The simultaneous occurrence of worms in their normal habitat causes parasitemia [11]. In our case, many microfilariae were observed by optical microscopy, which may be due to the concurrent

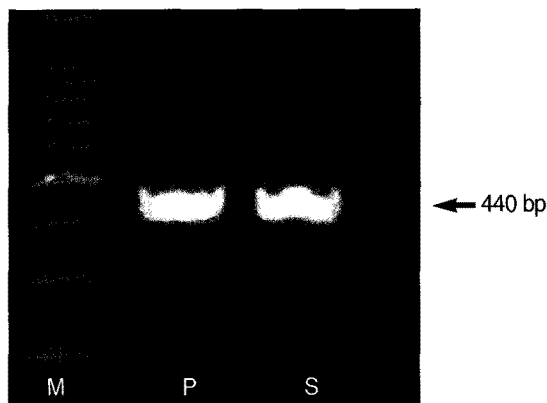


Fig. 2. PCR-based detection of *D. immitis* DNA in an adult worm found in the abdominal cavity of the dog. M is a 100-bp marker. P is a *D. immitis* DNA-positive control. S is an adult worm collected from abdominal cavity.

infection of *D. immitis* in the right ventricle and pulmonary artery. Treatment of aberrantly migrating heartworms requires either nothing, surgical excision of the offending parasite, adulticidal therapy, or symptomatic treatment [1]. Removal of the heartworm from the abdominal cavity is recommended if it affects the gastrointestinal tract, indirectly. Further studies are needed to elucidate the mechanism for the ectopic migration of heartworms.

### REFERENCES

1. Ettinger SJ. Textbook of Veterinary Internal Medicine. 6th ed. St. Louis, USA. Elsevier Saunders. 2005, p 1134.
2. Pak UB, Lee HS. Studies on the infection rate of *Dirofilaria immitis* in Chinju area by use of blood test and intracutaneous test. Bull Chinju Agricul College 1962; 1: 54-58.
3. Song KH, Lee SE, Hayasaki M, Shiramizu K, Kim DH, Cho KW. Seroprevalence of canine dirofilariasis in South Korea. Vet Parasitol 2003; 114: 231-236.
4. Newton WL, Wright WH. The occurrence of a dog filariid other than *Dirofilaria immitis* in the United States. J Parasitol 1956; 42: 246-256.
5. Watts KJ, Courteny CH, Reddy GR. Development of a PCR and probe-based test for the sensitive and specific detection of the dog heartworm *Dirofilaria immitis*, in its mosquito intermediate host. Mol Cell Probes 1999; 13: 425-430.
6. Byeon KH, Kim BJ, Kim SM, Yu HS, Jeong HJ, Ock MS. A serological survey of *Dirofilaria immitis* infection in pet dogs of Busan, Korea and effects of chemoprophylaxis. Korean J Parasitol 2007; 45: 27-32.
7. Lee SE, Kim HC, Chong ST, Klein TA, Lee WJ. Molecular survey of *Dirofilaria immitis* and *Dirofilaria repens* by direct PCR for wild caught mosquitoes in the Republic of Korea. Vet Parasitol 2007; 148: 149-155.

8. Tada I, Sakaguchi Y, Eto K. *Dirofilaria* in the abdominal cavity of a man in Japan. *Am J Trop Med Hyg* 1979; 28: 988-990.
9. Goggin JM, Biller DS, Rost CM, DeBey BM, Ludlow CL. Ultrasonographic identification of *Dirofilaria immitis* in the aorta and liver of a dog. *J Am Vet Med Assoc* 1997; 210: 1635-1637.
10. Dibbell CB. *Dirofilaria immitis* in abdominal cavity of dog. *J Am Vet Med Assn* 1951; 118: 298.
11. Otto GF. Occurrence of the heartworm in unusual locations and in unusual hosts. In Otto GF, *Proceedings of the Heartworm Symposium '74*. Auburn, USA. VM Publishing Co., Bonner Springs. 1975, p 6-12.