

Case Report

Oral Extrusion of Screw after Anterior Cervical Interbody Fusion

Jin Soo Lee, M.D., Dong-Ho Kang, M.D., Soo Hyun Hwang, M.D., Jong Woo Han, M.D.

Department of Neurosurgery, Gyeongsang National University School of Medicine, Jinju, Korea

We present a case of delayed oral extrusion of a screw after anterior cervical interbody fusion in a 68-year-old man with osteoporosis. Fifteen months earlier, he had undergone C5 corpectomy and anterior cervical interbody fusion at C4-6 for multiple spinal stenoses. The patient was nearly asymptomatic, except for a foreign body sensation in his throat. We conclude that the use of a mesh graft or other instrument in elderly patients and those with osteoporosis or problematic bone quality should be considered carefully and that if surgery were to be performed, periodic postoperative follow-up evaluations are mandatory.

KEY WORDS : Extrusion · Instrumentation · Cervical · Spine · Complication.

INTRODUCTION

Anterior cervical spine fusion and stabilization is a well-established procedure for cervical myelopathy, cervical radiculopathy, neoplasms, cervical spondylitic diseases, and cervical trauma⁹⁾. Although injuries to the pharynx and esophagus are known complications of anterior cervical spine surgery¹³⁾, delayed pharyngeal or esophageal perforation is rare¹⁷⁾. Extrusion of the cervical graft is extremely rare complication. We report a rare but potentially serious and life-threatening complication of the extrusion of a cervical graft.

CASE REPORT

A 68-year-old man was admitted to our hospital with a 4-month history of neck pain and left upper extremity weakness. Cervical spine MRI and CT findings showed congenital blocked C3-4 vertebrae and severe degenerative spinal stenosis, with compressive myelopathy at C4-5 (Fig. 1). He underwent anterior C5 corpectomy with total discectomy at the level of C4-5 and C5-6. An anterior cervical plating (Atlantis Plate, Medtronic Sofamor Danek, Memphis, TN) with screw fixation and a Pyramesh (Medtronic

Sofamor Danek, Memphis, TN) graft were performed. He also underwent posterior C4 total laminectomy for decompression (Fig. 2A). He was transferred to the rehabilitation unit at postoperative day 15. After 2 months, the patient was discharged with marked neurological improvement.

Fifteen months after the operation, the patient presented at our institution, complaining of a 2-day history of a foreign body sensation in his throat and oral extrusion of a screw (Fig. 2C). He had coughed up a screw 4 days earlier, but no new neurological deficit had occurred. Roentgenograms of the cervical spine showed the fracture and dislocation of a screw in the C4 body, and another screw was missing completely (Fig. 2B). We could not find a perforation site by

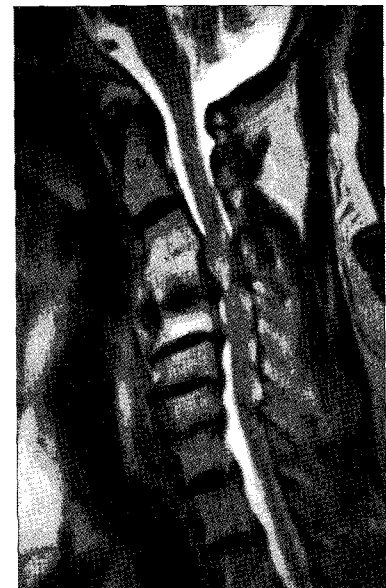


Fig. 1. Preoperative cervical spinal magnetic resonance image showing the congenital block at vertebrae C3-4 and severe degenerative spinal stenosis with compressive myelopathy at C4-5.

• Received : April 16, 2008 • Accepted : August 18, 2008
• Address for reprints : Dong-Ho Kang, M.D.
Department of Neurosurgery, Gyeongsang National University School of Medicine, 90 Chiram-dong Jinju 660-702, Korea
Tel : +82-55-750-8112, Fax : +82-55-759-0817
E-mail : ns4793@hanmail.net

esophagography, gastroduodenal endoscopy, or laryngoscopy.

Esophagography revealed that the dislodged screw had moved when the patient swallowed the contrast medium, and thus we recommended an operation to remove the screw. The patient was reluctant to undergo further surgery and declined the operation, despite his discomfort. There was no evidence of infection on lab findings or pharynx enhanced CT; however, the patient continued taking antibiotics for 7 days. Recovery was uneventful, and the patient was discharged in good condition with his throat symptoms resolved, 7 days after admission. He had regular follow-up visits to our outpatient clinic. Periodic plain X-rays of the cervical spine taken 6 months later showed that the position of the remaining screw had changed slightly, with no change in neurological status (Fig. 2D).

DISCUSSION

The use of internal stabilization devices has expanded the indications for cervical surgery, mainly for cervical spondylolytic myelopathy, with or without disc herniation. Interbody fusion is recommended when more than one disc is removed, and grafts are mandatory if partial or total spondylectomy is carried out^{3,4,21}. Plating is expected to improve the results to a fusion rate of 98% and to reduce graft-related complications, especially in multilevel fusions, also avoiding late deterioration of the cervical spine alignment obtained at surgery^{3,4}.

The preoperative and postoperative complications associated with anterior cervical fusion are well known. The complication rate after anterior cervical plating is generally low and decreases in accordance with the surgeon's experience^{3,4}. According to Zeidmann²¹, the overall complication rate associated with anterior cervical spinal fusion was approximately 5%. Complications include bone graft failure, cerebrospinal fluid leakage, recurrent laryngeal nerve injury, quadriplegia, and even death. Rupture, loosening, and failure of the anterior plate-screw system may become a serious complication with possible damage to the anterior soft tissue structures: esophagus, trachea, and vessels. At present, however, esophageal perforation is a rare but serious complication following anterior cervical spinal surgery. Additionally, if oral graft or implant extrusion were to occur, it may be very serious or life-threatening, as it can lead to

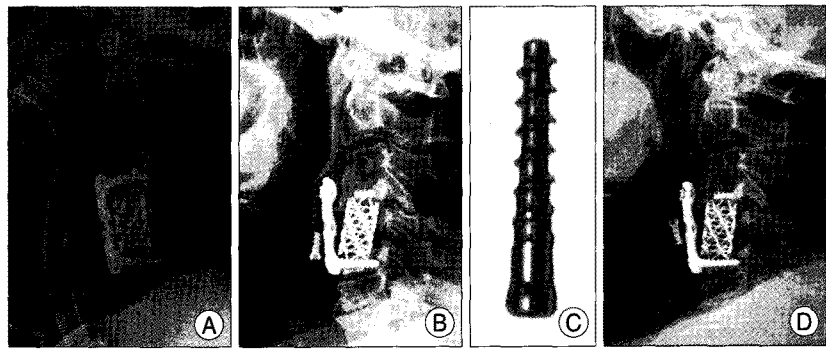


Fig. 2. A : Immediate postoperative radiographs showing anterior cervical plating at the C4-C6 level. B : Lateral cervical spine X-ray demonstrating the fracture and dislocation of the upper screws. C : The screw that the patient coughed up. D : Lateral cervical spine X-ray 6 months later, showing that the position of the remaining screw had changed slightly.

infections such as aspiration pneumonia, abscess formation at the perforated site, mediastinitis, systemic sepsis, pleuritis, fistula, and gastrointestinal problems^{2,15}. The mortality rate for all causes of esophageal perforation is about 20%, rising to 50% if treatment is delayed^{2,18}. The most catastrophic event was recently described by Riew et al. who reported a case of plate rupture and graft migration causing airway impairment and resulting in death of the patient¹⁶. The extrusion of a cervical graft has been described in the literature on only a few occasions: the oral graft extrusion of an iliac crest donor, and the oral extrusion of a screw and of a synthetic graft^{5,6,14,20}. Ours is an extremely rare case in which an expansion screw from a cervical spine locking plate migrated and was extruded orally.

There are many causes of the complications that can occur after anterior cervical plating. Esophageal perforation can be caused by iatrogenic injury during the surgical approach, owing to inappropriate placement or dislodgement of sharp-toothed retractor blades in the esophagus. Over-vigorous retraction often results in delayed local vascular complications^{1,2,7,12,19}. The chronic compression of the posterior wall of the pharyngo-esophagus by a protruding bone or fixation device may lead to focal ischemia and necrosis, cellulitis abscess, and perforation. Hanci et al. suggested that esophageal perforations were due to pressure sores caused by the metallic implant and its micro trauma effect as a mechanism of the observed esophageal perforation in three cases¹⁶. Instrumental failure may be related to the purchase of an inadequate screw, malpositioning of the screw into the disc, existing medical problems or the general condition of the patient, posterior ligamentous instability, or incomplete fusion. Many authors suggested that the main predisposing factor in the development of screw or plate extrusion is the initial malposition or suboptimal position of the screws^{8,11,15}. But, in our case, initial malposition or an intraoperative technical mistake was less likely

due to early postoperative and follow-up radiographs.

A major factor in the dislodgement and failure of the screw in our case was osteoporosis-related subsidence. The dislodgement and failure of the screw might have been influenced by increased mechanical stress attributable to additional osteoarthritis, as the peripheral articular condition was in a stressful state due to the C3-4 interbody fusion. There was also instability as a result of severe degenerative changes and facet subluxation in C3-4, 4-5, and 5-6 on preoperative CT images, and there was additional injury in the posterior tension band due to posterior decompression. Thus, the use of a mesh graft or other instrument in elderly patients or those with osteoporosis or problematic bone quality should be carefully considered. Furthermore, periodic follow-up would be necessary if such surgery were to be performed in these patients.

The treatment of instrumental failure depends on the severity of the problem, the patient's general condition, and the presence of complications. Broad-spectrum antibiotics and primary repair form the basis of management in early cases; delayed perforations with abscess formation are treated with incision and drainage, broad-spectrum antibiotics, clearing of the throat, and gastrostomy¹⁷. Asymptomatic extrusion of the graft into the gastrointestinal tract should be watched carefully for the development of complications. Special attention should also be given to the surgical technique, because at least some instrumentation failures appear to be related to malpositioning of the screw and failure of the fusion^{8,11,15}.

Fortunately, except for a transient foreign body sensation in the throat, there was no abscess formation or osteomyelitis in our case. The erythrocyte sedimentation rate and the C-reactive protein were normal, and there was no enhanced lesion in the pharynx on enhanced CT. Spontaneous healing and recovery without significant morbidity might have been the result of the small diameter of the screw and its slow migration, which gave the esophageal perforation time to heal and allowed for closure of the defect^{10,15}.

CONCLUSION

We report a very rare case of oral extrusion of a screw that presented as a foreign body sensation in the throat after anterior cervical spine plating. We conclude that the use of a mesh graft or other instrument in elderly patients and those with osteoporosis or problematic bone quality should be considered carefully and that if surgery were to be per-

formed, periodic postoperative follow-up would be necessary.

References

- Balmaseda MT, Pellioni DJ : Esophagocutaneous fistula in spinal cord injury : a complication of anterior cervical fusion. *Arch Phys Med Rehabil* 66 : 783-784, 1985
- Bohlman HH : Complications of treatment of fracture dislocations of the cervical spine : *Complications in orthopedic surgery*, Vol. 2, CH Epps, ed; New York : JB Lippincott, 1978, pp 622-623
- Bose B : Anterior cervical fusion using Caspar plating : analysis of results and review of the literature. *Surg Neurol* 49 : 25-31, 1998
- Caspar W, Barbier DD, Klara PM : Anterior cervical fusion and Caspar plate stabilization for cervical trauma. *Neurosurgery* 25 : 491-502, 1989
- Cavanagh SP, Tyagi A, Marks P : Extrusion of BOP-B graft orally following anterior cervical discectomy and fusion. *Br J Neurosurg* 10 : 417-418, 1996
- Chataigner H, Gangloff S, Onimus M : Elimination spontanée de vis d'ostéosynthèse cervicale antérieure par les voies naturelles. *Rev Chir Orthop* 83 : 78-82, 1997
- English GM, Hsu S, Edgar R, Gibson-Eccles M : Esophageal trauma in patients with spinal cord injury. *Paraplegia* 30 : 903-912, 1992
- Fountas KN, Kapsalaki EZ, Machinis T, Robinson JS : Extrusion of a screw into the gastrointestinal tract after anterior cervical spine plating. *J Spinal Disord Tech* 19 : 199-203, 2006
- Gaudinez RF, English GM, Gebhard JS, Brugman JL, Donaldson DH, Brown CW : Esophageal perforations after anterior cervical surgery. *J Spinal Disord* 13 : 77-84, 2000
- Gazzeri R, Tamorri M, Faiola A, Gazzeri G : Delayed migration of a screw into gastrointestinal tract after anterior cervical spine plating. *Spine* 33 : E268-E271, 2008
- Hanci M, Toprak M, Sarioglu AC, Kaynar MY, Uzan M, Islak C : Oesophageal perforation subsequent to anterior cervical spine screw/plate fixation. *Paraplegia* 33 : 606-609, 1995
- Kuriloff DB, Blaugrund S, Ruan J, O'Leary P : Delayed neck infection following anterior spine surgery. *Laryngoscope* 97 : 1094-1098, 1987
- Newhouse KE, Lindsey RW, Clark CR, Lieponis J, Murphy J : Oesophageal perforation following anterior cervical spine injury. *Spine* 14 : 1051-1053, 1989
- Ogle K, Palsingh J, Hewitt C : Osteophytosis : a complication of cervical spine surgery. *Br J Neurosurg* 6 : 607-609, 1992
- Pomili A, Canitano S, Caroli F, Caterino M, Crecco M, Raus L, et al : Asymptomatic esophageal perforation caused by late screw migration after anterior cervical plating : report of a case and review of relevant literature. *Spine* 27 : E499-E502, 2002
- Riew KD, Sethi NS, Devney J, Goette KRN, Choi K : Complications of buttress plate stabilization of cervical corpectomy. *Spine* 24 : 2404-2410, 1999
- Sharma RR, Sethu AU, Lad SD, Turel KE, Pawar SJ : Pharyngeal perforation and spontaneous extrusion of the cervical graft with its fixation device : a late complication of C2-C3 fusion via anterior approach. *J Clin Neurosci* 8 : 464-468, 2001
- Skinner DB, Belsey RHR : *Penetrating wounds, crush injuries, foreign bodies, and other cases of tracheoesophageal fistula in Management of esophageal disease*. Philadelphia : WB Saunders, 1988, pp792-801
- Smith MD, Bolesta MJ : Esophageal perforation after anterior cervical plate fixation : a report of two cases. *J Spinal Disord* 5 : 357-362, 1992
- Yee GKH, Terry AF : Esophageal perforation by an anterior cervical fixation device. *Spine* 18 : 522-527, 1993
- Zeidman SM, Ducker TB, Raycroft J : Trends and complications in cervical spine surgery : 1989-1993. *J Spinal Disord* 10 : 523-526, 1997