

## A study on wound healing activity of *Bacopa monnieri* Linn. aerial parts

Tirtha Ghosh<sup>1,\*</sup>, Tapan Kumar Maity<sup>2</sup>, Deepak Kumar Dash<sup>2</sup> and Anindya Bose<sup>1</sup>

<sup>1</sup>*Institute of Pharmacy and Technology, Salipur, Cuttack, Orissa, 754202, India;* <sup>2</sup>*Departmentt. of Pharmaceutical Technology, Jadavpur University, Kolkata, 700032, India*

### SUMMARY

*Bacopa monnieri* is being used in the traditional system of medicine for a variety of ailments. In the present study, the ethanolic extract of *Bacopa monnieri* aerial parts has been studied for its wound healing activity using various models in rats. Significant increase in wound contraction and skin breaking strength were observed in the excision and incision wound models respectively. There was also significant increase in hydroxyproline content, DNA content, superoxide dismutase activity, catalase activity, glutathione level and decrease in the level of thiobarbituric acid reactive substances in the 12<sup>th</sup> day post wounding tissue of experimental rats in the ethanol extract treated groups with respect to the control group. The effect of the extract was found to be comparable with the standard drug nitrofurazone. From the results it may be concluded that the plant *Bacopa monnieri* is endowed with significant wound healing activity, thereby justifying its use in the traditional medicine. Saponins may be responsible for the observed wound healing activity.

**Key words:** *Bacopa monnieri*; Wound healing activity; Antioxidant activity; Ethanolic extract

### INTRODUCTION

Wound healing is a complicated process which is composed of a cascade of many cellular and biochemical mechanisms involving phases of hemostasis, inflammation, proliferation and remodeling. During inflammation, neutrophils migrate into the wound site and release several mediators followed by cellular activation. Oxygen free radicals or reactive oxygen species (ROS) are one of these products, generated due to excessive delivery of oxygen to tissues, and reported to be responsible for the decrease in wound strength after incision (Hogstrom *et al.*, 1988; Witte *et al.*, 1997). There is evidence that overproduction of ROS, particularly the most reactive radical hydroxyl, is followed by

the release in extracellular space and causes tissue damage (Foschi *et al.*, 1988; Reiter, 1996). Thus, wound healing might benefit from the drugs that act by inhibiting ROS. Efforts are being made all over the world to discover agents that can promote healing and thereby reduce the cost of hospitalisation and save the patient from amputation or other severe complication.

*Bacopa monnieri* Linn. (Family-Scrophulariaceae) is a creeping, glabrous, succulent herb, rooting at nodes, distributed throughout India in all plain districts, ascending to an altitude of 1,320 m (Anonymous, 1998). In Ayurveda, the plant has been used in the treatment of insanity, epilepsy and hysteria. The other reported activities include sedative, antiepileptic, vasoconstrictor and anti-inflammatory respectively (Chopra *et al.*, 1986). The ethanolic extract of the aerial parts of the plant has been reported to possess significant Anthelmintic

\*Correspondence: Tirtha Ghosh, Institute of Pharmacy and Technology, Salipur, Cuttack, Orissa, 754202, India. E-mail: tghosh75@yahoo.co.in; ghosh\_tirthag@rediffmail.com

(Ghosh *et al.*, 2005) and antimicrobial activity (Ghosh *et al.*, 2006). The plant is reported to contain tetracyclic triterpenoid saponins, bacosides A and B (Chatterjee *et al.*, 1965; Basu *et al.*, 1967), hersaponin, alkaloids viz. herpestine and brahmine and flavonoids (Anonymous, 1998). The various tribes of Orissa, India use the juice of aerial parts of *Bacopa monnieri* over the fresh cuts and wounds for quick healing. The present paper deals with the wound healing activity of ethanolic extract of the aerial parts of *Bacopa monnieri* on experimental animal wounds.

## MATERIALS AND METHODS

### Plant material

The plant was identified by the taxonomists of the Botanical Survey of India, Govt. of India, Shibpur, Howrah, India. After authentication, fresh aerial parts of the young and matured plants were collected in bulk from the rural belt of Salipur, Orissa, India during early summer, washed, shade dried and then milled in to coarse powder by a mechanical grinder. The powdered plant material (400 g) was defatted with petroleum ether (60 -80°C) and then extracted with 1.5 l of ethanol (95%) in a soxhlet apparatus. The solvent was removed under reduced pressure, which obtained a greenish-black sticky residue (yield: 11.6% w/w with respect to dried plant material). The dried extract was mixed with simple ointment i.p. (10% w/w) and was used directly over the wounds during the study.

### Preliminary phytochemical studies

The test samples were subjected to preliminary phytochemical studies using standard procedures (Trease and Evans, 1983; Harborne, 1984) to find out the nature of the phytoconstituents present with in them.

### Animals

Studies were carried out using Wistar albino rats (150 - 180 g) of male sex. The animals were grouped

and housed in polyacrylic cages (38 × 23 × 10 cm) with not more than six animals per cage and maintained under standard laboratory conditions. They were allowed free access to standard dry pellet diet (Hindustan Lever, Kolkata, India) and water *ad libitum*. All procedures described were reviewed and approved by the Institutional Animal Ethical Committee.

### Wound healing evaluation

Screening for wound healing activity was performed by excision wound model, incision wound model and estimation of hydroxyproline and DNA content in the wound tissues. Further estimation of thiobarbituric acid reactive substances (TBARS), glutathione (GSH), superoxide dismutase (SOD) and catalase (CAT) of the wound tissues were carried out in order to find out the level of ROS inhibition in the wound tissues. The selected animals were divided into three groups of six animals in each group. All the test samples were applied topically.

### Excision wound model (Shirwaikar *et al.*, 2003)

The hair on the skin of back surface of animals was removed by using a suitable depilatory (Anne French hair removing cream). The selected animals were divided into three groups of six in each. All the test samples were applied topically.

Circular wounds of approximately 10 mm diameter were inflicted on the cleared skin by cutting under mild ether anaesthesia. The areas of the wounds were measured (sq. mm) immediately by placing a transparent polythene graph paper over the wound and then tracing the area of the wound on it. This was taken as the initial wound area reading. Group-I served as negative control, which received simple ointment i.p. Group-II animals were treated with the extract (10% w/w in simple ointment i.p.) and Group-III served as positive control to which nitrofurazone (0.2% w/v in simple ointment i.p.) was applied topically. All the test samples were applied once daily. The

**Table 1.** Effect of topical application of ethanol extract of *Bacopa monnieri* on excision wounds

Group	Treatment	Percentage wound contraction on post wounding day			
		1 <sup>st</sup>	4 <sup>th</sup>	8 <sup>th</sup>	12 <sup>th</sup>
I	Vehicle	0	19.39 ± 4.33	27.96 ± 3.97	47.42 ± 2.76
II	Ethanol extract	0	19.77 ± 3.76	35.99 ± 3.18	67.08 ± 2.89**
III	Nitrofurazone	0	21.63 ± 1.74	42.59 ± 3.6*	80.99 ± 2.12**

Results expressed as mean ± SEM, for n = 6 rats in each group. All *P* values are calculated with respect to vehicle control. \**P* < 0.05, \*\**P* < 0.001.

**Table 2.** Effect of topical application of the extracts of *Bacopa monnieri* on tensile strength of incised wounds

Group	Treatment	Tensile strength in gm on 12 <sup>th</sup> post wounding day
I	Vehicle	140.0 ± 4.91
II	Ethanol extract	248.50 ± 9.18**
III	Nitrofurazone	286.66 ± 6.63**

Results expressed as mean ± SEM, for n = 6 rats in each group. All *P* values are calculated with respect to vehicle control, \**P* < 0.05, \*\**P* < 0.001.

wound area of each animal was measured on 1<sup>st</sup>, 4<sup>th</sup>, 8<sup>th</sup> and 12<sup>th</sup> post wounding day. The percentage of wound contraction was calculated on the basis of the 1<sup>st</sup> day wound area (Table 1).

#### Incision wound model (Udupa et al., 1994)

Light incisions were made on the cleared surface by cutting the skin of the animals under mild ether anaesthesia. The wounds were created at a length of about 1.5 cm. After the incision, the parted skin was kept together and stitched with black silk at both the ends of the created wound. The test samples were applied as above in a similar manner. The tensile strength was measured by using tensiometer on 12<sup>th</sup> post wounding day (Table 2).

#### Hydroxyproline and DNA estimation

At the end of 12<sup>th</sup> post wounding day excision wound tissues were analysed for hydroxyproline (Woessner, 1961) and DNA (Burton, 1956).

#### Determination of *in vivo* antioxidant activity

At the end of 12<sup>th</sup> post wounding day excision wound tissues were excised, rinsed in ice cold

normal saline, followed by 0.15 M Tris-HCl (pH 7.4) blotted dry and weighed. A 10% w/v of homogenate was prepared in 0.15 M Tris-HCl buffer and processed for the estimation of lipid peroxidation (Fraga et al., 1981). A part of homogenate after precipitating proteins with trichloroacetic acid (TCA) was used for estimation of glutathione (Ellman et al., 1959). The rest of the homogenate was centrifuged at 15,000 rpm for 15 min at 4°C. The supernatant thus obtained was used for the estimation of SOD (Kakkar et al., 1984) and CAT activity (Maehly et al., 1954). Protein was estimated according to Lowry et al. (1951).

#### Statistical analysis

Values are mean ± SEM for n = 6 animals in each group. Data were evaluated statistically using students *t*-test. *P* values < 0.05 were considered to be significant.

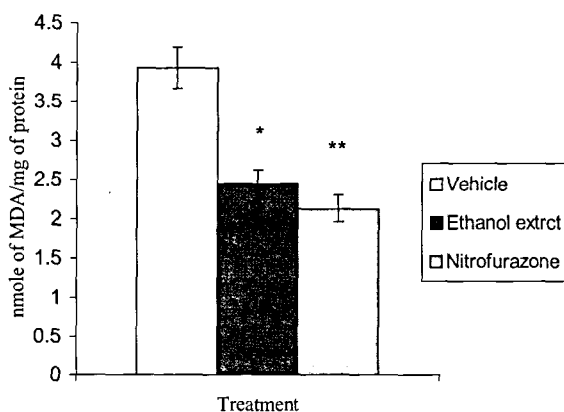
## RESULTS

The studies on excision wound healing model reveals that all the three groups showed decreased wound area from day to day. On the 12<sup>th</sup> post wounding day group I showed 47.42% healing (which might be due to self immunity of the animals), whereas the ethanol extract treated and standard drug treated groups showed 67.08% and 80.99% healing respectively (Table 1). In the incision model, the tensile strength of the resutured wound was significantly (*P* < 0.001) increased in both the ethanol extract treated and standard drug treated group (Table 2). It has been found that hydroxyproline and DNA content has increased

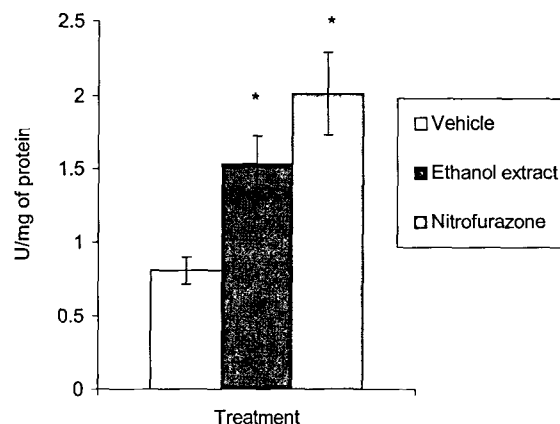
**Table 3.** Effect of ethanol extract of *Bacopa monnieri* treatment for 12 days on hydroxyproline and DNA content of the wound in rat excision model

Group	Treatment	Hydroxyproline (mg/g of tissue)	DNA (mg/g of tissue)
I	Vehicle	71.11 ± 1.85	6.44 ± 0.31
II	Ethanol extract	112.80 ± 2.01**	9.97 ± 0.40**
III	Nitrofurazone	117.57 ± 1.41**	11.21 ± 0.58**

Results expressed as mean ± SEM, for n = 6 rats in each group. All P values are calculated with respect to vehicle control, \*P < 0.05, \*\*P < 0.001.



**Fig. 1.** Effect of treatment of ethanol extract of *Bacopa monnieri* for 12 days on lipid peroxidation of excision wound tissue. Results expressed as mean ± SEM, for n = 6 rats in each group. All P values are calculated with respect to vehicle control, \*P < 0.05, \*\*P < 0.001.

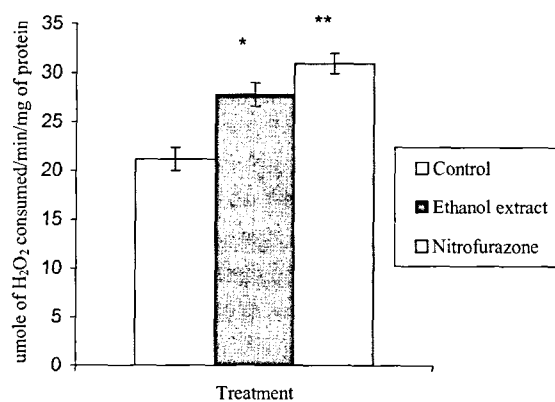


**Fig. 2.** Effect of treatment of ethanol extract of *Bacopa monnieri* for 12 days on SOD activity of excision wound tissue. Results expressed as mean ± SEM, for n = 6 rats in each group. All P values are calculated with respect to vehicle control, \*P < 0.05.

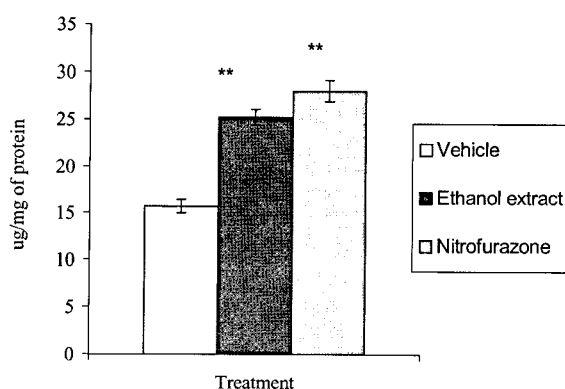
significantly ( $P < 0.001$ ) both in the extract treated and standard drug treated groups when compared with control (Group I) (Table 3). The extract and standard drug was found to reduce the levels of TBARS (Fig. 1), enhance the activities of SOD (Fig. 2) and CAT (Fig. 3) and increase the level of GSH (Fig. 4) in the 12<sup>th</sup> day post wounding tissue of excision model rats.

## DISCUSSION

Cutaneous injury is characterized by fibroplasia, angiogenesis, and re epithelization and involves the migration and proliferation of cells such as fibroblasts, endothelial cells and epithelial cells, deposition of connective tissues and counteraction of wound (Clark, 1991). These steps occur in a



**Fig. 3.** Effect of treatment of ethanol extract of *Bacopa monnieri* for 12 days on CAT activity of excision wound tissue. Results expressed as mean ± SEM, for n = 6 rats in each group. All p values are calculated with respect to vehicle control, \*P < 0.05, \*\*P < 0.001.



**Fig. 4.** Effect of treatment of ethanol extract of *Bacopa monnieri* for 12 days on GSH level of excision wound tissue. Results expressed as mean  $\pm$  SEM, for  $n = 6$  rats in each group. All  $P$  values are calculated with respect to vehicle control, \* $P < 0.05$ , \*\* $P < 0.001$ .

controlled manner by a variety of bioactive molecules like growth factors, cytokines, their receptors and matrix molecules (Ingold, 1993).

There was significant increase in rate of wound contraction in rats treated with ethanolic extract of *Bacopa monnieri*, as evidenced by enhanced epithelization of excision wound (Table 1). In resutured incision wound, wound breaking strength is determined, which indirectly represents collagenation phase of healing (Mukherjee *et al.*, 2000), and this parameter is commonly used to assess healing, perhaps because surgeons are specially interested and concerned with the strength of healed incision wounds (Patil and Kulkarni, 1985).

Again, hydroxyproline content estimation gives the net rate of synthesis and deposition of collagen in healing wounds (Madden *et al.*, 1968) and improved collagenation is often associated with increased tensile strength of wounds (Manjunatha *et al.*, 2005). In this study the ethanolic extract of *Bacopa monnieri* significantly increased breaking strength of the resutured incision wound (Table 2) and hydroxyproline content as compared to control (Table 3). Lipid peroxidation is an important process in several types of injuries. Drug that inhibits lipid peroxidation is believed to increase the viability of

collagen fibrils, increasing the strength of collagen fibers by increasing the circulation, preventing the cell damage, promoting DNA synthesis (Shobha *et al.*, 1999). The ethanolic extract of *Bacopa monnieri* significantly reduced lipid peroxidation of the wound tissue. The result is further supported by the increase in DNA content of wound tissues (Table 3). DNA synthesis is reported to augment granulation of tissue and mucopolysaccharide synthesis (Joshi *et al.*, 2003).

There is increasing evidence that lipid peroxides are generated at the injury sites and impair wound healing due to cytotoxic effects (Niwa, 1989; Elstner, 1991). The degree of oxidative injury depends on the balance between oxidant/antioxidant system (Davies, 1986). Studies showed that superoxide anion inhibited the healing of the wound and this damage could be prevented by oxygen free radical scavengers (Hogstrom, 1987; Foschi *et al.*, 1988). Thus, superoxide dismutase (Foschi *et al.*, 1988), catalase (Cetinkale *et al.*, 1999) and glutathione levels have been studied in healing due to their antioxidant effects. Further prohealing could be attributed to the antimicrobial activity (Veerapur *et al.*, 2004). Antimicrobial activity of *Bacopa monnieri* has been reported by the authors (Ghosh *et al.*, 2006), which might be responsible, at least partially for its prohealing potential.

In conclusion, the study confirms the promising wound healing activity of the ethanolic extract of aerial parts of *Bacopa monnieri*. It also provides a rationale for the use of *Bacopa monnieri* aerial parts preparation by certain tribes of India to promote wound healing. Saponins are natural products, which have been shown to possess antioxidant property (Yoshiki *et al.*, 1995; Yoshiki *et al.*, 1998; Hu *et al.*, 2002) and wound healing activity (Shukla *et al.*, 1999). Studies have confirmed that indeed oxidative stress plays an important role in the progression of wound (Foschi *et al.*, 1988; Reiter, 1996). It has been reported that *Bacopa monnieri* contains large amounts of saponins (Singh *et al.*, 1997). This fact was further supported by the

preliminary phytochemical studies. Hence, the observed wound healing activity might be due to the saponins present within the extract. Further studies regarding the isolation and characterization of the active principle responsible for the wound healing activity from the ethanolic extract is currently under progress in our laboratory.

### ACKNOWLEDGEMENTS

The authors are thankful to the taxonomists of Botanical Survey of India, Shibpur, Howrah, India for proper identification of the plant. The authors are also thankful to the Principal and the Management of Institute of Pharmacy and Technology, Salipur, Orissa, India and the authorities of Jadavpur University, Kolkata, India for providing necessary facilities to carry out the present research work.

### REFERENCES

- Anonymous. (1985) Indian Herbal Pharmacopoeia. Indian Drug Manufacturer's Association, Mumbai, India. **1**, 30-36.
- Arteel GE. (2003) Oxidants and antioxidants in alcohol-induced liver disease. *Gastroenterol.* **124**, 778-790.
- Basu N, Rastogi RP, Dhar ML. (1967) Chemical examination of *Bacopa monnieri* Wettst: Part III - Bacoside B. *Indian J. Chem.* **5**, 84-86.
- Bautista AP. (2001) Free radicals, chemokines and cell injury in HIV-I and SIV infections and alcoholic hepatitis. *Free Radic. Biol. Med.* **31**, 1527-1532.
- Burton K. (1956) A study of the condition and mechanism of diphenyl amine reaction for the colorimetric estimation of deoxy ribonucleic acid. *Biochem. J.* **62**, 351-321.
- Cetinkale O, Senel O, Bulan R. (1999) The effect of antioxidant therapy on cell-mediated immunity following burn injury in an animal model. *Burns* **25**, 113-118.
- Chatterjee N, Rastogi RP, Dhar ML. (1965) Chemical examination of *Bacopa monnieri* Part II. The constitution of Bacoside A. *Indian J. Chem.* **3**, 24-29.
- Chopra RN, Nayar SL, Chopra IC. (1986) Glossary of Indian Medicinal plants. pp. 32, National Institute of Science and Communication (CSIR), New Delhi, India.
- Clark RAF. (1991) Cutaneous Wound Repair, pp. 576, Oxford University, New York.
- Davies KJA. (1986) Intracellular proteolytic systems may function as secondary antioxidant defences: a hypothesis. *Free Radic. Biol. Med.* **2**, 155-173.
- Davlos M, Rolnaldo N. (1998) Alcoholic hepatitis. *Rev. Gastroenterol. Peru* **18**, 151-164.
- Ellman GL. (1959) Tissue sulphhydryl groups. *Arch. Biochem. Biophys.* **82**, 70-77.
- Elstner EF. (1991) Oxygen radicals--biochemical basis for their efficacy. *Klin. Wochenschr.* **69**, 949-956.
- Foschi D, Trabucchi E, Musazzi M. (1988) The effects of oxygen free radicals on wound healing. *Int. J. Tissue React.* **10**, 373-379.
- Fraga CG, Leibovitz BE, Toppel AL. (1981) Lipid peroxidation measured as TBARS in tissue characterization and comparison with homogenates and microsomes. *Free Radic. Biol. Med.* **4**, 155-161.
- Ghosh T, Maity TK, Bose A, Dash GK. (2005) Anthelmintic activity of *Bacopa monnieri*. *Indian J. Nat. Prod.* **21**, 16-19.
- Ghosh T, Maity TK, Bose A, Dash GK. (2006) A study on antimicrobial activity of *Bacopa monnieri*. Linn. aerial parts. *J. Nat. Rem.* **6**, 170-173.
- Harborne JB. (1984) Phytochemical Methods-A Guide to Modern Techniques of Plant Analysis, pp. 4-7, Chapman and Hall, New York.
- Hogstrom H. (1987) Mechanisms and prevention of decrease in wound margin strength in intestinal anastomoses and laparotomy wounds. *Acta Chir. Scand.* **539**, 1-63.
- Hogstrom H, Bondeson L, Haglund U. (1988) Neutrophil-induced decrease in wound margin strength after intestinal anastomosis--influence on collagen and mechanisms of granulocyte action. *Eur. Surg. Res.* **20**, 260-266.
- Hu J, Lee SO, Hendrich S, Murphy PA. (2002) Quantification of the group B soyasaponins by high-performance liquid chromatography. *J. Agric. Food Chem.* **50**, 2587-2594.
- Joshi SD, Aravind MB, Ashoke K, Veerapur VP, Shastry CS. (2003) Wound healing activity of *Dodonaea Viscosa* Leaves. *Indian Drugs* **40**, 549-552.
- Kakkar P, Das B, Viswanathan PN. (1984) A modified spectrophotometric assay of superoxide dismutase.

- Indian J. Biochem. Biophys.* **21**, 131-132.
- Lowry OH, Rosebrough NJ, Farr AL, Randall RJ. (1951) Protein measurement with the folin-phenol reagent. *J. Biol. Chem.* **193**, 265-275.
- Madden JW, Peacock EE. (1968) Studies on the Biology of Collagen During Wound Healing. I. Rate of Collagen Synthesis and Deposition in Cutaneous Wounds of the Rats. *Surgery* **64**, 288-294.
- Maehly AC, Chance B. (1954) Methods of Biochemical Analysis, Vol. I, pp. 357-358, Interscience, New York.
- Manjunatha BK, Vidya SM, Rashmi KV, Mankani KL, Shilpa HJ, Singh SDJ. (2005) Evaluation of wound healing potency of *Vernonia arborea* Hk. *Indian J. Pharmacol.* **37**, 223-226
- Mukherjee PK, Verpoorte R, Suresh B. (2000) Evaluation of *in vivo* wound healing activity of *hypericum patulum* leaf extracts on different wound models in rats. *J. Ethnopharmacol.* **70**, 351-321.
- Niwa Y. (1989) Lipid peroxides and superoxide dismutase (SOD) induction in skin inflammatory diseases, and treatment with SOD preparations. *Dermatolog.* **179**, 101-106.
- Patil PA, Kulkarni DR (1985) Effect of antiproliferative agents on healing of incision wounds in rats. *Indian J. Exp. Biol.* **23**, 149-150.
- Reiter RJ. (1996) Functional aspects of the pineal hormone melatonin in combating cell and tissue damage induced by free radicals. *Eur. J. Endocrinol.* **134**, 412-420.
- Shirwaikar A, Ghosh S, Rao PGM. (2003) Effect of *Gmelina arborea* Roxb. Leaves on wound healing in rats. *J. Nat. Rem.* **3**, 45-48.
- Shobha SN, Gurumadhva Raos. (1999) Effect of Hepatogard - An indigeneous formulation on dexamethasone induced antihealing effects in male albino rats. *Indian J. Physiol. Pharmacol.* **43**, 230-234.
- Shukla A, Rasik AM, Jain GK Shankar R, Kulshrestha DK, Dhawan BN. (1999) *In vitro* and *in vivo* wound healing activity of asiaticoside isolated from *Centella asiatica*. *J. Ethnopharmacol.* **65**, 1-11.
- Singh HK, Dhawan BN. (1997) Neuropsychopharmacological effects of the Ayurvedic nootropic *Bacopa monnieri* Linn. (Brahmi). *Indian J. Pharmacol.* **29**, S359-365.
- Trease GE, Evans WC. (1983) Pharmacognosy, 12<sup>th</sup> Ed. pp. 735-738, Bailliere Tindall, London.
- Udapa SL, Udapa AL, Kulkarni DR. (1994) Anti-inflammatory and wound healing properties of *Aloe vera*. *Fitoterapia* **65**, 141-145.
- Veerapur VP, Palkar BB, Srinivasa H, Kumar MS, Patra S Rao PGM, Srinivasan KK. (2004) Evaluation of aqueous extract of pulp and seeds of *Moringa oleifera* for wound healing in albino rats. *J. Nat. Rem.* **4**, 145-149.
- Witte MB, Barbul A. (1997) General principles of wound healing. In: The Surgical Clinics of North America, Wound healing, Barbul A, Saunders WB, p. 509-528, Philadelphia.
- Woessner JF. (1961) The determination of hydroxyproline in tissue and protein samples containing small portion of this imino acid. *Arch. Biochem. Biophys.* **193**, 440-447.
- Yoshiki K, Kudou S, Okubo K. (1998) Relationship between chemical structures and biological activities of triterpenoid saponins from soyabean. *Biosci. Biotechnol. Biochem.* **62**, 2291-2299.
- Yoshiki Y, Okubo K. (1995) Active oxygen scavenging activity of DDMP (2, 3-dihydro-2, 5-dihydroxy-6-methyl-4H-pyran-4-one) saponin in soybean seed. *Biosci. Biotechnol. Biochem.* **59**, 1556-1557.