

## POEMS syndrome에서의 $^{18}\text{F}$ -FDG PET/CT 소견

아주대학교 의과대학 핵의학교실  
안영실 · 윤준기 · 홍선표 · 조철우 · 윤석남

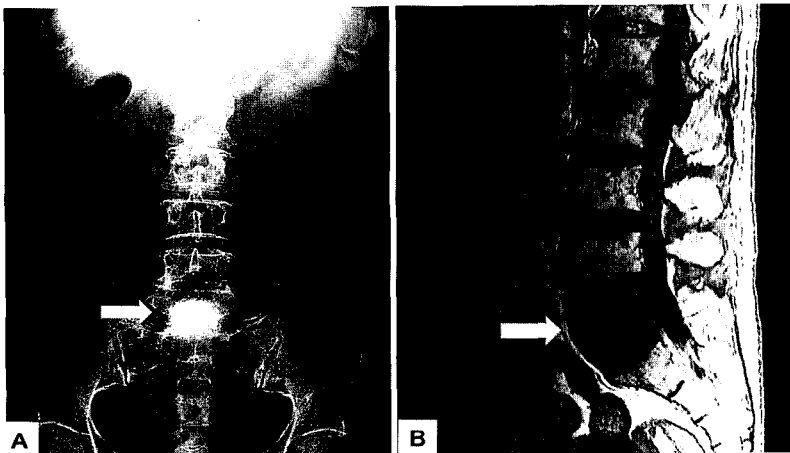
### $^{18}\text{F}$ -FDG PET/CT in POEMS Syndrome

Young-Sil An, M.D., Joon-Kee Yoon, M.D., Seon-Pyo Hong, M.D.,  
Chul-Woo Joh, Ph.D., and Seok-Nam Yoon, M.D.

Department of Nuclear Medicine and Molecular Imaging, Ajou University School of Medicine, Suwon, Korea

POEMS syndrome is a rare disorder, also known as Crow-Fukase, PEP or Takatsuki syndrome. The acronym, POEMS, represents *poly*neuropathy, *organomegaly*, *endocrinopathy*, *M* protein and skin change.<sup>1,2</sup> However, there are associated features not included in the acronym such as sclerotic bone lesions, Castlemans disease, papilledema, thrombocytosis, peripheral edema, ascites, effusion, polycythemia, fatigue and clubbing.<sup>1-5</sup> In most cases, osseous lesions in POEMS syndrome present as an isolated sclerotic deposit and that reveal as osteosclerotic myeloma.<sup>6,7</sup> Several cases of  $^{18}\text{F}$ -FDG PET in multiple myeloma involvements were reported,<sup>8</sup> but there was no previous literature that reported FDG PET findings in POEMS syndrome. We describe here a 66-year-old patient with POEMS syndrome who underwent  $^{18}\text{F}$ -FDG PET/CT image. (Nucl Med Mol Imaging 2007; 41(1):66-67)

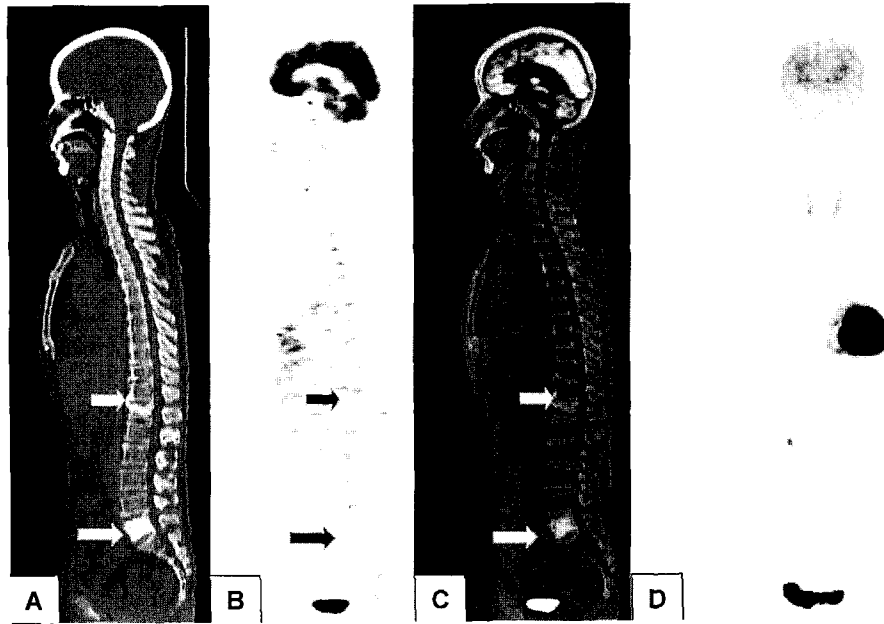
**Key Words:** POEMS,  $^{18}\text{F}$ -FDG-PET, osteosclerotic myeloma



**Fig 1.** A 66-year-old woman was referred to our hospital for tingling and burning sensation in both soles. The paresthesia progressively worsened in intensity, ascended and finally she had difficulty in gaiting. She also had hypothyroidism, and chronic back pain due to old T12 compression. Laboratory test demonstrated mild hyperinsulemia (120 mg/dl; normal range 70-110) and a marked thrombocytosis of 499,000 per microliter, a polyclonal hypergammaproteinemia with a monoclonal Ig A gammopathy (increase in lamda light chains). Plain X-ray of the lumbar spine showed an osteoclerotic lesion on L5 spine (arrow on A) and sagittal T1-weighted MR image of L-spines demonstrated decreased signal intensity on the same region (arrow on B). These clinical, laboratory and radiographic manifestations were enough to diagnose as POEMS syndrome.

• Received: 2007. 1. 17. • Accepted: 2007. 1. 24.

• Address for reprints: Seok-Nam Yoon, M.D., Department of Nuclear Medicine and Molecular Imaging, Ajou University School of Medicine, San 5, Woncheon-dong, Yeongtong-gu, Suwon, 442-749, Korea  
Tel: 82-31-219-5947, Fax: 82-31-219-5950  
E-mail: snyoon@ajou.ac.kr



**Fig 2.** The  $^{18}\text{F}$ -FDG PET/CT was obtained for further evaluation for other involvement lesions. There was no significant FDG uptake in L5 (osteosclerotic myeloma) and T12 spine (old compression fracture)(Fig 2, arrows point to lesion on from A to D, CT, PET, fusion image and whole body PET image). The patient underwent chemotherapy and radiotherapy on L5 spine as planned.

## References

1. Chong ST, Beasley HS, Daffner RH. POEMS syndrome: radiographic appearance with MRI correlation. *Skeletal radiology* 2006; 35:690-5.
2. Dispenzieri A, Kyle RA, Lacy MQ, Rajkumar SV, Therneau TM, Larson DR, et al. POEMS syndrome: definition and long-term outcome. *Blood* 2003;101:2496-506.
3. Dispenzieri A. POEMS syndrome. *Hematology(Am Soc Hematol Educ Program)* 2005;360-7.
4. Soubrier MJ, Dubost JJ, Sauvezie BJ. POEMS syndrome: a study of 25 cases and a review of the literature. French Study Group on POEMS Syndrome. *Am J Med* 1994;97:543-53.
5. Nakanishi T, Sobue I, Toyokura Y, Nishitani H, Kuroiwa Y, Satoyoshi E, et al. The Crow-Fukase syndrome: a study of 102 cases in Japan. *Neurology* 1984;34:712-20.
6. Mulleman D, Gaxatte C, Guillermin G, Leroy X, Cotten A, Duquesnoy B, Flipo RM. Multiple myeloma presenting with widespread osteosclerotic lesions. *Joint Bone Spine* 2004;71:79-83.
7. Schey S. Osteosclerotic myeloma and 'POEMS' syndrome. *Blood Rev* 1996;10:75-80.
8. Bredella MA, Steinbach L, Caputo G, Segall G, Hawkins R. Value of FDG PET in the assessment of patients with multiple myeloma. *AJR* 2005;184:1199-204.