

A case of *Diphyllobothrium latum* infection with a brief review of diphyllobothriasis in the Republic of Korea

Eun Bin LEE¹⁾, Jung Hoon SONG¹⁾, Nam Seon PARK¹⁾, Byung Kook KANG¹⁾, Hyung Suk LEE¹⁾,
Yoon Ju HAN^{1)*}, Hyo-Jin KIM²⁾, Eun-Hee SHIN²⁾ and Jong-Yil CHAI²⁾

¹⁾Department of Internal Medicine, Seoul Red Cross Hospital, Seoul 110-747,

²⁾Department of Parasitology and Tropical Medicine, Seoul National University College of Medicine, and
Institute of Endemic Diseases, Seoul National University Medical Research Center, Seoul 110-799, Korea

Abstract: A case of *Diphyllobothrium latum* infection in a 49-year old man is described, and diphyllobothriasis latum in the Republic of Korea is briefly reviewed. An incomplete strobila of a tapeworm, 95 cm in length, without scolex and neck, was spontaneously discharged in the feces of a patient. On the basis of morphologic characteristics of the worm and eggs, the worm was identified as *D. latum*. The patient was successfully treated with a single dose (15 mg/kg) of praziquantel. The most probable source of infection was salmon flesh according to the past history of the patient. The first case of *D. latum* infection was documented in 1971, and this is the 43rd recorded case in the Republic of Korea. The 43 cases were briefly reviewed. The patients' main complaints were gastrointestinal troubles, such as mild abdominal pain, indigestion, and diarrhea, and discharge of tapeworm segments in the feces. The suspected infection sources included raw or improperly cooked flesh of fresh or brackish water fish, including the perch, mullet, salmon, and trout.

Key words: *Diphyllobothrium latum*, salmon, praziquantel, case report, review

INTRODUCTION

Diphyllobothrium latum is an intestinal tapeworm of mammals, such as humans, dogs, cats, foxes, and other wild canines (Beaver et al., 1984). In the Republic of Korea, the first report of *D. latum* infection was documented based on recovery of eggs in the feces of 2 residents in Jinju, a southern area of Korea (Kojima and Ko, 1919). After then, 18 egg positive cases were reported by other workers (Hara and Himeno, 1923). An adult tapeworm was collected for

the first time from a human in 1971 and morphologically identified as *D. latum* (Cho et al., 1971). Until present, a total of 42 cases have been documented. The recent advancement of life quality with improvement of dietary conditions in the Republic of Korea, in particular, increased consumption of raw fish, is presumed to be a factor for an increase in *D. latum* infections. We report here a case of *D. latum* infection, and a total of 43 documented cases reported after 1971 were briefly reviewed.

CASE RECORD

A 49-year-old man visited our hospital with a seg-

• Received 31 May 2007, accepted after revision 12 July 2007.

*Corresponding author (e-mail: chamos@hanmail.net)

ment of a tapeworm, naturally discharged in his feces. He was a resident of Seoul, without any recent history of travel abroad or to coastal areas. He reported an otherwise non-specific history except for consumption of raw salmon in autumn of 2005 at a restaurant in Seoul. He was a construction worker, with height of 157 cm and weight of 52 kg. He didn't have any special medical history.

He reported lower abdominal pain and diarrhea from February 2006, and from March of the same year, he experienced a total of 4 episodes of fecal discharge of several segments of a tapeworm, 1 to 5 m in length. CBC was in normal range without signs of anemia (WBC: 5,900/ μ l, Hb: 15.8 g/dl, Hct: 45.9%, MCV: 87.9 fL, MCH: 29.6 pg, PLT: 327,000/ μ l). Blood chemistry and serology were all within normal ranges.

The specimen was brought to the Department of Parasitology and Tropical Medicine, Seoul National University College of Medicine, Seoul, Korea, and was identified as *D. latum* according to the characteristic morphology of the worm and the eggs. The worm was creamy-white and 95 cm long without scolex and neck. Some proglottids were fixed with 10% formalin under a pressure of a glass slide. The size of a proglottid was 8.2 x 2.7 mm, and the number of proglottids was 330. Gravid proglottids stained with acetocarmine revealed a rosette-shape uterus with 4-5 times piled-up uterine loops (Fig. 1). The eggs collected from the proglottids were oval with an operculum at the anterior end and an abopercular protuberance at the posterior end, grayish brown, and 63.5 μ m in average length and 42.5 μ m in average width. The patient was treated with a single dose (15 mg/kg) of praziquantel, and there was no evidence of relapse during the next 9 mo.

DISCUSSION

Since 1971 when the first worm-proven *D. latum* case was reported in the Republic of Korea (Cho et al., 1971), the total number of cases documented so far is 43, including the present case (Table 1). All cases of *D. latum* and *D. latum parvum* type infections (Lee et al.,

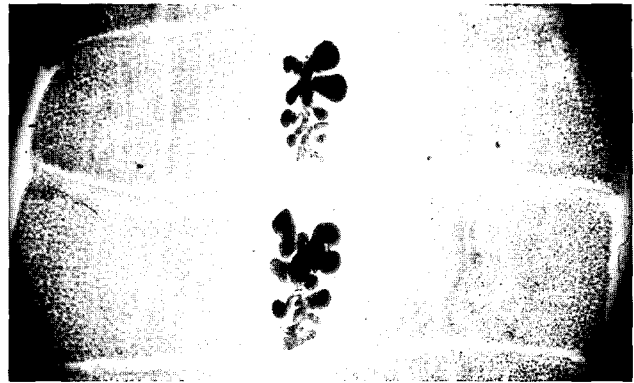


Fig. 1. Gravid proglottids of *D. latum* discharged from the present patient, acetocarmine-stained. Note 4-5 uterine loops in rosette form. $\times 40$.

1994) were included, but a case of *D. yonagoense* infection has been excluded from this study (Lee et al., 1988). The adult worm of *D. latum* was not collected in the case numbers 36, 38, and 42 (Table 1); therefore, the number of worm-proven *D. latum* cases in the Republic of Korea becomes 40. We briefly reviewed the 43 cases in terms of epidemiological, clinical, and parasitological aspects.

The age and sex distribution of *D. latum* infection revealed a predominance of infection among middle-aged men, i.e., 30-49 years (Table 2), which agrees to Sohn et al. (1996). The number of males was 31 and that of females 12 (Table 2). In general, Korean men tend to eat raw fish more frequently than women, and this tendency seems to be responsible for the higher number of *D. latum* cases in men. With regard to the residence of the cases, the majority of the 43 patients were citizens of Seoul or metropolitan Seoul (Bucheon), and the others were citizens of or visitors to coastal or lakeside cities like Chuncheon, Ullungdo (Island), Sokcho, and Busan (Table 3).

The major symptoms complained by *D. latum* cases were gastrointestinal troubles, such as abdominal pain, vomiting, diarrhea, and dyspepsia in 20 cases (Table 1). Other symptoms included anemia, fatigue, anorexia, fever, and myalgia in a few cases. In a total of 17 cases, there were natural discharge of proglottids in the feces, and in 4 cases no symptoms were complained (Table 1). Except a child reported by Joo et al. (1983), there were no other cases that showed

Table 1. Summary of 43 *D. latum* cases reported in the Republic of Korea (1971-2007)

Case No	Author (year)	Age (Sex)	Residence/visit	Complaints	Suspected source of infection	Size of eggs (μm)	Length of strobila (cm)	Collection of scolex	Drug (dosage)
1	Cho et al. (1971)	50(M)	Seoul	Passage of proglottids	Raw fishes	66.5 × 41.2	198	No	Atabrine (0.9 g)
2	Min et al. (1975)	37(M)	Seoul	Passage of proglottids	Unknown	N.m. ^{a)}	N.m.	No	Niclosamide (2.0 g)
3	Jeong et al. (1980)	14(M)	Seoul	Fatigue, anorexia	Perch	64.3 × 41.4	685	No	Bithionol (40 mg/kg)
4	Kim and Lee (1981)	26(F)	Seoul	Dizziness, dyspnea	Sea fish	63.8 × 43.6	40	No	Niclosamide (2.0 g)
5	Kim and Lee (1982)	42(M)	Seoul	Abd. pain	Sea fishes	N.m.	635	Yes	Bithionol (3.0 g)
6	Song and Jung (1983)	48(M)	Busan	Abd. pain	Perch	N.m.	N.m.	-	Niclosamide (3.0 g)
7	Lee et al. (1983)	10(M)	Seoul	Abd. pain	Perch	64 × 45	454	Yes	Bithionol (40 mg/kg)
8		48(M)	Seoul	Passage of proglottids	Sea fish	62 × 42	30	No	Niclosamide (2.0 g)
9		64(M)	Seoul	No symptoms	Sea fish	67 × 48	320	Yes	Bithionol (40 mg/kg)
10		53(F)	Seoul	Abd. pain, vomiting	Sea fish	59 × 41	680	Yes	Praziquantel (20 mg/kg)
11		23(M)	Seoul	Abd. pain, indigestion	Perch, mullet	67 × 45	565	Yes	Praziquantel (15 mg/kg)
12	Joo et al. (1983)	17(M)	Seoul	Passage of proglottids	Salmon	N.m.	1250	No	Bithionol (40 mg/kg)
13		17(M)	Seoul	Passage of proglottids	Sea fishes	N.m.	854	No	Bithionol (40 mg/kg)
14		6(F)	Seoul	Anemia	Sea fishes	N.m.	45-50	Yes	Bithionol (40 mg/kg)
15		35(M)	Seoul	Diarrhea	Perch, salmon	N.m.	830, 850	Yes	Bithionol (40 mg/kg)
16		14(M)	Seoul	Passage of proglottids	Sea fishes	N.m.	620	No	Bithionol (40 mg/kg)
17		17(F)	Seoul	Passage of proglottids	Salmon	N.m.	1050	Yes	Bithionol (40 mg/kg)
18		10(M)	Seoul	Passage of proglottids	Unknown	N.m.	460	No	Bithionol (40 mg/kg)
19	Cho et al. (1986)	29(M)	Seoul	Abd. pain	Sea fish	64 × 44	92	No	Unknown
20		41(M)	Seoul	Diarrhea, constipation	Salmon	62 × 43	> 20	No	Unknown
21	Lee et al. (1987)	14(M)	Seoul	No symptoms	Mullet, salmon, perch	62 × 46	650	Yes	Praziquantel (13 mg/kg)
22		31(M)	Seoul	Abd. pain, diarrhea	Perch, mullet	61 × 42	300	Yes	Praziquantel (13.6 mg/kg)
23	Lee et al. (1989)	20(M)	Ullungdo	Fever, passage of proglottids	Sea fish	63.0 × 44.0	152, 123, 100	Yes (n=2)	Praziquantel (10 mg/kg)
24		30(M)	Ullungdo	Passage of proglottids	Sea fish	63.0 × 44.0	240	No	Praziquantel (10 mg/kg)
25		36(M)	Seoul	No symptoms	Fishes	63.0 × 44.0	265, 423	No	Praziquantel (10 mg/kg)
26		44(M)	Seoul	Passage of proglottids	Sea foods	63.0 × 44.0	119, 114, 85	Yes (n=3)	Praziquantel (10 mg/kg)
27		41(M)	Seoul	Passage of proglottids	Sea fish	63.0 × 44.0	N.m.	Yes	Praziquantel (10 mg/kg)
28		25(M)	Seoul	Passage of proglottids	Sea fish	63.0 × 44.0	100	Yes	Praziquantel (600 mg)
29		31(M)	Seoul	Abd. pain, dyspepsia	Sea fish	63.0 × 44.0	N.m.	No	Praziquantel (10 mg/kg)
30	Lee et al. (1994) ^{b)}	46(F)	Seoul	No symptoms	Trout	57.5 × 37.4	120	Yes	Praziquantel (13 mg/kg)
31		22(M)	Seoul	Passage of proglottids	Sea fish	N.m.	15	No	Praziquantel (10 mg/kg)
32	Ahn et al. (1996)	43(M)	Chuncheon	Passage of proglottids	Trout	62.4 × 41.5	665	No	Praziquantel (15 mg/kg)
33		39(F)	Chuncheon	Dyspepsia, abd. pain	Trout	N.m.	550	No	Praziquantel (15 mg/kg)
34	Ha et al. (1997)	60(F)	Unknown	Abd. pain	Trout (cultured)	55-70 × 45-60	50	No	Praziquantel (10 mg/kg)
35	Chung et al. (1997)	35(F)	Bucheon	Abd. pain	Mullet	72.4 × 47.2	310	Yes	Praziquantel (15 mg/kg)
36		39(M)	Bucheon	Abd. pain	Mullet	67 × 45	-	No	Praziquantel (15 mg/kg)
37		43(F)	Bucheon	Dizziness, abd. pain	Mullet	70.4 × 46.4	340	Yes	Praziquantel (15 mg/kg)
38		43(F)	Bucheon	Headache, abd. pain	Mullet	N.m.	-	No	Praziquantel (15 mg/kg)
39		42(M)	Bucheon	Abd. pain	Mullet	N.m.	100	No	Praziquantel (15 mg/kg)
40	Jang and Cho (2000)	42(M)	Chuncheon	Abd. pain	Trout	N.m.	300	Yes	Praziquantel (10 mg/kg)
41	Lee et al. (2001)	7(F)	Sokcho	Passage of proglottids	Salmon	N.m.	42	-	Praziquantel (15 mg/kg)
42		35(F)	Sokcho	Passage of proglottids	Salmon	N.m.	-	No	Praziquantel (600 mg)
43	The present study (2007)	49(M)	Seoul	Abd. pain, diarrhea	Salmon	63.5 × 42.5	95	No	Praziquantel (15 mg/kg)

^{a)}Not measured.^{b)}The worms were identified as *D. latum* parvum type.

Table 2. Age and sex distribution of *D. latum* cases reported in the Republic of Korea (1971-2007)

Age	No. of cases		
	Male	Female	Total (%)
< 9	0	2	2 (4.7)
10 ~ 19	7	1	8 (18.6)
20 ~ 29	5	1	6 (13.9)
30 ~ 39	7	3	10 (23.2)
40 ~ 49	10	3	13 (30.2)
50 ~ 59	1	1	2 (4.7)
60 ~ 69	1	1	2 (4.7)
Total	31 (72.1)	12 (27.9)	43 (100.0)

Table 3. Residence distribution of *D. latum* cases (1971-2007)

Residence/place of visit	No. of cases (%)
Seoul	29 (67.4)
Bucheon	5 (11.6)
Chuncheon	3 (7.0)
Ullungdo	2 (4.7)
Sokcho	2 (4.7)
Busan	1 (2.3)
Unknown	1 (2.3)
Total	43 (100.0)

significant signs and symptoms of anemia.

Adult worms were identified in 40 of the 43 cases, and from the 40 cases a total of 46 worms were collected; 2 cases were infected with 3 worms each, 2 cases were with 2 worms, and 36 cases were with a single worm (Table 1). Among the 46 worms recovered, 21 were with scolices. The longest worm was 1,250 μ m, and 13 worms were longer than 500 μ m (Table 1). For *D. latum*, the largest size of the eggs was 72.4 x 47.2 μ m, and the smallest size 59.0 x 41.0 μ m. The eggs of the 30th and 31st cases, identified as *D. latum parvum* type infections, were 57.5 x 37.4 μ m.

The medication was atabrine in 1971, and since then until 1986, either niclosamide, bithionol, or praziquantel was used. From 1987 up to present, praziquantel has been used as the drug of choice. There was no treatment failure among the 43 cases. In our case, the treatment with praziquantel in a single dose (15 mg/kg) was successful as revealed by the disappear-

Table 4. Suspected sources of infection in *D. latum* infection cases (1971-2007)

Source of infection	No. (%) of cases
Fish (undefined)	18 (37.5)
Salmon	8 (16.6)
Mullet	8 (16.6)
Perch	7 (14.6)
Trout	5 (10.4)
Unknown	2 (4.2)
Total	48 (100.0) ^{a)}

^{a)}Five cases recalled that they had consumed more than 1 kind of fishes.

ance of eggs in the feces at 9 mo after the treatment.

As to the second intermediate hosts for *D. latum*, freshwater fishes, such as pikes, burbot, trouts, salmon, and perch were listed (Beaver et al., 1984). In Japan, Eguchi (1973) listed 4 salmon species as the major second intermediate hosts for *D. latum*, i.e., *Onchorhynchus masou* (masu salmon), *O. gorbusha* (pink salmon), *O. keta*, and *O. nerka*. However, the species of the broad fish tapeworm, i.e., *D. latum*, transmitted by salmonid fish was put to question, and the one in Japan by *O. masou* and *O. gorbusha* was assigned as a new species *D. nihonkaiense* (Yamane et al., 1986), and another in Siberia transmitted by 2 salmonid fish species, *O. gorbusha* and *O. keta*, was assigned as *D. klebanovskii* (Muratov and Posokhov, 1988). The Republic of Korea and Japan share the sea and fish. Therefore, human-infecting *Diphyllobothrium* spp. may be taxonomically similar. In particular, the worms from cases who consumed salmonid fish among the Korean patients may have been *D. nihonkaiense*. However, the validity of *D. nihonkaiense* and *D. klebanovskii* remains to be further clarified, and we regarded all worms as *D. latum* in order to avoid taxonomic confusion.

With the exception of 2 cases in which the suspected source of infection is uncertain, all cases had the history of eating raw freshwater or brackish water fish (Table 4). The number of cases that ate salmon and mullet was equally 8 (16.6%), and those that consumed perch and trout were 7 (14.6%) and 5 (10.4%), respectively (Table 4). Most of the remaining cases

recalled that they had eaten any type of raw fish. Before the 1990s, perch was most frequently reported as the suspected second intermediate host in the Republic of Korea (Lee et al., 1983, 1989), but nowadays, salmon, trout, and mullet are mainly concerned (Table 1). It is regretted that there have been no reports on *D. latum* plerocercoid infections in fishes; studies on the life cycle of *D. latum* are required in the Republic of Korea.

REFERENCES

- Ahn YK, Ryang YS, Lee KJ, Chung PR (1996) Two human cases of *Diphyllobothrium latum* infection through eating raw fresh water trout, *Salmo gairdneri*. *Korean J Biomed Lab Sci* **2**: 283-288.
- Beaver PC, Jung RC, Cupp EW (1984) *Clinical Parasitology*. 9th ed. pp 544-547, Lea & Febiger, Philadelphia, USA.
- Chai JY, Murrell KD, Lymbery AJ (2005) Fish-borne parasitic zoonoses: status and issues. *Int J Parasitol* **35**: 1233-1254.
- Cho SY, Kang SY, Kim SI, Im IS (1986) Two cases of human infection of *Diphyllobothrium latum*. *Korean J Parasitol* **24**: 239 (abstract in Korean).
- Cho SY, Seo BS, Ahn JH (1971) One case report of *Diphyllobothrium latum* infection in Korea. *Seoul J Med* **12**: 157-163.
- Chung PR, Sohn WM, Jung Y, Pai SH, Nam MS (1997) Five human cases of *Diphyllobothrium latum* infection through eating raw flesh of redlip mullet, *Liza haematocheila*. *Korean J Parasitol* **35**: 283-289.
- Eguchi S (1973) *Diphyllobothrium latum*. *Prog Med Parasitol in Japan* **5**: 129-144.
- Ha JY, Yu BY, Yu JR (1997) A case of *Diphyllobothrium latum* infection. *J Korean Acad Fam Med* **18**: 866-870.
- Jang MK, Cho YK (2000) A case of *Diphyllobothrium latum* infection. *Korean J Int Med* **58**: 599 (abstract in Korean).
- Jeong KH, Lee JS, Rim HJ (1980) A case report of *Diphyllobothrium latum* infection. *J Soonchunhyang Univ* **3**: 155-160.
- Joo KH, Eom KS, Chung MS, Yeo HW, Chung KH, Lee JH, Rim HJ (1983) Case report: 7 cases of *Diphyllobothrium latum* infection. *Korean J Parasitol* **21**: 307 (abstract in Korean).
- Kim JJ, Lee KT (1981) A case report of *Diphyllobothrium latum* infection in Korea. *Korean J Parasitol* **19**: 193 (abstract in Korean).
- Kim JJ, Lee KT (1982) A case report of *Diphyllobothrium latum* infection in Korea. *Korean J Parasitol* **20**: 227 (abstract in Korean).
- Lee KW, Suhk HC, Pai KS, Shin HJ, Jung SY, Han ET, Chai JY (2001) *Diphyllobothrium latum* infection after eating domestic salmon flesh. *Korean J Parasitol* **39**: 319-321.
- Lee SH, Chai JY, Hong ST, Sohn WM, Choi DI (1988) A case of *Diphyllobothrium yonagoense* infection. *Seoul J Med* **29**: 391-395.
- Lee SH, Chai JY, Hong ST, Sohn WM, Huh S, Cheong EH, Kang SB (1989) Seven cases of *Diphyllobothrium latum* infection. *Korean J Parasitol* **27**: 213-216.
- Lee SH, Chai JY, Seo M, Kook J, Huh S, Ryang YS, Ahn YK (1994) Two rare cases of *Diphyllobothrium latum parvum* type infection in Korea. *Korean J Parasitol* **32**: 117-120.
- Lee SH, Seo BS, Chai JY, Hong ST, Hong SJ, Cho SY (1983) Five cases of *Diphyllobothrium latum* infection. *Korean J Parasitol* **21**: 150-156.
- Lee SK, Chung NS, Paik IK, Ko IH (1987) Two cases of *Diphyllobothrium latum* infection and analysis of diphyllobothriasis in Korea. *Korean J Medical Technologists* **19**: 239-24.
- Min DY, Im KI, Cho KM (1975) One case of diphyllobothriasis. *Korean J Parasitol* **13**: 184 (abstract in Korean).
- Min DY (1990) Cestode infections in Korea. *Korean J Parasitol* **28**(Suppl): 123-144.
- Muratov IV, Posokhov PS (1988) Causative agent of human diphyllobothriasis – *Diphyllobothrium klebanovskii* sp. n. *Parazitologia* **22**: 165-170 (in Russian).
- Sohn WM, Chai JY, Lee SH (1996) Epidemiologic studies on diphyllobothriid tapeworms in Korea. *Proceedings of 2nd Japan-Korea Parasitologists' Seminar (Forum Cheju-2)* **2**: 66-73.
- Song SB, Jung TS (1983) A case report of *Diphyllobothrium latum* infection in Korea. *Korean J Parasitol* **21**: 131 (abstract in Korean).
- Wardle RA, Mcleod JA (1952) *The Zoology of Tapeworms (Order Pseudophyllidea)*. pp 559-652, University of Minnesota Press, Minneapolis, USA.
- Yamane Y, Kamo H, Bylund G, Wikgren BJP (1986) *Diphyllobothrium nihonkaiense* sp. nov. (Cestoda: Diphyllobothriidae) – revised identification of Japanese broad tapeworm. *Shimane J Med Sci* **10**: 29-48.
- Yokogawa M, Niimura M, Kobayashi M, Hata H, Tazaki T, Tokita K, Kojima S (1979) Epidemiological survey for diphyllobothriasis latum in Chiba prefecture and treatment with bithionol. *Jap J Parasitol* **28**: 133-138.