

Clinical Article

Tae-One Lee, M.D.¹Dae-Jean Jo, M.D.²Sung-Min Kim, M.D.²

Department of Neurosurgery¹
Hallym University College of
Medicine, Seoul, Korea

Department of Neurosurgery²
East-West Neo Medical Center
Kyunghee University, Seoul, Korea

Outcome and Efficacy of Height Gain and Sagittal Alignment after Kyphoplasty of Osteoporotic Vertebral Compression Fractures

Objective : Although a significant correction of local kyphosis has been reported previously, only a few studies have investigated whether this correction leads to an improved overall sagittal alignment. The study objective was to determine whether an improvement in the local kyphotic angle improves the overall sagittal alignment. We examined and compared the effects of thoracic and lumbar level kyphoplasty procedures on local versus overall sagittal alignment of the spine.

Methods : Thirty-eight patients with osteoporotic vertebral compression fractures who showed poor response to conventional, palliative medical therapy underwent single-level kyphoplasty. The pertinent clinical data of these patients, from June 2006 to November 2006, were reviewed retrospectively. We measured preoperative and postoperative vertebral body heights, which were classified as anterior, middle, or posterior fractured vertebral body heights. Furthermore, the local and overall sagittal angles after polymethylmethacrylate deposition were measured.

Results : More height was gained at the thoracic level, and the middle vertebral height regained the most. A significant local kyphosis correction was observed at the fractured level, and the correction at larger spanning segments decreased with the distance from the fractured level.

Conclusion : The inflatable balloon kyphoplasty procedure was the most effective in regaining the height of the thoracic fractured vertebra in the middle vertebral body. The kyphosis correction by kyphoplasty was mainly achieved in the fractured vertebral body. Sagittal angular correction decreased with an increase in the distance from the fractured vertebra. No significant improvement was observed in the overall sagittal alignment after kyphoplasty. Further studies in a larger population are required to clarify this issue.

KEY WORDS : Kyphoplasty · Vertebral compression fracture · Sagittal alignment.

INTRODUCTION

Vertebroplasty, which is augmentation of vertebral compression fractures (VCFs) by a percutaneous injection of polymethylmethacrylate (PMMA), was first described by Galibert et al. in 1987 for treatment of C2 hemangioma¹². Numerous reports have demonstrated that patients who underwent vertebroplasty experienced statistically significant pain relief and restoration of daily activities^{1,10,19,27}. However, vertebroplasty does not inflate the collapsed vertebral body. In the osteoporotic spine, a kyphotic deformity alters the biomechanical environment and may favor additional fractures^{2,27}. Furthermore, vertebroplasty requires cement injection at higher pressures and has a higher risk of cement extravasation compared to kyphoplasty^{20,22,26,29}. This led to the development of kyphoplasty, which combines vertebroplasty with balloon angioplasty¹⁸. By using a transpedicular or extrapedicular route, a cannula is introduced into the vertebral body, followed by the insertion of an inflatable balloon tamp, which directly reduces the fracture and restores the vertebral body height prior to the injection of cement. Initial studies have shown good clinical results, along with the restoration of the vertebral body height^{9,17,21,24}. Height restoration and decrease in cement leakage are also debated as important points that differentiate kyphoplasty from vertebroplasty^{13,22,30}. Significant vertebral height gain and reduction in local kyphosis (angular correction at the fractured vertebra) have been reported previously.

The objective of this study was to determine whether an improvement in the local kyphotic angle would lead to an improvement in the overall sagittal alignment.

- Received : May 17, 2007
- Accepted : September 7, 2007
- Address for reprints :
Sung-Min Kim, M.D.
Department of Neurosurgery
East-West Neo Medical Center
Kyunghee University
149 Sangil-dong, Gangdong-gu
Seoul 134-837, Korea
Tel : +82-2-440-6144
Fax : +82-2-440-7494
E-mail : spinekim@khu.ac.kr

MATERIALS AND METHODS

In this retrospective analysis from June 2006 to November 2006, we reviewed the hospital medical records of 38 consecutive patients who underwent the kyphoplasty procedure for acute to subacute symptomatic single-level osteoporotic vertebral wedge compression fractures.

All patients had persistent back pain for at least 2 weeks, resulting from an osteoporotic VCF that was not responsive to nonsurgical treatment, including bed rest, analgesic medication, and bracing when tolerated. The fracture was confirmed as the likely pain generator by correlating physical findings with the identification of edema in the fractured vertebra on T2 fat suppression images obtained by magnetic resonance imaging (MRI).

Of these, thirty patients were females and 8 were males. The mean age was 72 years, with a range from 55 to 82. Thirty-six patients had fractures with less than two-third loss of original height, while the remaining 2 patients had fractures with approximately 80% loss of original height. The number of patients with lumbar and thoracic fractures was 21 and 17, respectively. The onset of fracture ranged from 2 to 11 weeks.

Preoperative and postoperative radiographs were obtained and analyzed to quantify height gain and local and overall

spinal sagittal alignment correction. Standard anterior-posterior (AP) and lateral radiographs centered on the fractured vertebral level were obtained from all patients. Based on these radiographs, one surgeon (a spine surgeon) measured the anterior, middle, and posterior fractured vertebral body heights (Fig. 2). Local kyphotic angles were measured at the superior and inferior endplates of the fractured vertebra. Furthermore, we measured angles of spanning the fractured level by 1, 2, 3 above and below the fractured vertebra (Fig. 3). Statistical analyses were performed

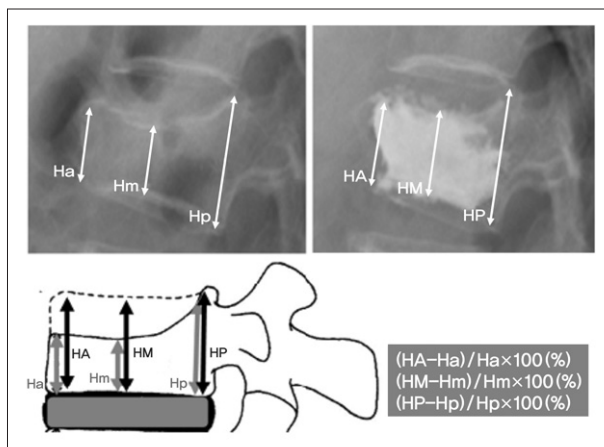


Fig. 2. Preoperative and postoperative radiographs obtained to quantify the percentage height gain (anterior, middle, and posterior fractured vertebral body heights). (Ha, Hm, Hp : preoperative anterior, middle, and posterior vertebral height, respectively HA, HM, HP : postoperative anterior, middle, and posterior vertebral height, respectively).

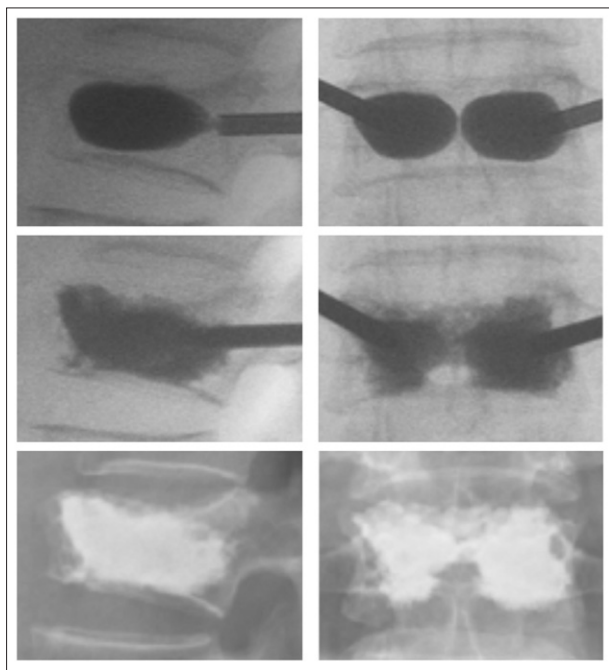


Fig. 1. Bilateral transpedicular access to the fractured vertebral body is obtained. The balloon tamps are then inserted through the cannulas and placed inside the anterior two-thirds of the vertebral body on the lateral view, covering both sides to the midline on the anterior-posterior view. The inflation is stopped when the pressure reaches 250 psi or when the balloon makes a contact with the fractured endplate. Ideally, the cement connects across the midline on the anterior-posterior projection.

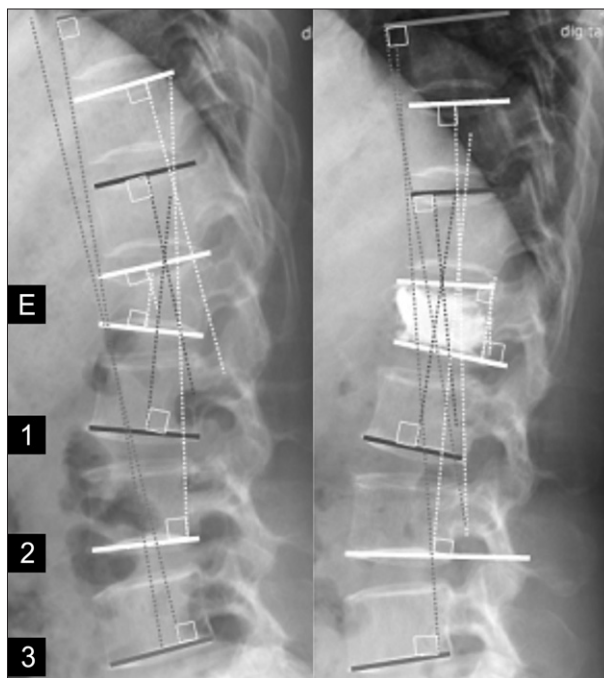


Fig. 3. Local kyphotic angles (E) are measured at the superior and inferior endplates of the fractured vertebra, spanning the fractured level by 1, 2, and 3 vertebrae.

for results obtained for thoracic and lumbar fractures by using Student's *t* test and Mann-Whitney *U* test.

Surgical procedure

After a simple postural reduction procedure with a soft pillow in the supine position¹⁶, we performed the balloon kyphoplasty procedure on a radiolucent Jackson table, with the spine extended by chest and pelvic bolsters. The patients were then placed prone under monitored anesthesia care.

By using fluoroscopic guidance, bilateral transpedicular or parapedicular access to the fractured vertebral body was obtained sequentially with trocars, guidewires, and cannulas. The balloon tamps were then inserted through the cannulas and placed inside the anterior two-thirds of the vertebral body on the lateral view, covering both sides to the midline on the anterior-posterior view. Ideally, the cement is to be connected across the midline on the anterior-posterior projection. The inflation was performed in an alternate fashion between the both sides, with regular fluoroscopic imaging. We stopped the inflation when the pressure reached 250 psi or when the balloon made a contact with the fractured endplate. The volume of cement injected is usually equal to or less than the inflation volume of the balloon tamps (Fig. 1). The mean injected cement volume was 4.4 ml, with a range from 2.0 to 7.5 ml (thoracic : 3.4 ml, lumbar : 5.2 ml).

RESULTS

The middle vertebral height showed an average increase by 39% of the preoperative height. The anterior and posterior height gains were 18% and 4%, respectively. The inflatable balloon tamp kyphoplasty procedure was the most effective in regaining the height of the fractured vertebra in the middle vertebral body (Table 1).

The average angular correction was obtained at the fractured level and at spinal segments spanned by 1, 2, and 3 levels above and below the fractured level. We observed a significant local kyphosis correction of 7.9° at the fractured level the correction at larger spanning segments decreased with the distance from the fractured level. It reduced to 3.1° at 1 level, 2.8° at 2 levels, and 1.1° at 3 levels above and below the fractured level (Table 2).

We assigned the patients to thoracic and lumbar spinal fractured groups to determine whether any difference exists in correction of the angle, height, and overall sagittal alignment. The average angular correction of the thoracic spine was 8.6° as compared to 6.9°

of the lumbar spine. This average angular correction at 1, 2 and 3 levels above and below the fractured level reduced to 4.2°, 3.1° and 1.3° in the thoracic spine and 2.8°, 2.4° and 0.9° in the lumbar spine, respectively (Table 3). More height was gained at the thoracic level, while the middle vertebral height regained the most. The sagittal angular correction decreased with an increase in the distance from the fractured vertebra.

No cement extravasation into the spinal canal or the neural foramen occurred during the kyphoplasty procedure in any of patients. Furthermore, there were no cement embolization or adverse clinical effects. However, minimal extravasation into the disc space and the paravertebral soft tissue occurred in 4 of 38 patients.

DISCUSSION

Treatment options for painful VCFs include nonsurgical approaches such as analgesic medication, bed rest, and back braces. However, these treatment approaches do not address spinal deformity, and the pain and disability may be prolonged during the healing of fractured vertebral body²⁵. Vertebroplasty that involves the percutaneous injection of cement directly into the fractured vertebral body has been reported to be effective in improving pain associated with VCFs^{4,5,7,8,15}. The limitations of vertebroplasty include the inability of this procedure to address the kyphotic deformity and the substantial risk of extravertebral cement leakage

Table 1. Average height restoration (%) (n=38)

	Preoperative	Postoperative	Restoration (%)
Average Ha, A (mm)	19.4	23.0	18%
Average Hm, M (mm)	16.8	23.4	39%
Average Hp, P (mm)	26.7	27.8	4%

Table 2. Average angular restoration (n=38)

Level	Angle	p value
Fractured level	7.9° (5 – 12.9°)	< 0.01
Spanning 1 level	3.1°	< 0.01
Spanning 2 level	2.8°	< 0.01
Spanning 3 level	1.1°	< 0.01

Table 3. Height and angular restoration in the thoracic versus lumbar spine (n=38)

		Thoracic (n=17)	Lumbar (n=21)	p value
Height Restoration (%)	Average ABH	25%	13%	< 0.01
	Average MBH	44%	33%	< 0.01
	Average PBH	6%	3%	< 0.01
Angular Restoration (°)	Fractured level	8.6°	6.9°	< 0.01
	Spanning 1 level	4.2°	2.8°	< 0.01
	Spanning 2 level	3.1°	2.4°	< 0.05
	Spanning 3 level	1.3°	0.9°	< 0.05

Statistics : Mann-Whitney *U* test

that results from the high-pressure cement injection required by this technique. In contrast, the kyphoplasty procedure attempts to restore spinal alignment and permits the injection of cement under low pressure into the cavity created in the vertebral body through the expansion of inflatable balloon tamps. The results of the present study indicate that kyphoplasty is an effective procedure for improving kyphotic deformity in a majority of patients despite no significant improvement observed in the overall sagittal alignment. A low risk of complications was observed furthermore, no complications related to the devices used or the injected cement were noted. The degrees of height and angular correction obtained in this study were similar with the previously reported results. Height restorations of 0% to 90% (percentage of normal adjacent vertebral height) and angular corrections of 0° to 18° have been reported^{9,13,18,26,30}.

The degree of reduction in adjacent segmental alignment (overall sagittal alignment) depends on multiple variables, including the mechanical quality of bone (density), nature of fracture (communion), mechanical quality of the disc, size of the disc (tall vs. bone-on-bone), number and size of balloon tamps, placement of balloon tamp (s), age of fracture, etc. Soft osteoporotic bone in the adjacent vertebrae cannot be easily pushed back to correct the overall alignment because the low modulus of elasticity may cause the vertebra itself to deform. In fact, this effect may impose a risk of adjacent VCF, particularly with aggressive kyphoplasty wherein a large amount of cement is injected. Similar findings have been reported in previous studies^{3,11,14}.

Kyphoplasty may have an advantage over vertebroplasty in this regard because the balloon tamp tends to create a void inside the vertebral body that is sealed by the compacted bone. Similar to the bone, the mechanical quality of the disc is also an important parameter. Softer discs are less likely to transmit corrective forces. The quantity (height) of the disc may also play a role. The smaller thoracic discs tend to transmit more corrective forces²³. The age of the VCF is an important factor because a healed fracture is difficult to be reduced⁶.

In the present study, most osteoporotic VCFs were wedge-shaped, and the upper endplates were fractured. In this regard, the balloon tamps were ellipsoidal in shape, and their placement provided the highest elevation of the upper endplates in the middle portion of the fractured level.

A statistically significant trend of higher angular and height correction was observed in the thoracic spine than in the lumbar spine. This effect depends on the smaller endplates and narrower disc spaces in the thoracic spine. The presence of the rib cage makes the thoracic spine stiffer than the lumbar spine this is also likely to contribute to a higher

correction of sagittal spinal curvature with kyphoplasty, as reported by Pradhan et al.²³. Since the balloon tamp has a relatively low mechanical advantage in reducing the overall sagittal alignment of the spine, we believe that aggressive balloon inflation and cement injection are not good for osteoporotic VCFs.

CONCLUSION

Kyphoplasty is a minimal invasive technique to restore height and to achieve significant correction of angular deformity at the fractured level. More height was gained at the thoracic level, while the middle vertebral height regained the most. The sagittal angular correction decreased as the distance from the fractured vertebra increased. Furthermore, there was no significant improvement in the overall sagittal alignment. Further studies in a larger population are required to clarify this issue.

References

1. Barr JD, Barr MS, Lemley TJ, McCann RM : Percutaneous vertebroplasty for pain relief and spinal stabilization. *Spine* 25 : 923-928, 2000
2. Belmont PJ Jr, Polly DW Jr, Cunningham BW, Klemme WR : The effect of hook pattern and kyphotic angulation on mechanical strength and apical rod strain in a long-segment posterior construct using a synthetic model. *Spine* 26 : 627-635, 2001
3. Berlemann U, Ferguson SJ, Nolte LP, Heini PF : Adjacent vertebral failure after vertebroplasty. A biomechanical investigation. *J Bone Joint Surg Br* 84 : 748-752, 2002
4. Chiras J, Depriester C, Weill A, Sola-Martinez MT : Deramond H Percutaneous vertebral surgery. Technique and indications. *J Neuroradiol* 24 : 45-59, 1997
5. Cortet B, Cotten A, Boutry N, Flipo RM, Duquesnoy B, Chastanet P, et al : Percutaneous vertebroplasty in the treatment of osteoporotic vertebral compression fractures : an open prospective study. *J Rheumatol* 26 : 2222-2228, 1999
6. Crandall D, Slaughter D, Hankins PJ, Moore C, Jerman J : Acute versus chronic vertebral compression fractures treated with kyphoplasty : Early results. *Spine J* 4 : 418-424, 2004
7. Cyteval C, Sarrahere MP, Roux JO, Thomas E, Jorgensen C, Blotman F, et al : Acute osteoporotic vertebral collapse : open study on percutaneous injection of acrylic surgical cement in 20 patients. *AJR Am J Roentgenol* 173 : 1685-1690, 1999
8. Deramond H, Depriester C, Galibert P, Le Gars D : Percutaneous vertebroplasty with polymethylmethacrylate. Technique, indications, and results. *Radiol Clin North Am* 36 : 533-546, 1998
9. Dudeney S, Liberman IH, Reinhardt MK, Hussein M : Kyphoplasty in the treatment of osteolytic vertebral compression fractures as a result of multiple myeloma. *J Clin Oncol* 20 : 2382-2387, 2002
10. Evans AJ, Jensen ME, Kip KE, DeNardo AJ, Lawler GJ, Negin GA, et al : Vertebral compression fractures : pain reduction and improvement in functional mobility after percutaneous polymethylmethacrylate vertebroplasty - retrospective report of 245 cases. *Radiology* 226 : 366-372, 2003
11. Fribourg D, Tang C, Sra P, Delamarter R, Bae H : Incidence of subsequent vertebral fracture after kyphoplasty. *Spine* 29 : 2270-2276, 2004
12. Galibert P, Deramond H : Percutaneous acrylic vertebroplasty as a treatment of vertebral angioma as well as painful and debilitating diseases. *Chirurgie* 116 : 326-334, 1990
13. Garfin SR, Yuan HA, Reiley MA : New technologies in spine : Kyphoplasty and vertebroplasty for the treatment of painful osteoporotic compression fractures. *Spine* 26 : 1511-1515, 2001

14. Harrop JS, Prpa B, Reinhardt MK, Lieberman IH : Primary and secondary osteoporosis incidence of subsequent vertebral compression fractures after kyphoplasty. *Spine* **29** : 2120-2125, 2004
15. Jensen ME, Evans AJ, Mathis JM, Kallmes DF, Cloft HJ, Dion JE : Percutaneous polymethylmethacrylate vertebroplasty in the treatment of osteoporotic vertebral body compression fractures : technical aspects. *AJNR Am J Neuroradiol* **18** : 1897-1904, 1997
16. Kim YS, Kim KW, Park HC, Chung SS, Lee KC : Postural reduction for the compression fracture of thoracolumbar spines. *J Korean Neurosurg Soc* **17** : 1421-1431, 1988
17. Ledlie JT, Renfro M : Balloon kyphoplasty : one-year outcomes in vertebral body height restoration, chronic pain, and activity levels. *J Neurosurg* **98 (Suppl)** : 36-42, 2003
18. Liberman IH, Dudeney S, Reinhardt MK, Bell G : Initial outcomes and efficacy of "kyphoplasty" in the treatment of painful osteoporotic vertebral compression fractures. *Spine* **26** : 1631-1638, 2001
19. Mathis JM, Barr JD, Belkoff SM, Barr MS, Jensen ME, Deramond H : Percutaneous vertebroplasty : a developing standard of care for vertebral compression fractures. *AJNR Am J Neuroradiol* **22** : 371-381, 2001
20. Mousavi P, Roth S, Finkelstein J, Cheung G, Whyne C : Volumetric quantification of cement leakage following percutaneous vertebroplasty in metastatic and osteoporotic vertebrae. *J Neurosurg* **99 (Suppl)** : 56-59, 2003
21. Phillips FM, Ho E, Campbell-Hupp M, McNally T, Todd Wetzel F, Gupta P : Early radiographic and clinical results of balloon kyphoplasty for the treatment of osteoporotic vertebral compression fractures. *Spine* **28** : 2260-2265, 2003
22. Phillips FM, Todd Wetzel F, Liberman IH : An in vivo comparison of the potential for extravertebral cement leak after vertebroplasty and kyphoplasty. *Spine* **27** : 2173-2178, 2002
23. Pradhan BB, Bae HW, Kropf MA, Patel VV, Delamarter RB : Kyphoplasty reduction of osteoporotic vertebral compression fractures : correction of local kyphosis versus overall sagittal alignment. *Spine* **31** : 435-441, 2006
24. Rhyne A 3rd, Banit D, Laxer E, Odum S, Nussman D : Kyphoplasty : report of eighty-two thoracolumbar osteoporotic vertebral fractures. *J Orthop Trauma* **18** : 294-299, 2004
25. Silverman SL : The clinical consequences of vertebral compression fracture. *Bone* **13 (Suppl)** : 27-31, 1992
26. Theodorou DJ, Theodorou SJ, Duncan TD, Garfin SR, Wong WH : Percutaneous balloon kyphoplasty for the correction of spinal deformity in painful vertebral body compression fractures. *Clin Imaging* **26** : 1-5, 2002
27. Watts NB, Harris ST, Genant HK : Treatment of painful osteoporotic vertebral fractures with percutaneous vertebroplasty or kyphoplasty. *Osteoporosis Int* **12** : 429-437, 2001
28. White AA 3rd, Panjabi MM, Thomas CL : The clinical biomechanics of kyphotic deformities. *Clin Orthop* **128** : 8-17, 1977
29. Wong W, Mathis J : Is intraosseous venography a significant safety measure in performance of vertebroplasty? *J Vasc Interv Radiol* **13** : 137-138, 2002
30. Wong W, Riley MA, Garfin S : Vertebroplasty/kyphoplasty. *J Womens Imaging* **2** : 117-124, 2000