

## Case Report

Jin-Wook Kim, M.D.

Ju-Ho Jeong, M.D.

# Fractures and Dislocations of the Cervicothoracic Junction

Cervicothoracic junction instability should be stabilized with the circumferential fusion. In addition, cervicothoracic junctional area should be examined carefully in acute traumatic injury not only to confirm hidden lesions but also to make the proper surgical plans. Here, three patients who underwent cervicothoracic arthrodesis at our institution are presented with a review of literature.

**KEY WORDS :** Cervicothoracic injury · Pedicle screw · Lateral mass screw · Anterior fusion.

## INTRODUCTION

Cervicothoracic junction is where the mobile lordotic cervical spine joins the rigid kyphotic thoracic spine. It is a complex, potentially unstable anatomic site with unique biomechanical properties. Acute traumatic fractures and dislocations of the cervicothoracic junction are rare and are often incorrectly diagnosed because of suboptimal imaging studies and severe injuries at other vital organs.

We reviewed three patients who had been injured at cervicothoracic junction from November 2004 to July 2006. The medical records and imaging study results were reviewed. Outcome measures, as previously documented<sup>3,4</sup>, were classified as follows : excellent, complete recovery and return to previous activities; good, occasional pain, return to gainful activities, and only intermittent use of analgesics; fair, partial recovery, frequent use of analgesics, and modified activities; poor, no relief of original symptoms, constant pain, and full-time support. Neurologic status at presentation and final follow-up was assessed using the Frankel classification. All three cases were involved in a road traffic accident. Neurologic status on presentation and at follow-up, treatment methods, and outcomes are summarized in Table 1.

## CASE REPORT

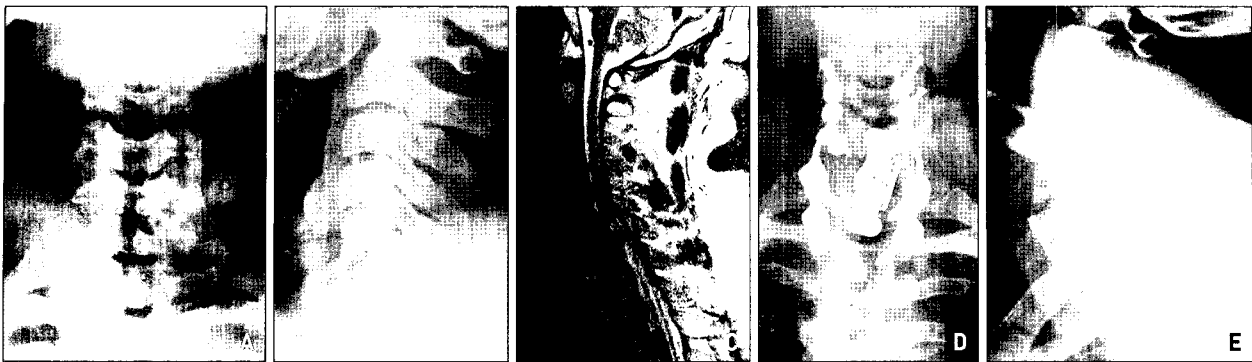Case 1 presented with quadriplegia (Fig. 1). Due to poor visualization of the cervicothoracic region on standard lateral cervical spine radiographs, we could not find the lesion. Cervical

**Table 1.** Clinical details of three cases

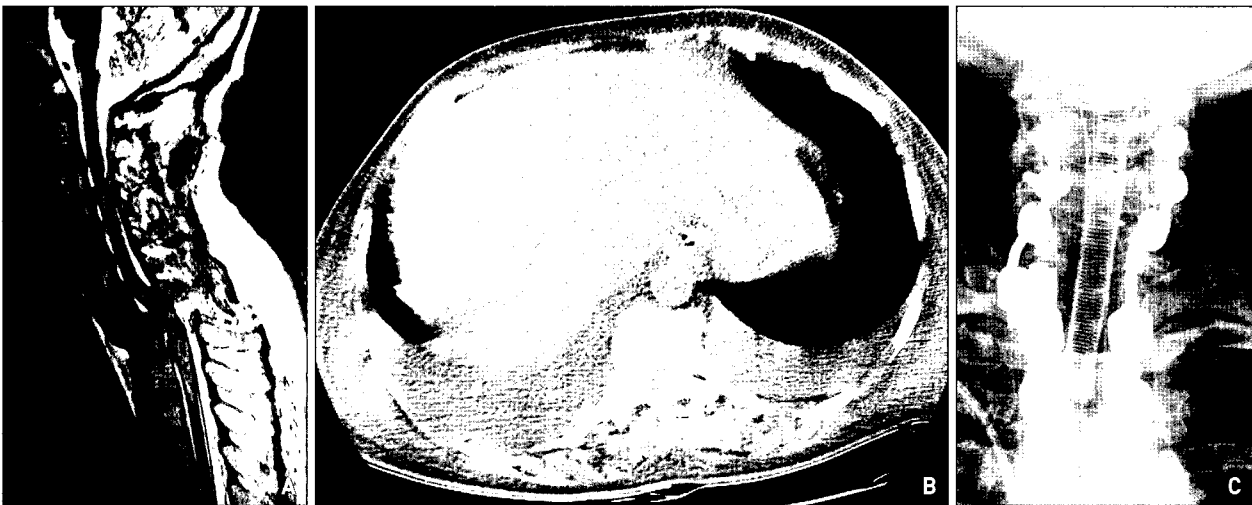Case	Age (yr) / Sex	Diagnosis	Procedure	Frankel Grade (Initial/FU)	Follow-Up (mo)	Outcome
1	29/M	C6-C7 Fx DL C7 bursting Fx	Posterior open reduction; C4-T2 posterior fusion; C7 corpectomy; C6-T1 anterior fusion with sternotomy	C/D	27	Good
2	54/F	C7-T1 Fx DL	Posterior open reduction; C5-T3 posterior fusion	A/A	1	Good
3	45/F	C7 bursting Fx	C7 corpectomy; C6-T1 anterior fusion without sternotomy; C5-T2 posterior fusion	E/E	3	Excellent

• Received : October 4, 2006  
 • Accepted : August 8, 2007  
 • Address for reprints :  
 Ju-Ho Jeong, M.D.  
 Department of Neurosurgery  
 College of Medicine, Dongguk  
 University Gyeongju Hospital  
 1090-1 Seokjang-dong  
 Gyeongju 780-350, Korea  
 Tel : +82-54-748-9300  
 Fax : +82-54-770-8500  
 E-mail : ktokhou@hanmail.net

yr : year, mo : month, FU : follow-up, Fx : fracture, DL : dislocation



**Fig. 1.** Case 1. Anteroposterior (A) and lateral (B) cervical spine radiographs fail to demonstrate the cervicothoracic junction. Sagittal T2-weighted magnetic resonance image (C) of the cervical spine shows dislocation of C6 on C7, C7 bursting fracture and spinal cord compression. Quality of MRI is not good due to motion artifact from poor cooperation of the patient. Postoperative radiographs (D, E) demonstrating anterior, posterior instrumentation and wires used for sternotomy.



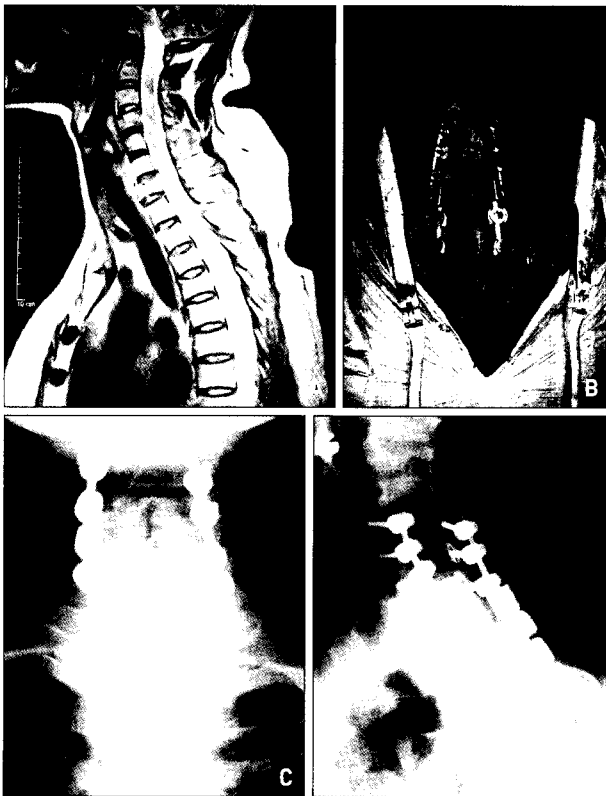
**Fig. 2.** Case 2. Sagittal T2-weighted magnetic resonance image (A) of the cervical spine shows dislocation of C7 on T1 and spinal cord compression. Chest computed tomography (B) demonstrates severe hemothorax. Postoperative anteroposterior cervical spine radiograph (C) shows posterior instrumentation.

MRI revealed a C6-C7 fracture-dislocation and a C7 burst fracture. He underwent posterior fixation after decompression and open reduction followed by C7 corpectomy and anterior cervical strut reconstruction with sternotomy. Lateral mass polyaxial screws in C4, C5, C6 and pedicle polyaxial screws were placed in T1, T2 and two dual diameter rods were used to connect with polyaxial screw heads at both sides instrumentation. A lateral offset connector was necessary to link the rod with polyaxial screw head in right C7 pedicle. Also, sternotomy was performed because of position of the manubrium. Finally, a mesh cylinder packed with bone chips in C7 corpectomy site was inserted and then an anterior locking plate system was placed. He could ambulate at the time of discharge.

Case 2 presented with quadriplegia (Fig. 2). Associated injuries were multiple rib fractures and hemothorax. Cervical MRI revealed a C7-T1 fracture-dislocation. She underwent posterior fixation after decompression and open

reduction. Lateral mass polyaxial screws in C5, C6 and pedicle polyaxial screws were inserted in C7, T1, T2. Dual diameter rod was used to connect with polyaxial screw heads at left instrumentation. At right instrumentation, two rods which were different in diameter were used. They were connected each other by a side-by-side rod connector. After surgery, however, patient died of acute respiratory distress syndrome after one month of hospitalization.

Case 3 presented with neck pain, left arm pain and paresthesia (Fig. 3). She was initially seen at department of thoracic surgery because of hemothorax, multiple rib fractures and clavicle fracture. Initial cervical spine radiographs were thought to be normal but neck pain and left arm pain persisted. Cervical MRI revealed a C7 burst fracture and the fractured fragment was compressing the dural sac. Preoperative midsagittal cervical MR images revealed that the position of manubrium was not an obstacle for anterior cervical approach. She underwent C7 corpectomy and



**Fig. 3.** Case 3. Sagittal T2-weighted magnetic resonance image (A) of the cervical spine shows C7 bursting fracture without spinal cord compression. This midsagittal magnetic resonance images suggest that manubrium is not an obstacle to anterior approach. Intraoperative photograph (B) shows posterior instrumentation. Postoperative radiographs (C, D) demonstrate anterior and posterior instrumentation.

anterior cervical fusion without sternotomy. A mesh cylinder packed with bone chips in C7 corpectomy site was inserted and then an anterior locking plate system was placed. One week later, she underwent posterior fixation. Lateral mass polyaxial screws in C4, C5, C6 and pedicle polyaxial screws were placed in T1, T2. We used side-by-side rod connectors in both sides to connect two different diameter rods which were connected polyaxial screw heads. She made a complete recovery at discharge.

## DISCUSSION

The incidence of fracture-dislocation at the cervicothoracic junction is 2.4% to 9% in cervical spine-injured population reported by Amin et al.<sup>3</sup>. The cervicothoracic junction injury is rare but requires careful attention to the patients by acceleration-deceleration mechanism. It requires prompt diagnosis and treatment for optimal outcomes.

The possibility of cervicothoracic junction instability in the unconscious head- or chest-injured patient should always be borne in mind and adequate visualization of the

cervicothoracic junction together with full protective spinal measures employed in all cases until satisfactory studies are completed and formally reported. In equivocal cases, arrangements for alternative imaging methods such as swimmer views, CT, radioisotope bone scan, and MRI should be made. If the patients who were injured by acceleration and deceleration mechanism complain vague symptoms such as lower nuchal pain, the possibility of cervicothoracic junction injury should be considered.

The cervicothoracic junction is unique in many aspects. It is a transition between the extremely flexible cervical spine and the rigid thoracic spine. This transitional nature of the cervicothoracic junction subjects a multisegment anterior fusion construct to increased mechanical stress leading to the failure of the anterior spinal fusion. However, when fusing multiple levels including the cervicothoracic junction via anterior approach, supplemental posterior instrumentation increases construct rigidity, potentially limiting the failure of the anterior spinal fusion. Boockvar et al.<sup>9</sup> reported that anterior reconstruction alone may not meet the biomechanical needs of this spinal region and that supplementary fixation may be considered to augment stabilization for fusion success.

Instability between C7 and T1 can lead to an increased kyphosis with subsequent narrowing of the spinal canal and damaging of the spinal cord. The management goals are immediate stabilization, maintenance of anatomic alignment and early rehabilitation. Many authors have pointed out that the area is a potentially unstable site, much like the thoracolumbar and lumbosacral junction<sup>4,5,10</sup>.

The approach to this region is more technically demanding. Anterior approach to this region is complicated by the presence of major vascular element as well as important visceral and soft-tissue structures. Exposure of the anterior aspect of the cervicothoracic junction may be obtained via a low cervical approach with or without the creation of a manubrial window. This approach obviates the need for a thoracotomy, sternotomy or medial clavicular excision. This approach needs preoperative midsagittal cervicothoracic MRI to evaluate whether the manubrium is an obstacle or not and a meticulous surgical technique to avoid any injury to vital neurovascular structures. Preoperative MRI can be an effective tool for anterior spinal fusion of the cervicothoracic junction and upper thoracic spine<sup>7,9</sup>. Fraser et al.<sup>7</sup> demonstrated reliable, reproducible, and practical criteria that effectively evaluate the cervicothoracic region on MRI. They recommend preoperative midsagittal cervical MRI as decision-making tool of anterior approach to the cervicothoracic junction and upper thoracic spine.

Posterior instrumentation is also difficult at the cervicothoracic region. Because of shoulder and chest wall, C-

arm fluoroscopy is not useful as an intraoperative image guidance. Anteroposterior radiograph by intraoperative C-arm fluoroscopy does not demonstrate a true anatomic cortical line of the thoracic pedicle. It is a kind of overlapping image just like a innominate line of temporal bone in anteroposterior radiograph of skull. Moreover, pedicle diameter at this region, is too small to place transpedicular screw safely. Because of acute transition of cervicothoracic curvature and variation of interpedicular distance and inner pedicular diameter, it is also difficult to connect rod to pedicle screw. But recent technical advance and biomechanical studies make posterior instrumentation easier, safer and more effective<sup>10</sup>.

The transition of techniques from wires to rods, and from lateral mass screws to pedicle screws has improved stabilization options at the cervicothoracic junction. Pedicle screw fixation has become an ideal alternative for fixation at the cervicothoracic junction. The addition of multiaxial screws, dual diameter rods, and interlocking connections has also improved the ease of stabilization<sup>10</sup>.

Usually, lateral mass fixation can be considered for C3-C6 and pedicle screw fixation can be considered for vertebrae caudal to C6. In assembling a cervicothoracic construct, one must take into account the offset between the laterally directed lateral mass screws and the medially directed pedicle screws. Further, a full understanding of the advantage and disadvantages of the potential instrumentation systems helps avoid unanticipated instrumentation limitations and prolonged operative times.

If dual diameter rod is used, the offset between the laterally directed lateral mass screws and the medially directed pedicle screws often makes rod connection to adjacent fixation points difficult. The solution for this problem is the lateral offset connector. The Vertex (Medtronic Sofamor Danek, Memphis, TN) multiaxial screws allow approximately 5 mm medial-lateral variability without the need for additional rod contouring. Offset connectors can be used to facilitate coupling the screws to the rod if further medial-lateral offset is required. But, the three dimensional bending of dual diameter rod is very complex procedure due to much mechanical limitations.

If only cervical pedicle screw and rod system are used, no system interface needs to be considered. However, if a construct is made with the Vertex and Legacy systems (Medtronic Sofamor Danek, Memphis, TN) or the Summit and Moss-Miami (Depuy JNJ, Raynham, MA), a side-by-side connector or end-to-end connector must be used. Vertex and Legacy systems can be coupled with side-by-side rod connectors. These connectors allow for transition from the 3.2 mm Vertex rod to the 5.5 or 6.35 mm Legacy rods. No tapered dual diameter rod is available for these system. The disadvantage of the side-by-side connector is that it may require more

medial-to-lateral room than is available. Depending on patient's anatomy, a level of the instrumentation may have to be skipped if the connector is too long.

Jones et al.<sup>8</sup> reported that cervical pedicle screws demonstrated a significantly higher resistance to pull-out forces than did lateral mass screws. Rhee JM et al.<sup>13</sup> reported that C7 pedicle screw fixation provides the highest stiffness for stabilizing the cervicothoracic junction. If C7 pedicle fixation is not possible, then performing two-level lateral mass fixation at C6 and C7 will achieve similar stiffness except in axial compression<sup>13</sup>. The addition of triple wiring to the spinous processes does not significantly increase lateral mass construct normalized stiffness<sup>13</sup>. Abumi and Kaneda<sup>1</sup> reported that pedicle screw fixation is a useful procedure for posterior reconstruction of the cervical spine. This procedure does not require the lamina for stabilization, and should be especially valuable for simultaneous posterior decompression and fusion. The risk to neurovascular structures, however, cannot be completely eliminated. Albert et al.<sup>2,11</sup> reported that pedicle screws in C7 placed with a laminoforaminotomy and palpation technique seemed to be safe and effective while offering excellent fixation.

Richter et al.<sup>14</sup> reported that transpedicular screws in the cervical spine and cervicothoracic junction can be applied safely and with high accuracy in a computer-assisted surgery (CAS) system (VectorVision : BrainLAB AG, Heimstetten, Germany). The CAS system leads to significantly reduced screw misplacement rates. Therefore, because of the potential risk of injury to the vertebral artery and neural elements, the use of a CAS system seems to be beneficial, especially for pedicle instrumentation C3-C6.

The thoracic pedicle is different from that of the lumbar spine because its mediolateral diameter is significantly less than its superoinferior diameter and it has less medial inclination<sup>6</sup>. The dural sac lies immediately medial to the pedicle, and the spinal nerve roots run superior and inferior to the pedicle as they exit from the dural sac<sup>6</sup>. Therefore, pedicular screw insertion in the sagittal plane seems to be safer than that in the transverse plane in the thoracic spine<sup>6</sup>.

McLain et al.<sup>12</sup> reported on T1-T6 vertebrae from 18 human cadavers, ages 62 to 85 years at death. The authors measured each vertebra to determine medial-lateral pedicle width, cranial-caudal pedicle height, and coaxial depth from lamina to anterior vertebral cortex. Pedicle diameter uniformly diminished as specimens proceeded caudally from T2. Findings showed that 25% of T1 pedicles, 17% of T2 pedicles, and 42% of T3 pedicles were narrower than 5.5 mm. At T4, 61% of pedicles were too small, at T5, 67% were too small, and at T6, 75% were too small to accept a 5.5-mm screw. They concluded that even the largest

patients had some pedicles that could not accommodate the smallest standard pedicle screw, and that more than one half of the pedicles in average patients were too small.

Transpedicular screw placement is not safe in these patients. Proper placement must avoid penetration of the medial pedicle wall.

## CONCLUSION

Cervicothoracic junction injury should be studied carefully in initial assessment of patients with severe multiple traumas, because such injuries are likely to be missed. Cervicothoracic junction instability should be stabilized through the circumferential fusion but the procedure is not simple owing to unique anatomy and technical limitations. Further, a full understanding of the advantage and disadvantages of the potential instrumentation systems will help to avoid unanticipated instrumentation limitations and prolonged operative times.

## References

1. Abumi K, Kaneda K : Pedicle screw fixation for nontraumatic lesions of the cervical spine. *Spine* 22 : 1853-1863, 1997
2. Albert TJ, Klein GR, Joffe D, Vaccaro AR : Use of cervicothoracic junction pedicle screws for reconstruction of complex cervical spine pathology. *Spine* 23 : 1596-1599, 1998
3. Amin A, Saifuddin A : Fractures and dislocations of the cervicothoracic junction. *J Spinal Disord Tech* 18 : 499-505, 2005
4. An HS, Vaccaro A, Cotler JM, Lin S : Spinal disorders at the cervicothoracic junction. *Spine* 19 : 2557-2564, 1994
5. Boockvar JA, Philips MF, Telfeian AE, O'Rourke DM, Marcotte PJ : Results and risk factors for anterior cervicothoracic junction surgery. *J Neurosurg (Spine 1)* 94 : 12-17, 2001
6. Ebraheim NA, Jabaly G, Xu R, Yeasting RA : Anatomic relations of the thoracic pedicle to the adjacent neural structures. *Spine* 22 : 1553-1556, 1997
7. Fraser JF, Diwan AD, Peterson M, O'Brien MF, Mintz DN, Khan SN, et al : Preoperative magnetic resonance imaging screening for a surgical decision regarding the approach for anterior spine fusion at the cervicothoracic junction. *Spine* 27 : 675-681, 2002
8. Jones EL, Heller JG, Silcox DH, Hutton WC : Cervical pedicle screws versus lateral mass screws. Anatomic feasibility and biomechanical comparison. *Spine* 22 : 977-982, 1997
9. Kim HS, Kim YB, Kwon JT, Park K, Min BK, Hwang SN, et al : A study on the distance and height of the suprasternal Notch - Cervicothoracic vertebrae in normal Korean adults. *J Korean Neurosurg Soc* 25 : 758-763, 1996
10. Le H, Balabhadra R, Park J, Kim D : Surgical treatment of tumors involving the cervicothoracic junction. *Neurosurg Focus* 15 : E3, 2003
11. Ludwig SC, Kramer DL, Vaccaro AR, Albert TJ : Transpedicle screw fixation of the cervical spine. *Clin Orthop Relat Res* 359 : 77-88, 1999
12. McLain RF, Ferrara L, Kabins M : Pedicle morphometry in the upper thoracic spine : limits to safe screw placement in older patients. *Spine* 27 : 2467-2471, 2002
13. Rhee JM, Kraiwattanapong C, Hutton WC : A comparison of pedicle and lateral mass screw construct stiffnesses at the cervicothoracic junction : a biomechanical study. *Spine* 30 : E636-640, 2005
14. Richter M, Cakir B, Schmidt R : Cervical pedicle screws : conventional versus computer-assisted placement of cannulated screws. *Spine* 30 : 2280-2287, 2005