

A case of hereditary hemorrhagic telangiectasia

Young Seung Lee, M.D., Seonguk Kim, M.D.
Eun Kyeong Kang, M.D. and June Dong Park, M.D.

Department of Pediatrics, Seoul National University College of Medicine, Seoul, Korea

Hereditary hemorrhagic telangiectasia (HHT), which is characterized by the classic triad of mucocutaneous telangiectases, arteriovenous malformations (AVMs) and inheritance, is an autosomal dominant disorder. The characteristic manifestations of HHT are all due to abnormalities of the vascular structure. This report deals with the case of a 14-year-old girl with typical features of HHT that include recurrent epistaxis, mucocutaneous telangiectases, pulmonary and cerebral AVMs and a familial occurrence. (**Korean J Pediatr 2007;50:1018-1023**)

Key Words : Telangiectasia, Hereditary Hemorrhagic, Recurrence, Epistaxis, Arteriovenous Malformations, Inheritance Patterns

Introduction

Hereditary hemorrhagic telangiectasia (HHT), which is also known as Rendu-Osler-Weber disease and is characterized by the classic triad of mucocutaneous telangiectases, AVMs and inheritance, is an autosomal dominant disorder. In recent studies, the incidence of the disease was estimated to be approximately 1 in 5,000-8,000¹⁻³⁾ and about 20% of patients were estimated to have a negative familial history. Spontaneous recurrent epistaxis, which is caused by bleeding from telangiectases of the nasal mucosa, is the most common manifestation⁴⁾. Telangiectases can occur throughout the gastrointestinal (GI) tract and on the lips, tongue, buccal mucosa, face, ears, hands and fingertips^{5,6)}. Pulmonary AVMs occur in approximately 15-20% of patients with HHT⁷⁾, and cerebral AVMs occur in 4%⁸⁾, while hepatic AVMs rarely occur. Several cases of HHT have been reported in Korea, but there was only two cases in children, which manifested by frequent epistaxis and pulmonary AVMs without cerebral AVMs and a family history of HHT⁹⁾. We describe a case of HHT which is manifested by recurrent epistaxis, AVMs in the lung and brain and a family history of HHT.

Case Report

A 14-year-old girl was referred to our hospital because of recurrent nose bleeds and pulmonary AVMs. She had been suffering from recurrent nose bleeds, which occurred approximately three times a week, since she was six years old. She had also suffered from dyspnea on exertion two years ago, which had been observed without any medical intervention. When she went up a mountain one month prior to our analysis, her dyspnea was aggravated and cyanosis developed, forcing her to visit an outside hospital. The chest radiography and chest computed tomography (CT) were then conducted, which revealed pulmonary AVMs. She was transferred to our hospital for further evaluation and management of the pulmonary AVMs.

On family history (Fig. 1), her grandmother had been receiving a monthly red blood cell transfusion due to recurrent GI bleedings. In addition, her father had been operated on for pulmonary AVMs, had been having recurrent nose bleeds and had been suffering from iron deficiency anemia (IDA), while her brother had been operated on for cerebral AVMs and got quadriplegia as that sequela.

On the day of admission, she had lip cyanosis. Oxygen saturation was approximately 80% in room air. Her conjunctivae were slightly anemic and multiple telangiectases were observed on the tongue (Fig. 2). The chest wall was expanded symmetrically without retraction and breathing sound

접수 : 2007년 8월 8일, 승인 : 2007년 9월 11일

책임저자 : 박준동, 서울대학교 의과대학 소아과학교실

Correspondence : June Dong Park, M.D.

Tel : 02)2072-3359 Fax : 02)762-3359

E-mail : jdparkmd@snu.ac.kr

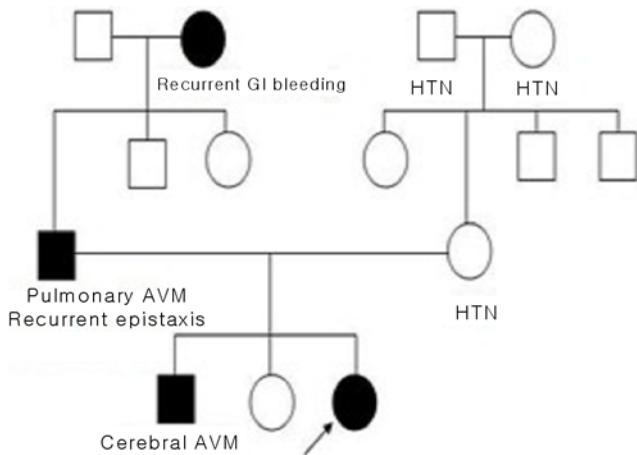


Fig. 1. The Pedigree of the patient. The patient's grandmother, father and brother are suspected of hereditary hemorrhagic telangiectasia.

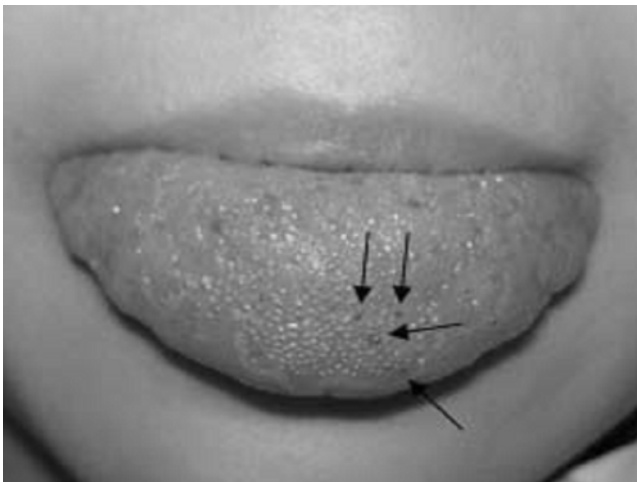


Fig. 2. Multiple telangiectases (arrows) are observed on the tongue.

was clear without rales nor wheezing. Heart sound was regular without audible murmur. Digital clubbing was observed.

Blood laboratory findings demonstrated that IDA such as hemoglobin was 10.6 g/dL, iron was 22 ug/dL, total iron binding capacity was 495 ug/dL and ferritin was <3 ng/mL. The chest radiography showed multiple, round-shaped lesions in the middle and lower lobe of the right lung and lower lobe of the left lung (Fig. 3). The chest CT demonstrated AVMs in both lungs (Fig. 4). There was no pul-

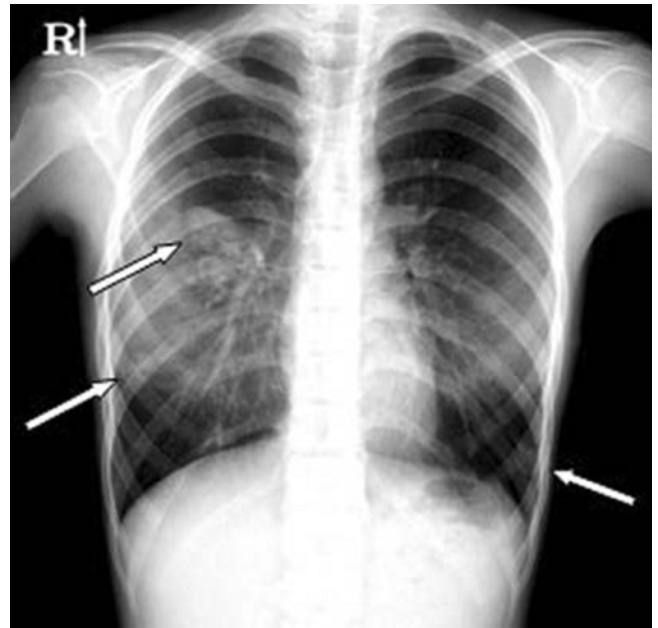


Fig. 3. The chest radiography shows pulmonary arteriovenous malformations (arrows) in the middle and lower lobe of the right lung and lower lobe of the left lung.

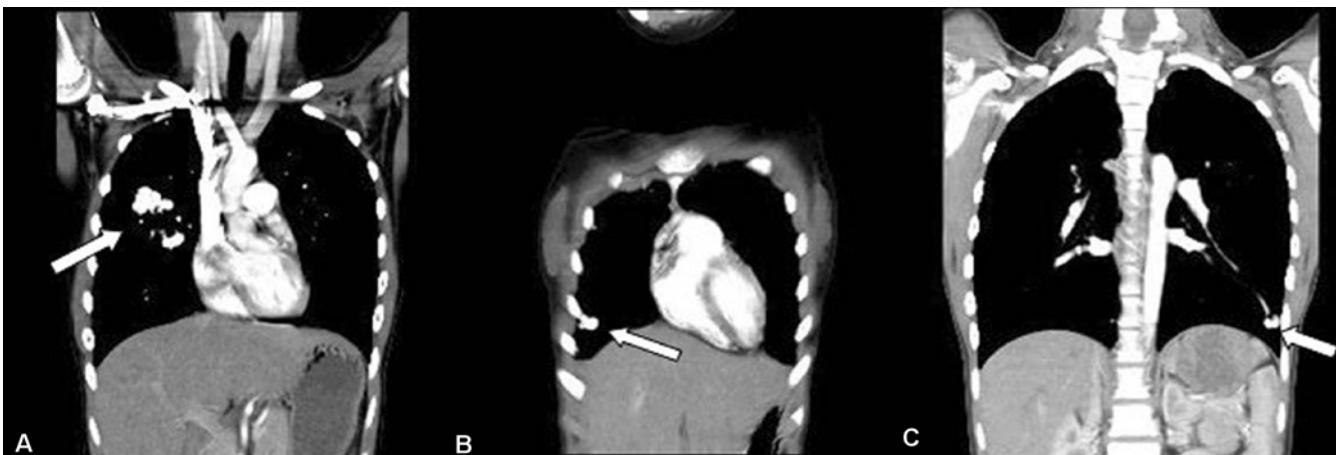

Fig. 4. The chest computed tomography demonstrates pulmonary arteriovenous malformations (arrows) in the middle and lower lobe in the right lung (A, B) and lower lobe of the left lung (C).

monary hypertension finding in the echocardiography. The pulmonary angiography was performed and coil embolization was done for the large pulmonary AVMs in the middle lobe of the right lung (Fig. 5). Oxygen saturation was increased from 80% to 95% just after coil embolization. Pulmonary AVMs remained in the middle and lower lobe of the right lung and lower lobe of the left lung (Fig. 6), for which coil embolization was to be scheduled. The brain magnetic resonance imaging (MRI), magnetic resonance angiography (MRA) and transfemoral cerebral angiography

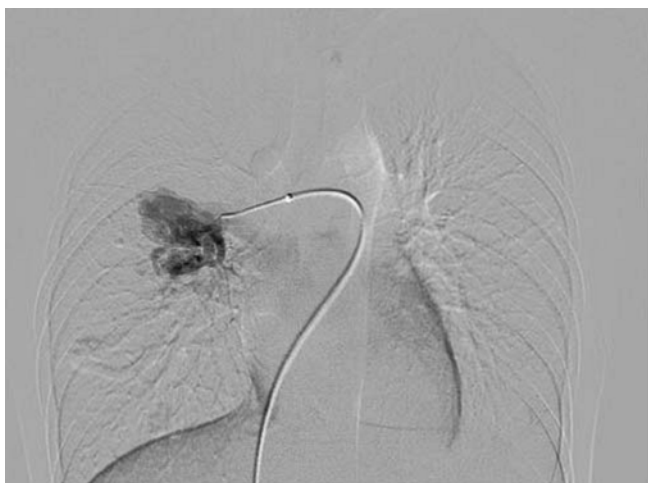


Fig. 5. The pulmonary angiography reveals the largest pulmonary arteriovenous malformation in the middle lobe of the right lung.

(TFCA) revealed a cerebral AVM in the left superior frontal gyrus (Fig. 7) and was treated by the gamma knife. The abdomen CT demonstrated no evidence of hepatic AVMs or abnormal AVMs in the abdomen and pelvis. The otolaryngologic examination was performed for recurrent epistaxis and telangiectases were detected in the left nasal cavity. Electrocauterization failed. The TFCA was performed and embolization was done for the telangiectases (septal branch of the left sphenopalatine artery and superior labial artery of the left infraorbital and facial artery). The recurrent spontaneous nose bleeds continued but the frequency and amount of epistaxis were decreased.

Discussion

Hereditary hemorrhagic telangiectasia, or Rendu-Osler-Weber syndrome, is an autosomal dominant disease, characterized by mucocutaneous telangiectases, AVMs and familial occurrence. The diagnosis of HHT is a clinical diagnosis based on the Curaçao criteria¹⁰, which contains the following four main clinical features: (i) spontaneous recurrent nose bleeds; (ii) muco-cutaneous telangiectasia; (iii) visceral AVMs; (iv) an affected first-degree relative. These criteria define “definite HHT” where three criteria are present, “suspected HHT” where two criteria are present or “unlikely HHT” where only one criterion is present. According to these criteria, our patient was diagnosed as having “definite

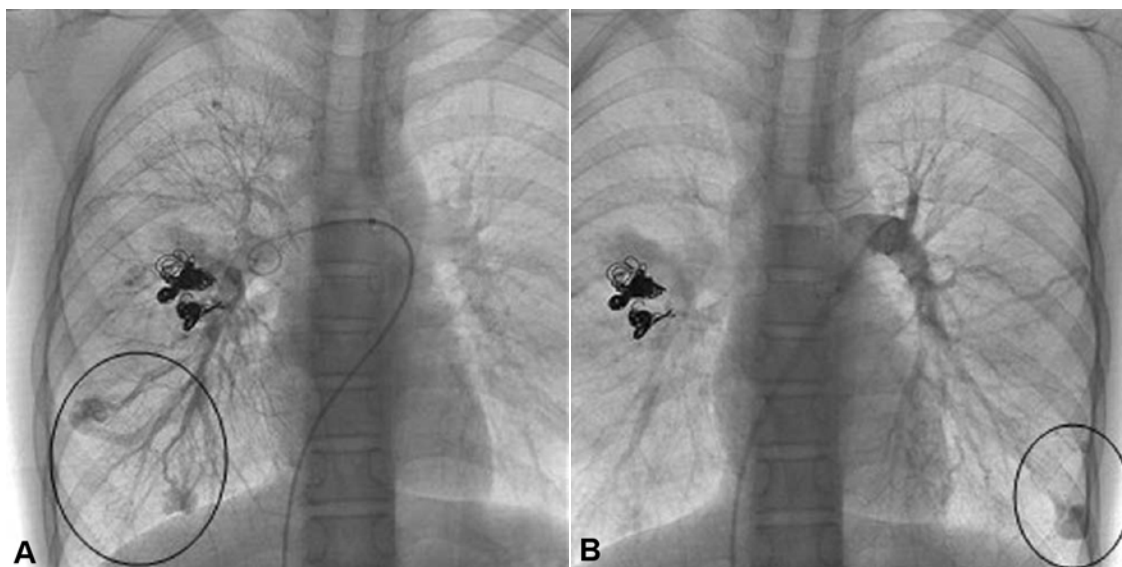


Fig. 6. Pulmonary arteriovenous malformations (circles) remain in the middle and lower lobe of the right lung (A) and lower lobe of the left lung (B) after coil embolization for the the largest pulmonary arteriovenous malformation.

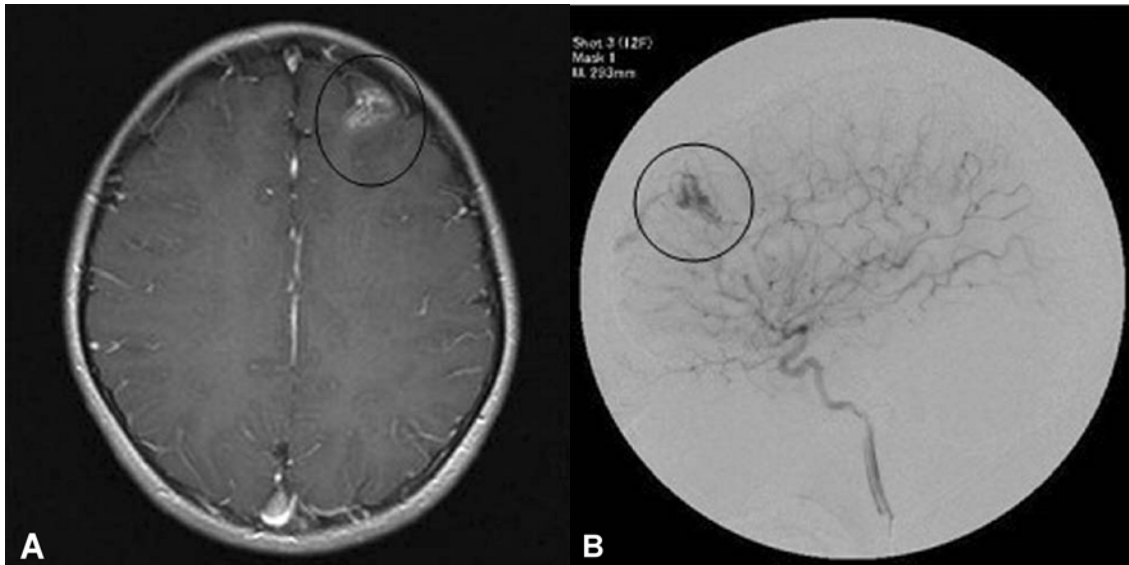


Fig. 7. The brain magnetic resonance imaging (A) and transfemoral cerebral angiography (B) reveal a cerebral arteriovenous malformation (circles) in the left superior frontal gyrus.

HHT”.

Genetic linkages to HHT have been established to chromosome 9p33-34 in some families¹¹⁾ and to chromosome 12q in others¹²⁾. It is possible that genes on the other chromosomes may also create the condition¹³⁾. The gene for HHT at chromosome 9p33-34 has been identified as endoglin (ENG)¹⁴⁾. The gene encoding for HHT at chromosome 12q has been identified as activin-receptor-like kinase 1 (ALK1)¹⁵⁾. ENG and ALK1 both encode a homodimeric integral membrane glycoprotein, which is the surface receptor for transforming growth factor- β (TGF- β) that is known to have a regulatory role in tissue repair and angiogenesis. It is thought that abnormal vessels in HHT develop because of aberrant TGF signaling at some stage during vascular development and homeostasis¹⁶⁾. The characteristic manifestations of HHT are all due to vascular structural abnormalities of the nose, skin, lung, brain and GI tract⁵⁾. In this case, the patient's grandmother, father and brother are suspected of HHT and a genetic linkage analysis for this family is needed, which will be helpful for genetic counseling during her pregnancy and for predicting the prognosis of the patient and her family involved in HHT.

Epistaxis caused by spontaneous bleeding from telangiectases of the nasal mucosa is the most frequently noticed symptom of HHT and is found in approximately 90% of the patients⁴⁾. Recurrent epistaxis begins by the age of 10 in many patients and by the age of 21 in most, becoming more severe in later decades of life in about two-thirds of

affected individuals⁵⁾. In this case, the patient had also been having recurrent spontaneous nose bleeds since 6 years of age. It had a massive impact on the quality of her life. Embolization was done for the telangiectases in the left nasal cavity. Treatment such as electrocauterization, intranasal topical estrogen and septodermoplasty was used^{17, 18)} and embolization was not tried yet in Korea. This is the first case treated with embolization for epistaxis caused by telangiectases in Korea.

Mucocutaneous telangiectases occur in about 50-80% of individuals and typically present later in life than epistaxis. The lesions mostly occur in any combination of the face, lips, mouth, tongue and buccal mucosa, ears, hands, fingertips and chest, although they can also occur elsewhere^{5, 6)}. There may be bleeding from mucocutaneous telangiectases, but it is rarely clinically significant and the main concern is cosmetic. The patient in this case had multiple telangiectases on the tongue, but these were not observed in any other places on her body.

Pulmonary AVMs consist of direct connections between a branch of a pulmonary artery and a pulmonary vein through a thin-walled aneurysm. It is estimated that approximately 60%-70% of persons with pulmonary AVMs have HHT⁷⁾. Conversely, it is estimated that 15-20% of persons with HHT have pulmonary AVMs, but the incidence of these lesions apparently varies according to specific gene mutation for the condition like ENG and ALK1 that is present¹⁹⁾. Pulmonary AVMs result in direct right-to-left shunts

and bypass the capillary bed. Right-to-left shunts such as these cause hypoxemia, dyspnea, hemoptysis and polycythemia. The right-to-left shunt and absence of a filtering capillary bed allow embolism that can reach the systemic arteries and especially the passage of septic emboli can lead to neurologic complications including transient ischemic attack, cerebral stroke and cerebral abscess⁴. The screening examination for pulmonary AVMs is strictly recommended, since severe complications such as stroke or brain abscess can arise²⁰. The helical CT with a contrast agent can be very cost-effective in spite of its adverse effect of radiation exposure. The treatment of pulmonary AVMs includes therapeutic embolization and surgical resection, and these can almost always be treated completely and permanently using embolization²¹. In this case, the patient had cyanosis and dyspnea on exertion and the chest CT was performed, which revealed pulmonary AVMs that were treated by coil embolization.

According to recent studies, the occurrence rate of cerebral AVMs in HHT is approximately 4%⁸. Neurologic symptoms including migraine headache, brain abscess, transient ischemic attack, stroke, seizure and intracerebral and subarachnoid hemorrhage are common in patients with HHT, particularly those with a personal or family history of pulmonary AVMs⁴. For two-thirds of those in whom neurologic symptoms develop, pulmonary AVMs are the source of the symptoms²². In the remaining one-third, cerebral or spinal AVMs lead to subarachnoid hemorrhage, seizure, or less commonly, paraparesis^{23, 24}. According to a recent study, the risk of being presented with an intracerebral hemorrhage from a cerebral AVM in patients with HHT is approximately 2%⁸. For diagnostic screening purposes, a cerebral MRI is currently the most sensitive non-invasive method, even though it can fail to detect the presence of AVMs. Cerebral AVMs are treated in different ways depending on their size, structure and location in the brain. Neurovascular surgery, embolotherapy and stereotactic radiosurgery can all be used, separately or in combination. The patient in this case did not have neurologic symptoms, but for the purpose of screening, a brain MRI & MRA were performed, which revealed a small AVM in the left superior frontal gyrus, removed by a gamma knife without a sequela. Her brother was operated on for cerebral AVMs and got quadriplegia as that sequela. Her grandmother and father did not have any neurologic symptoms and a brain-imaging study was not conducted on them. Several cases of HHT have been re-

ported in Korea but there was only two cases in children which manifested by pulmonary AVMs without cerebral AVMs and a family history of HHT⁹. In other words, this is the first case of HHT combined with cerebral AVMs and a strong family history in children which has not been reported yet in Korea.

Recurrent hemorrhage of the GI tract occurs in a minority of patients with HHT and is one of the manifestations of the condition that is most difficult to manage¹⁷. GI bleeding does not usually start until the fifth or sixth decade⁵. Telangiectases occur throughout the GI tract and are more commonly situated in the stomach or duodenum than in the colon. AVMs and aneurysms are less common. Photocoagulation using bipolar electrocoagulation or laser technique may control bleeding GI telangiectases in the short term but are less effective over the long term. In this case, the patient did not have a history of GI bleeding but her grandmother had been having recurrent GI bleeding and had been receiving a monthly red blood cell transfusion.

Liver involvement due to the presence of multiple AVMs or atypical cirrhosis is a rare but important manifestation of HHT. Patients with hepatic involvement of HHT can also have with high-output heart failure, portal hypertension and biliary disease²⁶. Hepatic AVMs are currently treated only if a patient shows signs of liver or heart failure as a result of their hepatic AVMs. Embolization, which has been so successful for the treatment of pulmonary AVMs, can cause severe complications when performed in the liver.

한글 요약

유전성 출혈성 모세혈관 확장증 1례

서울대학교 의과대학 소아과학교실

이영승 · 김성국 · 강은경 · 박준동

유전성 출혈성 모세혈관 확장증은 피부 점막 모세혈관확장증, 동정맥기형, 가족력을 3대 증상으로 하는 상염색체 우성 유전성 질환이다. 빈번한 코피가 가장 흔한 증상이며 폐, 뇌, 간 등에 동정맥기형이 동반될 수 있다. 저자들은 빈번한 코피, 폐와 뇌동정맥기형, 가족력을 가진 유전성 출혈성 모세혈관확장증 1례를 경험하고 이를 보고하는 바이다.

References

- 1) Bideau A, Plauchu H, Brunet G, Robert J. Epidemiological investigation of Rendu-Osler disease in France: its geo-

- graphical distribution and prevalence. *Population* 1989;44:3-22.
- 2) Kjeldsen AD, Vase P, Green A. Hereditary haemorrhagic telangiectasia: a population-based study of prevalence and mortality in Danish patients. *J Intern Med* 1999;245:31-9.
 - 3) Dakeishi M, Shiya T, Wada Y, Shindo T, Otaka K, Manabe M et al. Genetic epidemiology of hereditary hemorrhagic telangiectasia in a local community in the northern part of Japan. *Hum Mutat* 2002;19:140-8.
 - 4) Cottin V, Plauchu H, Bayle JY, Barthelet M, Revel D, Cordier JF. Pulmonary arteriovenous malformations in patients with hereditary hemorrhagic telangiectasia. *Am J Respir Crit Care Med* 2004;169:994-1000.
 - 5) Guttmacher AE, Marchuk DA, White RI. Hereditary hemorrhagic telangiectasia. *N Engl J Med* 1995;333:918-24.
 - 6) Plauchu H, de Chadavrian JP, Bideau A, Robert JM. Age-related clinical profile of hereditary hemorrhagic telangiectasia in an epidemiologically recruited population. *Am J Med Genet* 1989;32:291-7.
 - 7) Dines DE, Arms RA, Bernatz PE, Gomes MR. Pulmonary arteriovenous fistulas. *Mayo Clin Proc* 1974;49:460-5.
 - 8) Maher CO, Piepgras DG, Brown RD, Friedman JA, Pollock BE. Cerebrovascular manifestations in 321 cases of hereditary hemorrhagic telangiectasia. *Stroke* 2001;32:877-82.
 - 9) Kim HJ, Yoon YS, Seo JK, Moon HR, Yeon KM. Hereditary hemorrhagic telangiectasia with pulmonary arteriovenous fistula. *Korean J Pediatr* 1984;27:390-4.
 - 10) Shovlin CL, Guttmacher AE, Buscarini E, Faughnan ME, Hyland RH, Westermann CJ et al. Diagnostic criteria for hereditary hemorrhagic telangiectasia (Rendu-Osler-Weber syndrome). *Am J Med Genet* 2000;91:66-7.
 - 11) McDonald MT, Papenberg KA, Ghosh S, Glatfelter AA, Biesecker BB, Helmbold EA et al. A disease locus for hereditary haemorrhagic telangiectasia maps to chromosome 9q33-34. *Nat Genet* 1994;6:197-204.
 - 12) Johnson DW, Berg JN, Gallione CJ, McAllister KA, Warner JP, Helmbold EA et al. A second locus for hereditary hemorrhagic telangiectasia maps to chromosome 12. *Genome Res* 1995;5:21-8.
 - 13) Cole SG, Begbie ME, Wallace GM, Shovlin CL. A new locus for hereditary haemorrhagic telangiectasia (HHT3) maps to chromosome 5. *J Med Genet* 2005;42:577-82.
 - 14) McAllister KA, Grogg KM, Johnson DW, Gallione CJ, Baldwin MA, Jackson CE et al. Endoglin, a TGF-beta binding protein of endothelial cells, is the gene for hereditary haemorrhagic telangiectasia type 1. *Nat Genet* 1994;8:345-51.
 - 15) Johnson DW, Berg JN, Baldwin MA, Gallione CJ, Marondel I, Yoon SJ et al. Mutations in the activin receptor-like kinase 1 gene in hereditary haemorrhagic telangiectasia type 2. *Nat Genet* 1996;13:189-95.
 - 16) Begbie ME, Wallace GM, Shovlin CL. Hereditary haemorrhagic telangiectasia (Osler-Weber-Rendu syndrome): a view from the 21st century. *Postgrad Med J* 2003;79:18-24.
 - 17) Song JW, Kim HJ, Yoon YR, Kim YT. A Case of Hereditary Hemorrhagic Telangiectasia managed with intranasal topical estrogen. *Korean J Otolaryngol* 2006;49:447-50.
 - 18) Kim SS, Yoo SY, Kim MS, Choi YS. A case of hereditary hemorrhagic telangiectasia: surgical treatment with modified septodermoplasty. *Korean J Otolaryngol* 1999;42:245-8.
 - 19) Kjeldsen AD, Oxhøj H, Andersen PE, Green A, Vase P. Prevalence of pulmonary arteriovenous malformations (PAVMs) and occurrence of neurological symptoms in patients with hereditary haemorrhagic telangiectasia (HHT). *J Intern Med* 2000;248:255-62.
 - 20) Haitjema T, Disch F, Overtoom TT, Westermann CJ, Lammers JW. Screening family members of patients with hereditary hemorrhagic telangiectasia. *Am J Med* 1995;99:519-24.
 - 21) Morrell NW. Screening for pulmonary arteriovenous malformations. *Am J Respir Crit Care Med* 2004;169:978-9.
 - 22) Burke CM, Safai C, Nelson DP, Raffin TA. Pulmonary arteriovenous malformations: a critical update. *Am Rev Respir Dis* 1986;134:334-9.
 - 23) Kjeldsen AD, Oxhøj H, Andersen PE, Elle B, Jacobsen JP, Vase P. Pulmonary arteriovenous malformations: screening procedures and pulmonary angiography in patients with hereditary hemorrhagic telangiectasia. *Chest* 1999;116:432-9.
 - 24) Matsubara S, Mandzia JL, ter Brugge K, Willinsky RA, Faughnan ME. Angiographic and clinical characteristics of patients with cerebral arteriovenous malformations associated with hereditary hemorrhagic telangiectasia. *AJNR Am J Neuroradiol* 2000;21:1016-20.
 - 25) Kjeldsen AD, Kjeldsen J. Gastrointestinal bleeding in patients with hereditary hemorrhagic telangiectasia. *Am J Gastroenterol* 2000;95:415-8.
 - 26) Garcia-Tsao G, Korzenik JR, Young L, Henderson KJ, Jain D, Byrd B et al. Liver disease in patients with hereditary hemorrhagic telangiectasia. *N Engl J Med* 2000;343:931-6.