

Identification of intracerebral hematoma using ultrasonography in a dog

Dong-In Jung, Chul Park, Byeong-Teck Kang, Jong-Hyun Yoo, Ju-Won Kim, Ha-Jung Kim, Chae-Young Lim, So-Young Lee, Su-Hyun GU, Ra-Young Heo, Hyo-Won Jeon, Jung-Hyun Kim, Ki-Dong Eom, Jong-Im Park, Hee-Myung Park*

College of Veterinary Medicine, Konkuk University, Seoul 143-701, Korea

(Accepted: March 13, 2007)

Abstract : A 3-month-old male Maltese dog was presented with generalized trembling, ataxia, and seizure. The patient had traumatic injury on history takings. Physical examination revealed dome shaped cranium with open fontanelle, nasal hemorrhage, and blepharodema with hemorrhage on the left side. On serum biochemical profiles, creatine phosphokinase was severely elevated. There was no remarkable finding on radiography. Ultrasound images of brain were obtained via a persistence bregmatic fontanelle, and bilaterally dilated lateral ventricles with a hyperechoic mass on the left temporal lobe were detected. Based on clinical signs, history, physical examination, laboratory findings, and ultrasonographic findings, we suspected this intracranial mass to intracerebral hematoma induced by head trauma. Methylprednisolone sodium succinate and furosemide were administrated with oxygenation. However, the patient died in 12 h after initial diagnosis. We performed necropsy and confirmed intracerebral hematoma. This case report describes the identification of intracerebral hematoma using ultrasonography.

Key words : head trauma, intracerebral hematoma, ultrasonography

Head trauma is the most common cause of brain hemorrhage [4]. Subdural, epidural, subarachnoid, and/or intracerebral hematoma occurs due to head injuries, and it is known that a characteristic clinical course occurs for each type of hematoma in humans [3]. Severe head trauma with intracranial hemorrhage is associated with a high degree of mortality in humans and animals [4].

This case report describes the clinical and ultrasonographic findings in a dog had moderate ventromegally and a intracerebral hematoma.

A 3-month-old intact male Maltese dog of 0.96 kg body weight was presented to the Veterinary Medical Teaching Hospital of Konkuk University due to generalized trembling, ataxia, and seizure. The patient had traumatic injury on head 8 h before the presentation. He showed comatose status for 5 min after traumatic injury and neurological signs, such as cluster seizure and ataxia were progressively deteriorated. On physical examination, lethargic condition (not comatose),

dome shaped cranium with open fontanelle, nasal hemorrhage and blepharodema with hemorrhage on the left side were observed (Fig. 1).

The results of complete blood count profiles and urinalysis were normal. Serum chemistry profiles showed increased creatine phosphokinase (> 2,000 U/L; reference range, 10 to 199 U/L). No abnormalities, such as fractures, were revealed on radiographical examination of the head. Ultrasound images of brain were obtained via a persistence bregmatic fontanelle, and bilaterally dilated lateral ventricles with a hyperechoic mass on the left temporal lobe were detected (Fig. 2). Cerebral parenchyma was mildly deviated to the right by mass effect. Based on history takings, we suspected this intracranial mass to intracerebral hematoma induced by head trauma. Methylprednisolone sodium succinate (15 mg/kg CRI for 30 min; Samchundang Phama, Korea) and furosemide (1 mg/kg IV; Handok Phama, Korea) were administrated with humidified oxygenation (100 ml/kg/min) and fluid therapy (normal

*Corresponding author: Hee-Myung Park
College of Veterinary Medicine, Konkuk University, Seoul 143-701, Korea
[Tel: +82-2-450-4140, Fax: +82-2-450-3037, E-mail: parkhee@konkuk.ac.kr]

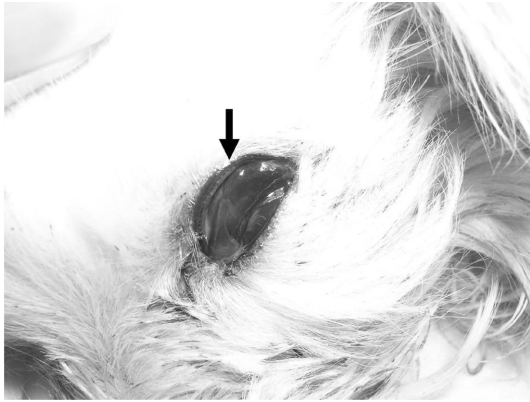


Fig. 1. Left side blepharodema with hemorrhage was observed on physical examination.

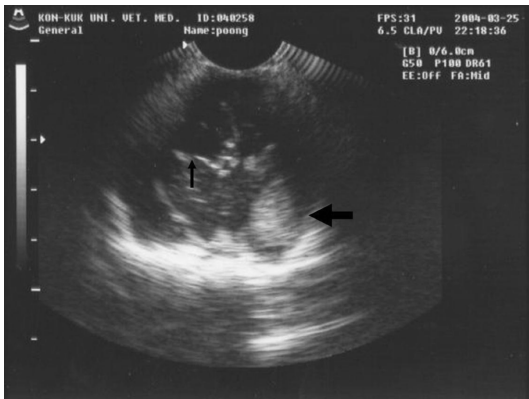


Fig. 2. Ultrasonographic image of the brain. A hyperechoic mass (arrow) was detected on the left temporal lobe. And lateral ventricles were bilaterally dilated (thin arrow). The mass mildly compressed the cerebrum to the right side.

saline; 40 ml/kg/h). Clinical signs were improved gradually after therapy. However, the patient died at 12 h after initial diagnosis. We performed necropsy and confirmed intracerebral hematoma (Fig. 3).

Most clinicians use mannitol in head trauma patients. However, mannitol is contraindicated in patients with intracranial hemorrhage [2]. Thus, we used methylprednisolone sodium succinate and furosemide to decrease intracranial pressure and to prevent shock in this case.

As head trauma and intracranial bleeding are common in veterinary medicine, clinicians have clearly determined the imaging signs associated with extradural, subdural, and subarachnoid hemorrhage. Computed tomography (CT) is still the most common imaging

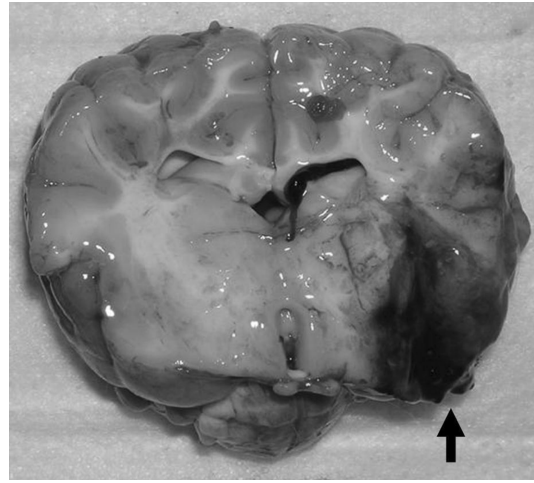


Fig. 3. Necropsy finding revealed intracerebral hematoma and parenchymal necrosis.

modality used for evaluating intracranial hemorrhage due to availability and speed of the procedure [5]. Furthermore, magnetic resonance imaging (MRI) offers better resolution and higher sensitivity, especially with minimal hemorrhage [5]. However, although CT and MRI allow clear definition of the lesion, general anesthesia is necessary and the cost of such studies prevents some clients from pursuing further diagnostics. With advances in technology, transcranial ultrasonography provides a viable alternative to CT and MRI for screening for certain structural brain diseases.

The main disadvantage of transcranial ultrasonography is the relatively poor anatomic detail obtained when compared to CT and MRI. Major structural abnormalities such as hydrocephalus or arachnoid cysts could be identified without difficulty, although the sensitivity for diagnosis of neoplastic and inflammatory lesions is low.

The advantages of transcranial ultrasonography include availability, relative inexpensive and non-invasiveness. In veterinary medicine, the use of ultrasonography to diagnose hydrocephalus or arachnoid cysts in dogs via a persistent fontanelle has been described [4, 6]. If dogs did not have a persistent fontanelle, diagnostic images of their brain could be obtained via the temporal window and the foramen magnum. Therefore, the absence of a persistent fontanelle could not preclude the use of transcranial ultrasonography in small dogs. The diagnostic quality of images obtained by transcranial ultrasonography varies with the imaging

window used. The best images are obtained via a persistent bregmatic fontanelle. Imaging via the temporal window also allows the entire brain to be visualized, however the quality of the images depends on the bone thickness at this site, which varies with breed, age, and individual [4].

The appearance of intracerebral hematoma on CT and MRI have been described in dogs [1, 3, 5, 7]. To the author's knowledge, this is the first report of intracerebral hematoma diagnosed in dogs using ultrasonography. This diagnostic method is useful to estimate the prognosis and to check the progress in head trauma cases without difficulty. Therefore, we suggest that transcranial ultrasonography could be used in small breed dogs to identify the intracerebral hematoma when difficult to use CT or MRI.

References

1. **Adamo PF, Crawford JT, Stepien RL.** Subdural hematoma of the brainstem in a dog: magnetic resonance findings and treatment. *J Am Anim Hosp Assoc* 2005, **41**, 400-405.
2. **Dewey CW.** Head-trauma management. In: Dewey CW (ed.). *A Practical Guide to Canine and Feline Neurology*, 1st ed. pp. 179-192. Blackwell, Ames, 2003.
3. **Kitagawa M, Okada M, Kanayama K, Sakai T.** Traumatic intracerebral hematoma in a dog: MR images and clinical findings. *J Vet Med Sci* 2005, **67**, 843-846.
4. **Lorenz MD, Kornegay JN.** Stupor or coma. In: Lorenz MD, Kornegay JN (eds.). *Handbook of Veterinary Neurology*, 4th ed. pp. 297-322, Saunders, Philadelphia, 2004.
5. **Nykamp S, Scrivani P, DeLahunta A, Yu-Speight A, Riis R.** Chronic subdural hematomas and hydrocephalus in a dog. *Vet Radiol Ultrasound* 2001, **42**, 511-514.
6. **Saito M, Olby NJ, Spaulding K.** Identification of arachnoid cysts in the quadrigeminal cistern using ultrasonography. *Vet Radiol Ultrasound* 2001, **42**, 435-439.
7. **Tamura S, Tamura Y, Tsuka T, Uchida K.** Sequential magnetic resonance imaging of an intracranial hematoma in a dog. *Vet Radiol Ultrasound* 2006, **47**, 142-144.