

## Case Report

Hyeun Sung Kim, M.D.<sup>1</sup>Seok Won Kim, M.D.<sup>2</sup>Seung Myung Lee, M.D.<sup>2</sup>Ho Shin, M.D.<sup>2</sup>

# Endoscopic Discectomy for the Cauda Equina Syndrome During Third Trimester of Pregnancy

Low back pain is common during pregnancy. However, the prevalence of symptomatic lumbar disc herniation is rare, and cauda equina syndrome due to disc herniation during pregnancy is even rarer. We report a rare case of lumbar disc herniation causing cauda equina syndrome during third trimester of pregnancy which successfully treated by endoscopic discectomy. This case shows that endoscopic discectomy can be the treatment option for the lumbar disc herniation during pregnancy.

**KEY WORDS :** Lumbar disc herniation · Pregnancy · Endoscopic discectomy.

Department of Neurosurgery<sup>1</sup>  
Mokpo Hankook Hospital  
Mokpo, Korea

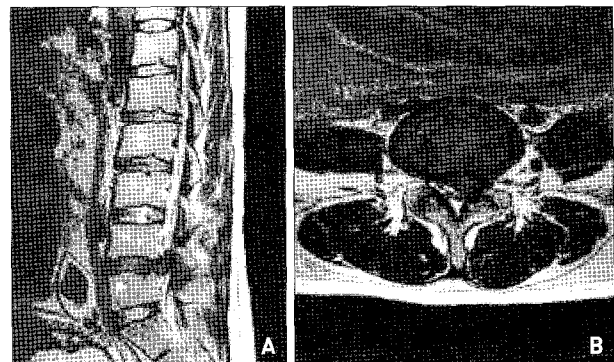
Department of Neurosurgery<sup>2</sup>  
College of Medicine, Chosun  
University, Gwangju, Korea

## INTRODUCTION

Low back pain is a common complaint during pregnancy that has been reported in as many as 56% of women during gestation<sup>5</sup>. However, the incidence of symptomatic lumbar disc herniation is very rare, occurring in only 1 in approximately 10,000 pregnancies. Cauda equina syndrome due to lumbar disc herniation during pregnancy is even rarer<sup>5,8</sup>. We report a rare case of successful endoscopic treatment of cauda equina syndrome. This case is presented to illustrate the current, safe approach to the patients with lumbar disc herniation during pregnancy.

## CASE REPORT

A 30-year-old primigravid nulliparous woman with a 2-month history of intermittent low back pain sought treatment at 30 weeks gestation with excruciating back and leg pain radiating to left and a one-week history of difficulty with walking and voiding. On physical examination, she could not dorsiflex the left foot against gravity. She also had decreased sensation in the L5 nerve root distribution of left lower extremity. She was also experiencing urinary hesitancy. After voiding a large volume of urine, the patient was catheterized, and 120 ml of post-voiding residual urine was retrieved, rectal tone was also slightly decreased, but perianal sensation was intact. Magnetic resonance imaging (MRI) showed a large left sided, paracentral disc prolapse at L4-L5 with effacement of the adjacent nerve root (Fig. 1). Endoscopic lumbar discectomy using lateral approach was performed and large disc fragments that were displaced into the spinal canal were removed (Fig. 2, 3). During the operation, fetal heart monitoring was done. In the immediate postoperative period, the patient experienced complete relief of back and leg pain. However, at the follow up of 3 months after surgery, she had persistent hypoesthesia and slightly weakened dorsiflexion on the left side. The patient delivered a full term healthy girl (birth weight-3.45kg) by cesarian section because of encephalopelvic portion.



**Fig. 1.** A : Sagittal and axial T2 weighted magnetic resonance images show huge disc herniation at L4-L5 level (left side).

- Received : August 24, 2007
- Accepted : September 19, 2007
- Address for reprints :  
Seok Won Kim, M.D.  
Department of Neurosurgery  
College of Medicine  
Chosun University  
588 Seoseok-dong, Dong-gu  
Gwangju 501-717, Korea  
Tel : +82-62-220-3120, 3126  
Fax : +82-62-227-4575  
E-mail : chosunns@hanmail.net




Fig. 2. Disc fragments removed by endoscope.

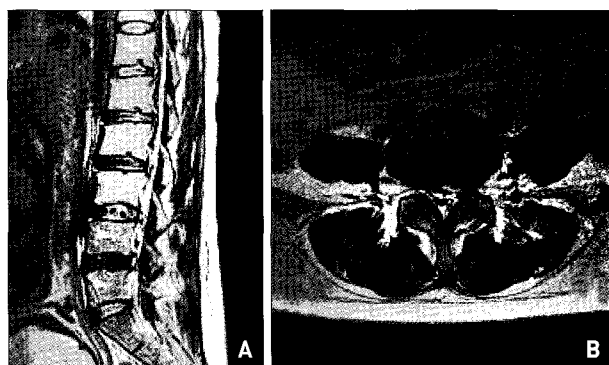


Fig. 3. A : Postoperative sagittal and axial T2 weighted magnetic resonance images revealing well-removed lesional disc.

## DISCUSSION

Although lumbar disc herniation is reported in only 1 in approximately 10,000 pregnancies, and fewer than 2% of lumbar disc herniations are estimated to result in cauda equina syndrome or progressive neurologic deficits, physicians should be aware that these conditions can occur during pregnancy, that they constitute an emergency, and they should be diagnosed and treated immediately regardless the stage of gestation<sup>2</sup>. To avoid permanent sequelae, the diagnosis in a pregnant woman should be made as soon as possible. If severe cauda equina compression is ruled out, bed rest, physiotherapy, muscle relaxants, and analgesia are usually used.

Most can be treated by conservatively by such means. If women are in the second or third trimester, an epidural injection of steroids is also possible. Cauda equina syndrome or severe and/or progressive neurologic deficits caused by lumbar disc displacement is a medical emergency that necessitates prompt surgery to avoid possible permanent sequelae<sup>10</sup>. The patient in this case had cauda equina syndrome. Waiting too long until parturition to undertake treatment in patients showing severe neurologic deficits from disc herniation during pregnancy may result in permanent neurologic deficits. The

literature clearly demonstrates that pregnancy at any stage is not a contraindication to MRI, administration of epidural or general anesthesia, or surgical intervention<sup>6</sup>. The MRI scan used in the patient in the current report is the definitive diagnostic procedure for lumbar disc herniation, and it has been shown to be safe during pregnancy. Most labor such as vaginal and cesarean section deliveries are currently performed under epidural anesthesia, which is known to be safe during any stage of gestation as long as normal maternal blood pressure and PO<sub>2</sub> are maintained<sup>4,6,9</sup>. However, Brown et al. suggested that epidural spinal anesthesia could result in further compression of the cauda equina and possible worsening of the neurologic deficits<sup>3</sup>. Endoscopic discectomy has the advantages of not requiring general anesthesia or epidural anesthesia. During surgery, the position of patients is critical because too excessive abdominal pressure can cause preterm labor<sup>1</sup>. As it does not require general anesthesia, the position of the patient can be repositioned in comparison with microscopic discectomy. Prone self-positioning of the patient allows both the surgeon and the patient to be satisfied that there was no excessive pressure on the uterus and fetus. Fetal heart monitoring during surgery after 23 weeks gestation is indicated to evaluate for abdominal heart rate patterns that may alert the obstetrician or neurosurgeon to take appropriate action to safeguard the fetus<sup>7</sup>.

## CONCLUSION

Timely prompt diagnosis by MRI scan and emergent endoscopic discectomy of lumbar disc herniation causing cauda equina syndrome during pregnancy can be safe and effective treatment.

## References

1. Abou-Shameh MA, Dosani D, Gopal S, McLaren AG : Lumbar discectomy in pregnancy. *Int J Gynaecol Obstet* 92 : 167-169, 2006
2. Ashkan K, Casey AT, Powell M, Crockard HA : Back pain during pregnancy and after childbirth : an unusual cause not to miss. *J R Soc Med* 91 : 88-90, 1998
3. Brown MD, Brookfield KF : Lumbar disc excision and cesarean delivery during the same anesthesia. A case report. *J Bone Joint Surg Am* 86A : 2030-2032, 2004
4. Evans JA, Savitz DA, Kanal E, Gillen J : Infertility and pregnancy outcome among magnetic resonance imaging workers. *J Occup Med* 35 : 1191-1195, 1993
5. Fast A, Shapiro D, Ducommun EJ, Friedmann LW, Bouklas T, Floman Y : Low-back pain in pregnancy. *Spine* 12 : 368-371, 1987
6. Gabbe SG, Niebyl JR, Simpson JL : *Obstetrics*, ed 3. New York : Churchill Livingstone, 1996, pp452
7. Katz JD, Hook R, Barash PG : Fetal heart rate monitoring in pregnant patients undergoing surgery. *Am J Obstet Gynecol* 125 : 267-269, 1976
8. Laban MM, Perrin JC, Latimer FR : Pregnancy and the herniated lumbar disc. *Arch Phys Med Rehabil* 64 : 319-321, 1983
9. Mazze RI, Kallen B : Reproductive outcome after anesthesia and operation during pregnancy : a registry study of 5405 cases. *Am J Obstet Gynecol* 161 : 1178-1185, 1989
10. O'Laoire SA, Crockard HA, Thomas DG : Prognosis for sphincter recovery after operation for cauda equina compression owing to lumbar disc prolapse. *Br Med J (Clin Res Ed)* 282 : 1852-1854, 1981