

Case Report

Dae Kyu Lee, M.D.
Keun-Tae Cho, M.D.
So-Hyang Im, M.D.
Seung-Koan Hong, M.D.

Department of Neurosurgery
Dongguk University International
Hospital, Goyang, Korea

Pleomorphic Xanthoastrocytoma with an Intracystic Hemorrhage : A Case Report and Literature Review

Pleomorphic xanthoastrocytoma (PXA) has been considered as a low grade tumor of adolescents and young adults. Although this tumor often shows cystic component, the hemorrhage within the cyst is extremely rare. The authors report a rare case of cystic PXA with a hemorrhage within the cyst and the mural nodule in the left frontal lobe. A 64-year-old male presented with a week history of the right side hemiparesis. After gross total resection of the tumor, the patient was fully recovered from neurological deficit. It is suggested that this typically benign tumor could be presented with hemorrhage, causing a rapid neurological deterioration. Prompt surgical intervention, especially total removal of the tumor can provide an excellent functional recovery.

KEY WORDS : Pleomorphic xanthoastrocytoma (PXA) · Cyst · Hemorrhage · Mural nodule.

INTRODUCTION

Pleomorphic xanthoastrocytoma (PXA) is an uncommon neoplasm and is considered as a low-grade tumor of adolescents and young adults with a favorable prognosis^{2,5,6,11}. Although over 200 PXAs have been reported so far, the intracranial or intratumoral bleeding is an extremely rare clinical situation, and only a few English-written literatures have been found^{2,8,11}. Erosion of cortical artery by the tumor, thin-walled tumor vessel or unknown microvascular anomaly within the tumor were thought to be contributing factors for the bleeding episode^{8,11}. When bleeding occurs, prognosis is usually poor as three of 4 reported patients died from bleeding^{2,8,11}.

The authors present a case of cystic PXA with intracystic and intramural hemorrhage in elderly patient and discuss the possible mechanisms of hemorrhage and prognosis of patients with hemorrhage.

CASE REPORT

A 64-year-old male presented with a week history of progressive right hemiparesis. He also reported a month history of progressive headache, memory disturbance and dysphasia. Neurological examination showed the mild right side weakness.

Computed tomography (CT)

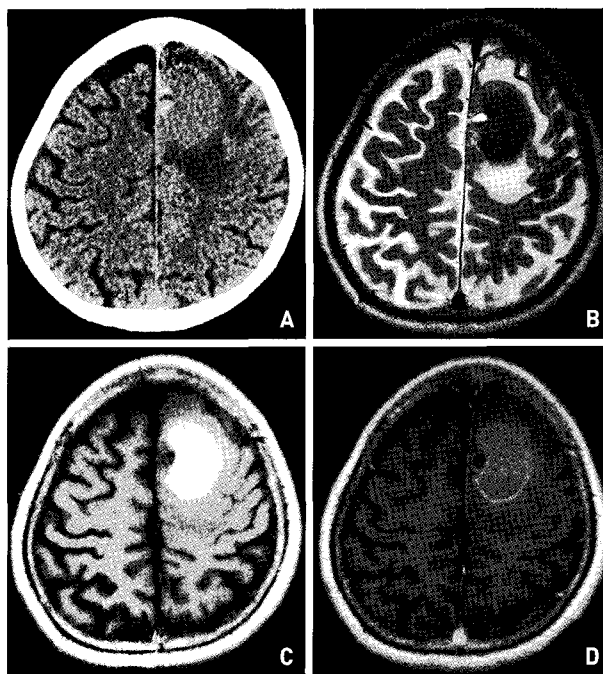


Fig. 1. A : Non-contrast computerized tomography of the brain demonstrating a cystic mass with a nodule in the left frontal lobe. The isodense cystic fluid and perilesional edema are also noted. B, C : T2 & T1-weighted axial magnetic resonance image showing a large cyst with high signal intensity on T1-weighted image and low signal intensity on T2-weighted image and fluid-fluid level within the mural nodule. D : Gadolinium-enhanced axial magnetic resonance image showing the rim enhancement of the nodule and the cyst.

• Received : June 1, 2007
• Accepted : August 10, 2007
• Address for reprints :
Keun-Tae Cho, M.D.
Department of Neurosurgery
Dongguk University International
Hospital, 814 Siksa-dong
Ilsandong-gu, Goyang 410-773, Korea
Tel : +82-31-961-7322
Fax : +82-31-961-7327
E-mail : ktcho21@naver.com

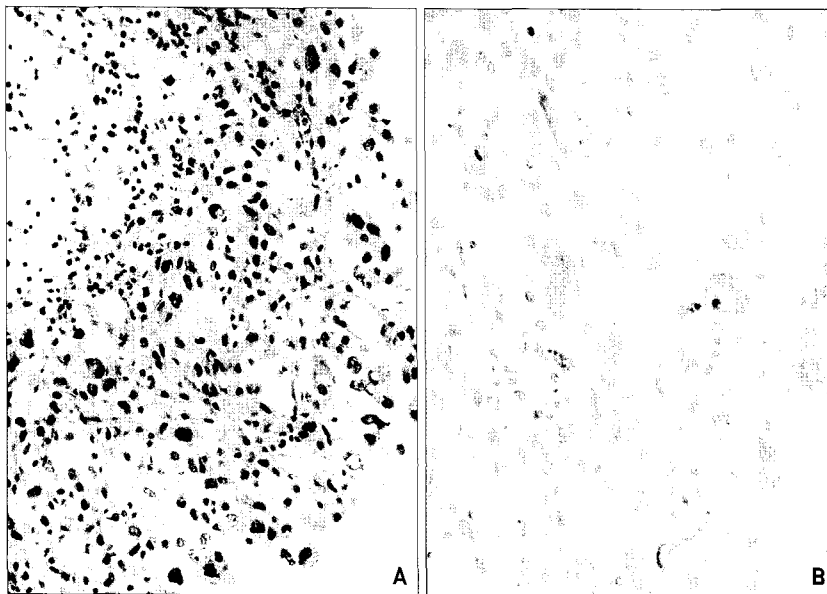


Fig. 2. A (H&E, $\times 200$): Large tumor cells showing nuclear and cytoplasmic pleomorphism and xanthomatous change in the background of reactive gliosis, collections of hemosiderin-laden macrophages and lymphocytic infiltration. B ($\times 400$): Positive glial fibrillary acidic protein immunostaining in large pleomorphic tumor cells.

Table 1. Reported bleeding episodes of PXA in the literature

Authors	Sex/ Age	Site	Primary/ Recurrence	Associated Cyst	Anaplastic feature	Outcome
Giannini, et al. ²⁾						
Case 1	F/52	N/S	R	N/S	-	Death
Case 2	M/21	N/S	R	N/S	+	Death
Levy, et al. ⁸⁾	F/46	Lt. T	P	-	-	Death
Yoshida, et al. ¹¹⁾	F/61	Lt. F-T	P	+	-	Improved

F: female, M: male, Lt: left, T: temporal, F: frontal, R: recurrence, P: primary, N/S: not stated

and magnetic resonance (MR) imaging of the brain revealed a large cystic mass, approximately 4 cm in diameter, with a mural nodule in the left frontal lobe. The mural nodule and the cyst wall were slightly enhancing, and the nodule was contacting the falx cerebri at the medial portion. Interestingly, there was fluid-fluid level inside the nodule, possibly meaning the evidence of bleeding (Fig. 1). Using navigation system (*Stryker Cor. Kalamazoo, MI, USA*), left frontal craniotomy was performed and a greenish yellow cortex was exposed. When the cortical surface was incised, a large amount of old blood was gushed out and a greenish mural nodule was found on the medial side of the cyst. The nodule was soft, poorly vascularized, and readily removed. When it was resected, small amount of xanthochromic fluid was drained. Histopathological examination and immunohistochemical staining showed the finding consistent with PXA (Fig. 2).

DISCUSSION

PXA is a rare brain tumor, accounting less than 1% of astrocytomas⁷⁾. Patients usually present in the second to

third decade of life, with a mean age of 20 to 26 years. Although there have been case reports on PXA of the cerebellum, spinal cord, or intrasellar area, the majority are located in the supratentorial and hemispheric area^{1,2,4,5,9,10)}. In this case, occurrence in old age is unusual.

Although well-defined enhancement of the tumor or nodule and the cystic component can be frequently seen in PXA, it is a typical hypovascular mass on angiography, and the histological hypervascularity has not been reported¹¹⁾. Therefore, the symptomatic hemorrhage from this tumor is exceedingly rare, and the cause is unclear. To the authors' knowledge, only four cases with intracranial or intratumoral bleeding have been reported up to date, and summarized in Table 1^{2,8,11)}. Levy, et al. hypothesized that the meningeal involvement by the tumor eventually produced erosion of the cortical artery, and caused intraparenchymal and subarachnoid hemorrhage. Thin-walled tumor vessel was also thought to be contributory to the bleeding⁸⁾. In the two hemorrhage cases of Giannini, et al, both the bleedings occurred in recurred cases, although the cause was not stated. Interestingly, one case had the histological sign of anaplasia, showing high mitotic index²⁾. Yoshida, et al proposed that unknown microscopic vascular anomaly within the tumor might be responsible for such a massive tumoral hemorrhage¹¹⁾.

In the present case, the evidence of bleeding inside the mural nodule was noted, showing fluid-fluid level in MR image. The bleeding within the cyst might be related with the hemorrhage of the nodule. Some hemangioma or vascular malformation near or in the cyst wall may cause intracystic hemorrhage³⁾. In this case, however, no such lesions were found on histological examination and there was no histological hypervascularity. The authors assumed that bleeding within the nodule might be caused by the ischemic necrosis caused by transient or sustained hypoperfusion during the growth of the nodule. Episodes of increased intra-tumoral pressure by coughing or sneezing may also cause a transient reduction in blood flow and hemorrhage of the mural nodule may occur as a result of reperfusion after the ischemic necrosis.

In the present case, the evidence of bleeding inside the mural nodule was noted, showing fluid-fluid level in MR image. The bleeding within the cyst might be related with the hemorrhage of the nodule. Some hemangioma or vascular malformation near or in the cyst wall may cause intracystic hemorrhage³⁾. In this case, however, no such lesions were found on histological examination and there was no histological hypervascularity. The authors assumed that bleeding within the nodule might be caused by the ischemic necrosis caused by transient or sustained hypoperfusion during the growth of the nodule. Episodes of increased intra-tumoral pressure by coughing or sneezing may also cause a transient reduction in blood flow and hemorrhage of the mural nodule may occur as a result of reperfusion after the ischemic necrosis.

CONCLUSION

It is suggested that PXA could be presented with hemorrhage, causing a rapid neurological deterioration. Prompt surgical

intervention, especially total removal of the tumor can provide an excellent functional recovery.

References

1. Arita K, Kurisu K, Tominaga A, Sugiyama K, Sumida M, Hirose T : Intracellular pleomorphic xanthoastrocytoma : case report. *Neurosurgery* 51 : 1079-1082, 2002
2. Giannini C, Scheithauer BW, Burger PC, Brat DJ, Wollan PC, Lach B, et al : Pleomorphic xanthoastrocytoma : what do we really know about it? *Cancer* 85 : 2033-2045, 1999
3. Hagiwara A, Inoue Y, Shutoh T, Kinoshita H, Wakasa K : Haemorrhagic hepatic cyst : a differential diagnosis of cystic tumour. *Br J Radiol* 74 : 270-272, 2001
4. Herpers MJ, Freling G, Beuls EA : Pleomorphic xanthoastrocytoma in the spinal cord. Case report. *J Neurosurg* 80 : 564-569, 1994
5. Jo JY, Yang SM, Min BK, Kwon JT, Suk JS : Pleomorphic Xanthoastrocytoma : Report of 3 Cases. *J Korean Neurosurg Soc* 31 : 166-169, 2002
6. Kepes JJ : Pleomorphic xanthoastrocytoma : the birth of a diagnosis and a concept. *Brain Pathol* 3 : 269-274, 1993
7. Kepes JJ, Rubinstein LJ, Eng LF : Pleomorphic xanthoastrocytoma : a distinctive meningocerebral glioma of young subjects with relatively favorable prognosis. A study of 12 cases. *Cancer* 44 : 1839-1852, 1979
8. Levy RA, Allen R, McKeever P : Pleomorphic xanthoastrocytoma presenting with massive intracranial hemorrhage. *AJNR* 17 : 154-156, 1996
9. Lindboe CF, Cappelen J, Kepes JJ : Pleomorphic xanthoastrocytoma as a component of a cerebellar ganglioglioma : case report. *Neurosurgery* 31 : 353-355, 1992
10. Lipper MH, Eberhard DA, Phillips CD, Vezina LG, Cail WS : Pleomorphic xanthoastrocytoma, a distinctive astroglial tumor : neuroradiologic and pathologic features. *AJNR* 14 : 1397-1404, 1993
11. Yoshida D, Kogiku M, Noha M, Takahashi H, Teramoto A : A case of pleomorphic xanthoastrocytoma presenting with massive tumoral hemorrhage. *J Neurooncol* 71 : 169-171, 2005