

## Case Report

Hyung Sub Kim, M.D.

Jin Woo Hur, M.D.

Jong Won Lee, M.D.

Hyun Koo Lee, M.D.

Department of Neurosurgery  
Cheongju St. Mary's Hospital  
Cheongju, Korea

## Extraordinarily Long-Term Posttraumatic Cerebrospinal Fluid Fistula

Most posttraumatic cerebrospinal fluid (CSF) leakage is noticed by the patients with the first symptom, rhinorrhea. A 38-year-old woman presented with frequent clear continuous rhinorrhea and otorrhea for 5 years after basilar skull fracture. After this, meningitis was developed with subsequent CSF fistula. Her clinical symptom was improved by medical treatment. The dural defect and CSF leakage were not detected by computerized tomography (CT) cisternography. We report a rare case of persistent posttraumatic CSF fistula that continued for five years.

**KEY WORDS :** Traumatic CSF fistula · Meningitis · CT cisternography.

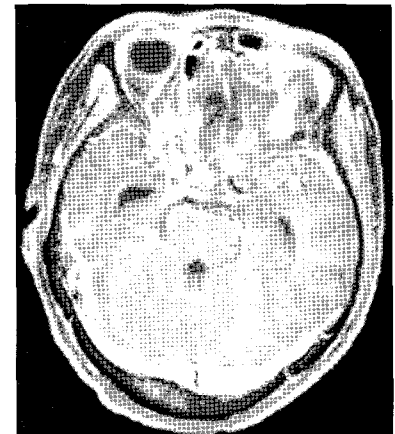
### INTRODUCTION

Most of posttraumatic CSF leakage resolves within six months after trauma. CSF fistula should be closely evaluated because of fatal complication. CSF leakage is the first symptom usually noticed by the patients. Therefore, it can usually be diagnosed before the development of meningitis as its complication. We experienced a case of posttraumatic CSF leakage that persisted for 5 years in undiagnosed state that resulted in meningitis.

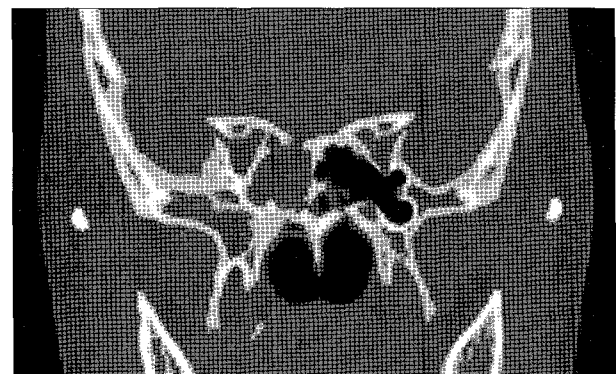### CASE REPORT

A 38-year-old woman visited emergency room for suddenly developed drowsy mentality, confusion, irritability and fever. Medical history showed she had cerebral contusion and basal skull fracture caused by traffic accident 5 years ago. She have experienced frequent morning watery fluid rhinorrhea since that trauma. But, she has not been received any special study for evaluation of clear rhinorrhea. Brain magnetic resonance imaging (MRI) at our hospital showed diffuse meningeal enhancement and encephalomalatic change on both frontal lobes (Fig. 1).

Ostiomeatal unit CT revealed defect of sphenoid sinus (Fig. 2). Lumbar spinal tapping was done that identified bacterial meningitis with *Streptococcus pneumoniae*. She was treated with medical treatment including antibiotics and showed a good response. On her 20th hospital stay, her consciousness was aggravated to a deep drowsy and brain CT showed a mild hydrocephalus (Fig. 3). Bilateral ventriculostomy was done and her consciousness was improved. Shunt operation was not performed at that time. CSF leakage was no longer seen. We

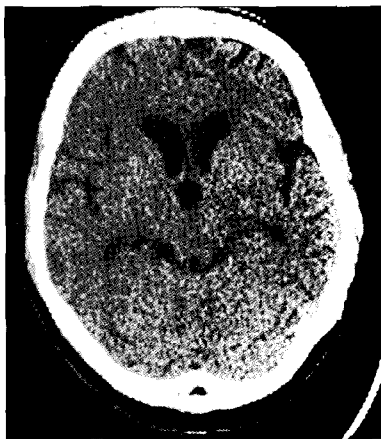


**Fig. 1.** Initial brain magnetic resonance imaging showing diffuse meningeal enhancement and encephalomalatic change on frontal lobe.

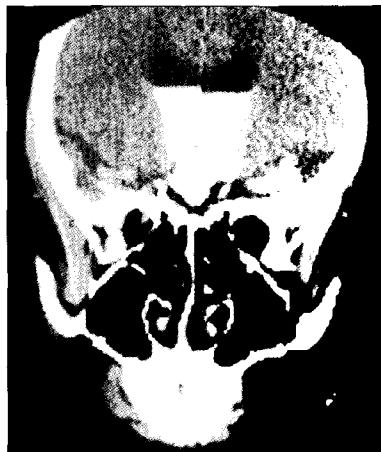

**Fig. 2.** Ostiomeatal unit computerized tomography revealing defect of sphenoid sinus.

- Received : May 28, 2007
- Accepted : September 7, 2007
- Address for reprints :  
Jin Woo Hur, M.D.  
Department of Neurosurgery  
Cheongju St. Mary's Hospital  
589-5 Jujung-dong, Sangdang-gu  
Cheongju 360-568, Korea  
Tel : +82-43-219-8152  
Fax : +82-43-211-7925  
E-mail : somalh@nate.com



**Fig. 3.** Brain computerized tomography revealing mild hydrocephalus.



**Fig. 4.** Computerized tomography cisternography does not indicate the site of cerebrospinal fluid leakage.

planned a surgery for dural defect closure after eradication of meningitis. But, leakage was stopped after improvement of meningitis. On 63th hospital day, she was discharged in neurologically free state. We have checked CT cisternography at out-patient department and the definite CSF leakage site was not detected (Fig. 4).

### DISCUSSION

CSF fistula occurs in 2-3% among patients with head injury, 60% of CSF fistula occurs within days of trauma, and 95% within 3 months<sup>27</sup>. At least 85% of posttraumatic CSF leak cases are of the posttraumatic

rhinorrhea and almost all cases of posttraumatic rhinorrhea will stop on their own within 1 week<sup>25</sup>. However, delayed CSF leakages may rarely occur after a few years<sup>19,23</sup>. There was one reported case in Korean literature : long-term delayed case of a 14-year-old girl with pneumococcal meningitis complicated by CSF rhinorrhea following an asymptomatic period of 3 years after head trauma<sup>12</sup>.

Posttraumatic formation of a dural scar prevents leakage of CSF but does not always provide a sufficient barrier against bacteria present in the paranasal sinuses<sup>23</sup>. As a result of atrophy of the tissue at the site of the dural lesion and microtrauma, CSF rhinorrhea can develop many years later<sup>19</sup>. Dural lesion can act as a portal of entry for bacteria present in the paranasal sinuses<sup>23</sup>. If the leaking sites are unidentified prior to attempted surgical treatment, 30% develop to a recurrent leak post-operation, with 5-15% of these developing meningitis before leak stops<sup>18</sup>.

Meningitis may promote inflammatory changes at the site of the leak, with a resultant cessation of the leak<sup>17</sup>. Streptococcus

pneumoniae is the most common pathogen (80-83% of cases)<sup>9,14</sup>. Pneumococcal meningitis, arising primarily from the upper airways, has the worst prognosis<sup>10</sup>. In the series reported by neither the conservative nor neurosurgical treatment guaranteed the prevention of meningitis. One could theorize several explanations for this finding : underdiagnosis of single or multiple CSF fistula, the lack of adequate separation of the cranial cavity and sphenonasotrachea, the development of posttraumatic hydrocephalus and altered paranasal sinus drainage<sup>16</sup>.

Spontaneous healing or the use of free grafts and/or vascularized flaps form an adequate barrier to separate the sinonasal tract and arachnoid space under normal circumstances. However, it remains as a weak point that may be transgressed if the patient develops posttraumatic hydrocephalus or infection in a paranasal sinus adjacent to the defect<sup>16</sup>.

At sites where the brain is in close contact with the skull base-in the region of the ethmoid bone, for example-leakage of CSF is rare even immediately after the trauma as the brain often tamponades the dural defect. In the region of the sphenoid cavity, on the other hand, there is often intensive leakage of CSF after a dural lesion as it is surrounded by large basal cisterns<sup>24</sup>.

To localize site of CSF fistula, CT cisternography was mentioned as the method that permits the most precise location of a dural lesion<sup>11</sup>. However, even with CT cisternography detection the location of a CSF fistula is not possible in all cases. Colquhoun's study was able to identify the site of the CSF leak in 17 of 21 (81%) CT cisternographies in 18 consecutive patients with CSF rhinorrhea<sup>3</sup>. Moreover, the preoperatively described site of the dural lesion does not always agree with the intraoperative findings<sup>6</sup>.

The ability to detect and to locate a CSF fistula by using contrast media depends from a general point of view on whether there is an active or inactive CSF leak present at the time of examination. Eljamel et al enumerated the success rate of CT cisternography reaching 92% in active and 40% in inactive CSF leaks<sup>5</sup>. However, MR cisternography have a much higher detection sensitivity for CSF fistulae than the comparable CT method where small dural defects (<2 mm<sup>2</sup>) are involved. Therefore, a clear relationship exists between the surgically confirmed size of a dural defect and the sensitivity in detecting a CSF fistula nearby<sup>13</sup>.

Loew et al and Cairns advised that all CSF fistulae should be treated surgically as soon as possible<sup>2,8,15</sup>. But, conservative treatment is initially recommended. The rationale of this suggestion is based on the observation that 50% to 85% of traumatic CSF fistulae occurring within 48 hours after injury cease spontaneously<sup>8,21</sup>. But, spontaneous cessation of CSF leakage does not guarantee that the dural tear is

definitely sealed, and recurrent rhinorrhea or late intracranial infections may develop<sup>4,20</sup>). Delayed or recurrent CSF rhinorrhea almost never stop without operative treatment. This is supported by recent studies showing that if a dural repair is undertaken, the risk of meningitis occurring within 10 years is reduced from 85% to 7%<sup>4</sup>).

Presence of encephalocele or meningocele is associated with high risk of recurring meningitis (arising from sinus bacteria). Also, because the herniated brain into osteodural defect keeps the defect open, the natural healing of the dural defect is prevented. For these reasons, encephalocele or meningocele indicates the absolute need for dural repair, even if CSF leakage is not observed<sup>7</sup>). When rhinorrhea persists for more than 8 days, it should be treated surgically<sup>22</sup>).

Surgical CSF leak repair may be performed transcranially or extracranially. Posttraumatic CSF otorrhea or rhinorrhea secondary to basilar skull fracture can be successfully treated by lumbar drainage alone. Findler et al reported in 1977, 14 patients with posttraumatic CSF rhinorrhea treated initially with lumbar drainage alone for an average of 8 days<sup>26</sup>). In those patients who experienced leaking within 48 hours, the drain was successful in 8 of 9 cases<sup>26</sup>).

## CONCLUSION

Most posttraumatic leakage may stop without surgical management. But, some delayed or long-term continuous CSF leakage should be closely followed up and be needed further evaluation or management because of possibility of developing life threatening meningitis.

## References

- Cairns H : Injuries of the frontal and ethmoidal sinuses with special reference to cerebrospinal rhinorrhea and aroceles. *J Laryngol Otol* 52 : 589-623, 1937
- Coquhoun IR : CT cisternography in the investigation of cerebrospinal fluid rhinorrhoea. *Clin Radiol* 47 : 403-408, 1993
- Dietrich U, Feldges A, Sievers K, Kochs W : Lokalisation von frontobasalen traumatischen Liquorfisteln. *Zentralbl Neurochir* 54 : 24-31, 1993
- El Gammal T, Sobol W, Wadlington VR, Sillers MJ, Erews C, Fisher WS 3rd, et al : Cerebrospinal fluid fistula : detection with MR cisternography. *AJNR Am J Neuroradiol* 19 : 627-631, 1998
- Eljamel MS : The role of surgery and h2-transferrin in the management of CSF fistulas. *MD thesis, Liverpool*, 1993, pp207-219
- Eljamel MS, Pidgeon CN, Toland J, Philips JB, O'Dwyer AJ : MRI cisternography, and the localization of CSF fistulae. *Br J Neurosurg* 8 : 433-437, 1994
- Griffith HB : CSF fistula and surgeon. *Br J Neurosurg* 4 : 369-371, 1990
- Hand WL, Sanford JP : Posttraumatic bacterial meningitis. *Ann Int Medicine* 72 : 869-874, 1970
- Hoen B, Viel JF, Gerad A, Dureux JB, Canton P : Mortality in pneumococcal meningitis : A multivariate analysis of prognostic factors. *Eur J Med* 2 : 28-32, 1993
- Horch HH, Grafm-von-Einsiedel H, Goebel WE : Diagnosis of cerebrospinal fluid fistula in frontobasal fractures using iotrolan CT-cisternography. *Fortschr Kiefer Gesichtschir* 36 : 133-136, 1991
- K E W Eberhardt, H P Hollenbach, M Deimling, B F Tomandl, W J Huk : MR cisternography : a new method for the diagnosis of CSF fistulae. *European Radiol* 7, 1485-1491, 1997
- Kim EJ : A Case of Pneumococcal Meningitis Associated with Posttraumatic Cerebrospinal Fluid Rhinorrhea. *J Korean Child Neurol Soc.* 14, 358-352, 2006
- Lackmann GM, Isenberg H, Tollner U, Draf W, Bohm HJ : Aneurysmale Knochenzyste des Felsenbein. *Monatschr Kinderheilkd* 141 : 855-859, 1993
- Loew F, Pertuiset B, Chaumier EE : Traumatic spontaneous and postoperative CSF rhinorrhea. In : Synmon L, editor. *Advances and technical standard in neurosurgery*, vol 11. Wien : Springer, 1984, pp. 169-207
- Manuel Bernal-Sprekelsen, Carmen Bleda-Vazquez, Ricardo L Carrau : Ascending Meningitis Secondary to Traumatic Cerebrospinal Fluid Leaks. *American journal of rhinology* 14 : 257-259, 2000
- Greenberg MS : CSF fistula : *handbook of neurosurgery 6th edition*, 10.4
- Naidich TP, Moran CJ : Precise anatomic localization of atraumatic sphenoidal CSF rhinorrhea by metrizamide CT cisternography. *J Neurosurg* 53 : 222-228, 1980
- Okada J, Tsuda T, Takasugi S, Nishida K, Toth Z, Matsumoto K : Unusually late onset of cerebrospinal fluid rhinorrhea after head trauma. *Surg Neurol* 35 : 213-217, 1991
- Passagia JG, Chirossel JP, Favre JJ : Surgical approaches to the anterior fossa and preservation of olfaction. In : Cohadon F, editor. *Advances and technical standard in neurosurgery*, Vol. 25. Wein, Springer; 1999, pp197- 241
- Rocchi G, Caroli E, Belli E, Salvati M, Cimatti M, Delfini R : Severe craniofacial fractures with frontobasal involvement and cerebrospinal fluid fistula : indications for surgical repair. *Surgical Neurology* 63 : 559-564, 2005
- Sakas DE, Beale DJ, Ameen AA : Compound anterior cranial base fractures : classification using computerized tomography scanning as a basis for selection of patients for dural repair. *J Neurosurg* 88 : 471- 477, 1998
- Samii M, Draf W : Surgery of the Skull Base. *An Interdisciplinary Approach*. New York : Springer 1989
- Schick B, Weber R, Kahle G, Draf W, Lackmann GM : Late manifestations of traumatic lesions of the anterior skull base. *Skull Base Surg* 7 : 77-83, 1997
- Shapiro SA, Scully T : Closed continuous drainage of cerebrospinal fluid via a lumbar subarachnoid catheter for treatment or prevention of cranial/spinal cerebrospinal fluid fistula. *Neurosurgery* 30 : 241-245, 1992
- Shapiro SA, Scully T : Department of Surgery, Indiana University Medical Center, Indianapolis. : Closed continuous drainage of cerebrospinal fluid via a lumbar subarachnoid catheter for treatment or prevention of cranial/spinal cerebrospinal fluid fistula. *Neurosurgery* 30 : 241-245, 1992
- Spezler RF, Zabramski JM : Cerebrospinal fluid fistula. *Contemp Neurosurg* 8 : 1-7, 1986
- Talamonti G, Fontana R, Villa F : bHigh riskQ anterior basal skull fractures. Surgical treatment of 64 consecutive cases. *J Neurosurg Sci* 39 : 191-197, 1995