

## Clinical Article

Young Jae Lee, M.D.

Jae Woo Kim, M.D.

Ik Soo Kim, M.D.

Myung Ki Lee, M.D.

Chang Ghue Ghang, M.D.

Young Woo Lee, M.D.

Department of Neurosurgery  
Bong Seng Memorial Hospital  
Busan, Korea

# Lateral Third Infraclavicular Implantation of the Vagal Nerve Stimulation Generator Through Axillary Incision

**Objective :** This report describes the clinical study of the surgical method of lateral third infraclavicular implantation of vagal nerve stimulation (VNS) generator through the axillary wrinkle incision.

**Methods :** In a retrospective study, the data for 20 patients with medically intractable epilepsy treated by this approach were examined. The mean age was 31.4 years (range : 14-50), and the mean follow-up period was 12.15 months (range : 4-21 months). The male to female ratio was 2.3 : 1. The subcutaneous pocket for the generator was located in the lateral third infraclavicular area through the axillary wrinkle. Our method was a modification of the standard VNS generator implantation in the mid-infraclavicular pocket through anterior axillary incision.

**Results :** There were the excellent or good cosmetic satisfaction in 95% of the cases and fair in 5%. The generator was located outside the lung field in 15%, periphery of the lung field in 45%, and crossed over the lung field in 40%. Discomfort from shoulder motion occurred transiently in 35% of cases. Other complications were minimal.

**Conclusion :** These results demonstrate that the lateral third infraclavicular approach will offers cosmetic benefits and reduction of obscuration of the lung field without serious complications. Thus, this technique provides an attractive alternative among the surgical techniques for the vagal nerve stimulation.

**KEY WORDS :** Vagal nerve stimulation · Infraclavicular approach · Lateral.

## INTRODUCTION

Vagal nerve stimulation (VNS) has become a popular procedure after FDA approved for the treatment of medically intractable seizure<sup>1-4,6</sup>. VNS generator is typically implanted in the subcutaneous pocket of the left mid-infraclavicular region through the anterior axillary incision<sup>1-3</sup>. However, this procedure has been associated with several problems, such as unsatisfactory cosmetic results due to visible scar and superficial protrusion of generator, migration of the generator and obscuration of the lung field by the generator. We report an alternative generator implantation method that could reduce the described drawbacks.

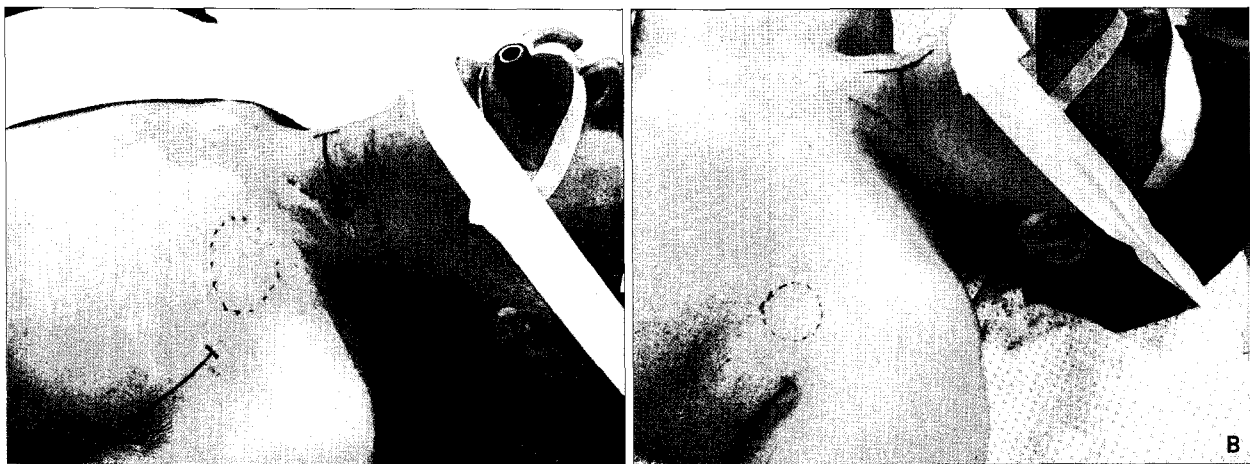
## MATERIALS AND METHODS

From 2001 to 2006, 21 patients underwent VNS operation performed by one operator for medically intractable epilepsy. One patient had the VNS generator implanted at the left mid-infraclavicular subcutaneous pocket through anterior axillary incision, and the other 20 patients had this operation through the left lateral third infraclavicular subcutaneous pocket through an incision along the natural axillary wrinkle line. To clarify the usefulness of this procedure, we have studied these series retrospectively, and evaluated several items, including postoperative cosmetic satisfaction, the obscuration of the lung field by follow-up chest X-ray, complications related to the procedure (infection, hematoma formation, discomfort of shoulder motion, other neurological deficit, migration of generator, lead fracture), and other stimulation induced symptoms such as coughing, hoarseness, vocal cord paralysis, chest pain, bradycardia, asystole, and dysphagia.

### The surgical procedure

The basic procedure is the same as the standard method<sup>1</sup> except that the authors used normal axillary wrinkle line instead of anterior axillary incision and the generator was placed

- Received : February 23, 2007
- Accepted : June 25, 2007
- Address for reprints :  
Chang Ghue Ghang, M.D.  
Department of Neurosurgery  
Bong Seng Memorial Hospital  
68-11 Jwacheon-dong, Dong-gu  
Busan 601-050, Korea  
Tel : +82-51-664-4101  
Fax : +82-51-631-8054  
E-mail : drghang@chol.com



**Fig. 1.** Implantation of vagal nerve stimulation generator. A : middle third infraclavicular implantation through anterior axillary line. B : lateral third infraclavicular implantation through natural axillary wrinkle.

**Table 1.** Characteristics of 20 patients

No.	Sex	Age	Operation date	F/U (M)
1	M	14	2005. 09. 08	16
2	M	16	2006. 03. 16	10
3	M	17	2006. 09. 12	4
4	F	18	2005. 09. 22	16
5	M	20	2006. 07. 31	6
6	F	20	2006. 07. 10	6
7	M	23	2006. 08. 18	5
8	M	25	2005. 04. 21	21
9	M	27	2006. 09. 19	4
10	M	29	2005. 06. 28	19
11	M	34	2005. 08. 25	17
12	F	34	2006. 08. 29	17
13	M	35	2006. 03. 27	10
14	M	43	2005. 06. 03	19
15	F	44	2006. 08. 24	5
16	F	44	2006. 07. 27	6
17	F	47	2005. 05. 30	20
18	M	49	2005. 11. 28	14
19	M	49	2005. 07. 15	18
20	M	50	2006. 03. 13	10

\* abbreviation, No : number, F/U : follow up, M : month

more to the lateral and upward of the subcutaneous pocket (Fig. 1). The average operation time was 50 minutes.

#### Cosmetic satisfaction

All patients were asked about their cosmetic satisfaction, especially invisible scar and superficial protruding of generator at 1 and 2 months after surgery. Their responses were divided into 4 categories : excellent ; very satisfied, good ; relatively satisfied, fair ; relatively unsatisfied, poor ; very unsatisfied.

#### Migration of generator and chest obscuration

The migration of the generator was estimated by a follow-up chest x-ray.

The chest obscuration was evaluated by 4 grades : grade 1 ; out of lung field, grade 2 ; cross over lung field, grade 3 ; periphery of lung field, grade 4 ; near the hilum.

#### Other complications related to the procedure and stimulation induced symptoms

The authors investigated the occurrence of hematoma formation, infection and the discomfort during the shoulder motion. And other stimulation induced symptoms such as coughing, hoarseness, vocal cord paralysis, chest pain, bradycardia, asystole, and dysphagia were also investigated.

## RESULTS

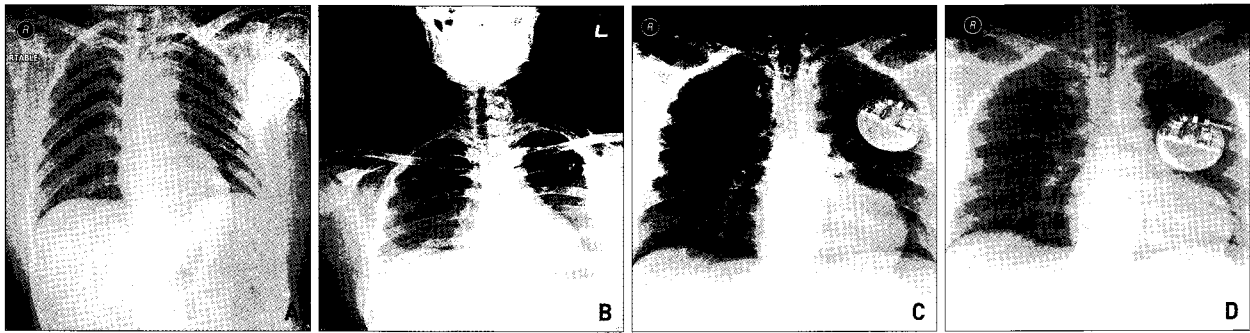
In the 20 cases of VNS generator implantation through the left lateral third infraclavicular subcutaneous pocket through axillary incision, male to female ratio was 2.33 to 1 (14:6), the mean age was 31.4 years (range : 14-50), and the average follow up period was 12.15 months (range : 4-21 months) (Table 1).

#### Cosmetic satisfaction

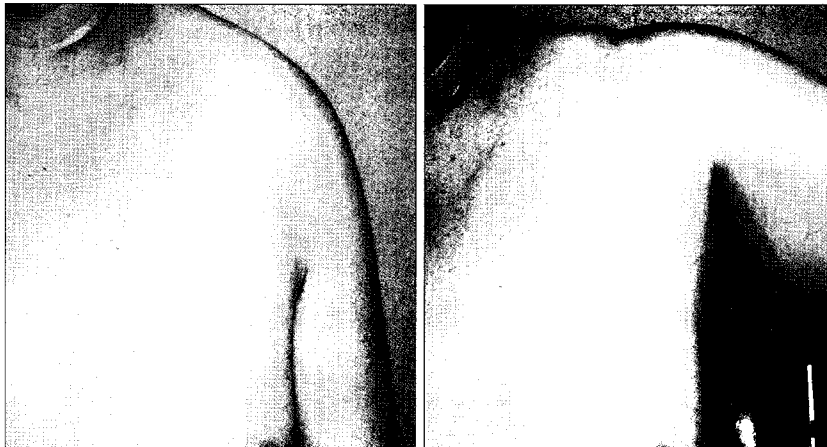
In the postoperative cosmetic satisfaction, the results showed: excellent, 5 cases (25%), good, 11 cases (55%), fair, 4 cases (20%) at a 1 month follow-up. At a 2 month follow-up, results showed : excellent, 7 cases (35%), good, 12 (60%), fair, 1 (5%) (Table 2). In one fair case, superficial protrusion of the lead at the cervical area was identified as being a cause by the technical error of anchoring to the cervical muscle layer. However, 95% of the patients were satisfied with our method after 2 month follow-up.

#### Migration of generator and chest obscuration

Generator migration from the initial anchoring site of



**Fig. 2.** The locations of generator in postoperative evaluation of chest x-rays. A : out of the lung field. B : cross over the lung field. C : periphery of the lung field. D : near the hilum of the lung field.



**Fig. 3.** Postoperative incision site (at a 2 month follow up). A : adduction state. B : abduction state.

**Table 2.** Postoperative cosmetic satisfaction

Result	1 month	2 month
excellent	5 (25%)	7 (35%)
good	11 (55%)	12 (60%)
fair	4 (20%)	1 (5%)
poor	-	-

\* excellent : very satisfied, good : relatively satisfied, fair : relatively unsatisfied, poor : very unsatisfied

**Table 3.** Assessment of Complications

Assessment	Number
Stimulation induced symptom	0/20 ( 0%)
Procedure related complication	0/20 ( 0%)
Migration of generator	3/20 (15%)

more than 2cm was identified in 3 cases but the distance was less than 4cm. The results of chest obscuration are as follows : 1) out of lung field ; 3 (15%), 2) cross over lung field ;11 (55%), 3) periphery of lung field ; 6 (30%), 4) near the hilum ; 0 (0%) (Fig. 2).

**Other complications**

Stimulation induced symptoms and complications related to procedure Stimulation induced symptoms and

complications related to procedure were not noticed. Mild discomfort during shoulder motion was identified early in the postoperative period (7 cases, 35%) but it subsided within 1 month (Table 3).

**DISCUSSION**

Authors have sought an alternative technique to provide better results of VNS generator implantation for cosmetic satisfaction, and to reduce the obscuration of the lung field in chest studies. An alternative method

was sought, as the first case, which operated in the same way as the standard method, revealed several problems. These included a postoperative wound scar that was of cosmetically ill appearance, especially in young woman, and the generator obscuring hilar area of the lung, which is the prevalent area where the lung lesions in chest x-rays occur. Other methods of VNS generator implantation were introduced such as subpectoral implantation<sup>5)</sup>, and interscapular placement<sup>9)</sup> of VNS generator. Subpectoral implantation has the advantages where the migration of generator is less and generator appears less bulky. Interscapular implantation can reduce the wound breakdown related to the wound tampering by the patient especially in children and developmentally disabled adults. But, these procedures cause relatively large scar formations and the obscuration of the lung field. In this regard, we designed a modified method which could create better cosmetic results, reduce the obscuration of the lung field in chest evaluations, without causing other complications.

An incision is made at the axillary fossa along the natural wrinkle line and the generator is implanted at the lateral third infraclavicular subcutaneous pocket. The axillary wrinkle incision can make a less obvious postoperative wound scar,

and the lateral third infraclavicular subcutaneous pocket has relatively thick soft tissue, which could reduce the superficial protruding of the generator (Fig. 3). This location also caused less obscuration of the lung field. However, there is the possibility of discomfort during the shoulder motion and peripheral nerve dysfunction because its location is in the vicinity of the shoulder joint. Seven patients felt discomfort during the shoulder motion in the early postoperative period, but it disappeared as patients became adapted. Other complications related to the procedure (hematoma formation, infection<sup>6,8,10</sup>, lead fracture<sup>10</sup>) were also worrying possibilities because the subcutaneous soft tissue is thicker here, but were not noticed in our cases.

The migration of the generator more than 2 cm occurred in 3 cases, but were not severe. We consider this result was acceptable because the conditions of taking chest x-rays might not be the same. This problem was improved by anchoring the generator to the subcutaneous infraclavicular pocket properly and by dissecting the subcutaneous pocket to small dimension, as needed.

Despite the very lateral position of the generator, it sometimes obscured the lung field in chest x-rays. Even though the generator obscured the lung field, the locations were not near the hilum where many lung lesions occurred, rather were located near the periphery of the lung field. We suggest that it could be better to anchor the generator to the lateral side and upward towards to the infraclavicular pocket as much as possible. Stimulation induced symptoms such as cough, hoarseness<sup>7,10</sup>, bradycardia<sup>4</sup>, asystole, vocal cord paralysis<sup>7</sup> were also not found in this study.

## CONCLUSION

The authors recommend vagal nerve stimulation generator implantation at the lateral third infraclavicular subcutaneous pocket through the axillary incision because of its safety, better cosmetic advantage and less obscuration of the lung field in chest evaluations. This technique provides an attractive alternative among the surgical techniques for the vagal nerve stimulation.

### • Acknowledgement

This topic was presented at the 2006 Annual Autumn Meeting of The Korean Neurosurgical Society.

## References

1. Amar AP, Heck CN, Levy ML, Smith T, DeGiorgio CM, Oviedo S, et al : An institutional experience with cervical vagus nerve trunk stimulation for medically refractory epilepsy : Rationale, technique, and outcome. *Neurosurgery* 43 : 1265-1280, 1998
2. Amar AP, Heck CN, DeGiorgio CM, Apuzzo MLJ : Experience with vagus nerve stimulation for intractable epilepsy : Some questions and answer. *Neurol Med Chir(Tokyo)* 39 : 489-495, 1999
3. Amar AP, Levy ML, McComb JG, Apuzzo MLJ : Vagus nerve stimulation for control of intractable seizures in childhood. *Pediatr Neurosurg* 34 : 218-223, 2001
4. Asconape JJ, Moore DD, Zipes DP, Hartman LM, Duffell WH Jr : Bradycardia and asystole with the use of vagus nerve stimulation for the treatment of epilepsy : A rare complication of intraoperative device testing. *Epilepsia* 40 : 1452-1454, 1999
5. Bauman JA, Ridgway EB, Devinsky O, Doyle WK : Subpectoral Implantation of the Vagus Nerve Stimulator. *Neurosurgery* 58 *Operative Neurosurgery Supplement* 2 : ONS-322-325; discussion 325-326, 2006
6. Binnie CD : Vagus nerve stimulation for epilepsy : A review. *Seizure* 9 : 161-169, 2000
7. Kalkanis JG, Krishna P, Espinosa JA, Naritoku DK : Self-inflicted vocal cord paralysis patient with vagus nerve stimulators. Report of two cases. *J Neurosurg* 96 : 949-951, 2002
8. Kirse DJ, Werle AH, Murphy JV, Bruegger DE, Hornig GW, Torkelson RD : Vagus nerve stimulator implantation in children. *Arch Otolaryngol Head Neck Surg* 128 : 1263-1268, 2002
9. Le H, Chico M, Hecox K, Frim D : Interscapular placement of a vagal nerve stimulator pulse generator for prevention of wound tampering Technical note. *Pediatr Neurosurg* 36 : 164-166, 2002
10. Smyth MD, Tubbs RS, Bebin EM, Grabb PA, Blount JP : Complications of chronic vagus nerve stimulation for epilepsy in children. *J Neurosurg* 99 : 500-503, 2003

## COMMENTARY

This article provides that cosmetic result as well as functional outcome are important in surgery for VNS. The authors used the incision of the normal axillary fold for the pocket for VNS generator to avoid the exposure of the scar. However we have to bear in mind the presence of the subcutaneous tissue of axillary region with abundant venous and lymphatic structures. Dissection of this region should be careful not to injure these structures.

Sometimes, it makes patient discomfort in setting the VNS parameter with wander, in spite of invisible scar. Patients should raise their arm to set the parameters, and the electrical communication between IPG and wander may be interrupted due to thick soft tissue in this region.

It is good try to provide cosmetic satisfaction, I hope that authors deal with clinical outcome in next article.

Ha-Young Choi, M.D.  
Department of Neurosurgery  
Chonbuk National University