

Young-Joon Kwon, M.D.

Department of Neurosurgery
Kangbuk Samsung Hospital
Sungkyunkwan University School
of Medicine, Seoul, Korea

Minimally Invasive Combined Interlaminar and Paraisthmic Approach for Symptomatic Lumbar Foraminal Stenosis : Surgical Technique and Preliminary Results

Objective : Lumbar foraminal stenosis is an important etiology of lumbar radicular symptomatology and frequent causes of remained symptoms after decompressive surgery. This study was conducted to determine the precise clinical and radiologic diagnosis of lumbar foraminal stenosis, and to demonstrate thorough treatment by decompressive surgery using a minimally invasive technique.

Methods : Seven patients with established unilateral lumbar foraminal stenosis according to clinical and radiologic diagnosis were retrospectively studied. All patients underwent combined interlaminar and paraisthmic procedure with partial facetectomy. The outcome of surgery was evaluated and classified into excellent, good, fair and poor.

Results : The results were excellent in four patients, good in two, and fair in one during the follow-up. There were no surgery-related complications.

Conclusion : Minimally invasive combined interlaminar and paraisthmic approach provides good outcome in carefully selected patients with symptomatic lumbar foraminal stenosis.

KEY WORDS : Spinal stenosis · Minimally invasive surgery procedure.

INTRODUCTION

Lumbar spinal stenosis has many etiologies and can be divided anatomically into central and lateral canal stenosis. Lateral canal stenosis is a common cause of lumbar radicular pain. An 8% to 11% incidence of lateral root entrapment has been reported^{9,14,17}. Unrecognized or recurrent foraminal stenosis may be associated with failed back surgery syndrome. In a study of 225 patients with failed back surgery syndrome, the authors attributed it to the lack of recognition or inadequate treatment of nonspecific lateral canal stenosis and considered it as the cause of pain in 56% of patients with continuous postoperative symptoms¹. Therefore, lumbar foraminal stenosis is an important pathological entity to identify in the patient with radicular pain.

Various surgical techniques have been used to decompress the foraminal area of the lumbar spine. In the present study, a minimally invasive transarticular combined lateral and medial approach was performed to decompress and explore affected nerve roots to demonstrate its clinical usefulness in management of symptomatic lumbar spinal stenosis.

MATERIALS AND METHODS

Seven patients with symptomatic foraminal stenosis were retrospectively reviewed from Jan. 2005 through Nov. 2006. Relevant clinical and radiographic features and intraoperative findings were noted and recorded. The study group consisted of three men and four women. Average age was 64.6 years (range, 49-80 years).

As a part of the clinical evaluation, hospital based medical records were reviewed for presenting duration, distribution, intensity of symptoms, and history of previous surgery. Moreover, relevant neurological examinations were evaluated, including the presence or

• Received : February 6, 2007
• Accepted : June 1, 2007
• Address for reprints :
Young-Joon Kwon, M.D.
Department of Neurosurgery
Kangbuk Samsung Hospital
Sungkyunkwan University School of
Medicine, 108 Pyeong-dong
Jongno-gu, Seoul 110-746, Korea
Tel : +82-2-2001-2159
Fax : +82-2-2001-2157
E-mail : neuriac@skku.edu

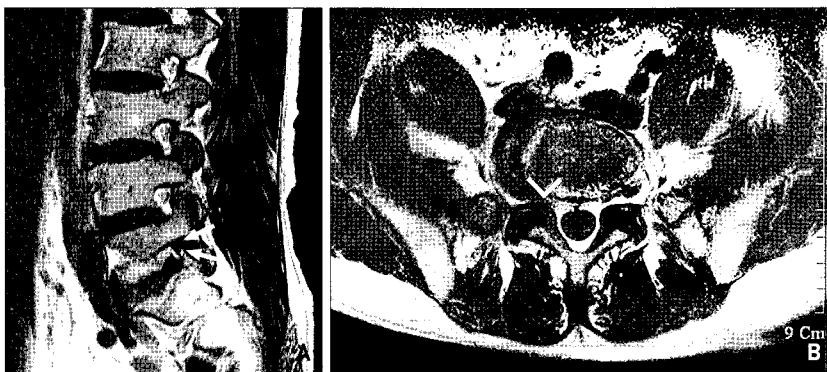

Fig. 1. Magnetic resonance image of a 50-year-old male with right L5 radiculopathy. A : Parasagittal T1-weighted image showing foraminal stenosis with circumferential loss of perineural fat signal at the L5S1 neuroforamen (arrows) compared with intense fat signal at the adjacent levels. B : Axial T1-weighted image revealing diminished sized right L5S1 foramen (arrow head).

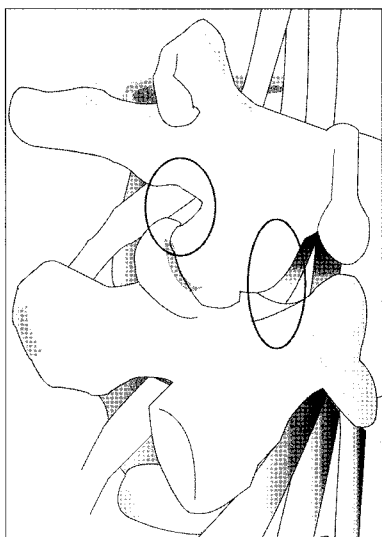


Fig. 2. Amount of bony resection of the minimally invasive combined interlaminar and paraisthmic approach. The circled areas demonstrates the portions of lateral isthmus and lamina needed for this approach.

with flexion and extension views were taken of all patients to check foraminal and posterior disc height. Advanced imaging studies such as computed tomography (CT) and magnetic resonance imaging (MRI) were also taken for evaluating and quantifying the degree of foraminal stenosis. CT scans were performed with reformatted parasagittal images of the foramen. Foraminal narrowing as determined by comparison of the superior or inferior foramen led to a diagnosis of significant foraminal stenosis. The T1 weighted parasagittal and axial MR images were evaluated for the presence of foraminal stenosis. Diminished size of the foramen and absence of epidural fat surrounding the exiting nerve root was considered as evidence of significant stenosis (Fig. 1). Patients with herniated disc were excluded from the study.

Outcome was defined as excellent, good, fair, and poor based on Macnab classification¹²⁾.

absence of a Lasegue sign, deep tendon reflexes, and motor or sensory changes. In addition, the association of central canal stenosis and symptoms of neurogenic claudications were sought. In case of multiple lesions, symptomatic site of foraminal stenosis was determined by thorough neurological examinations and selective foraminal root blocks.

Preoperative lateral lumbar radiographs

interlaminar approach. Dissection along the margin of this fascial flap is bloodless and lateral retraction of erector spinae muscle mass is performed carefully. After Caspar Micro Lumbar Discectomy Retractor or tubular retractor is applied, decompression of the medial part of the foramen is completed using the standard interlaminar approach. After that, lateral paraisthmic approach is performed between the multifidus and the longissimus muscles. Using an operating microscope and a high-speed drill, the superolateral portion of the facet joint and the upper and lateral margin of the interarticular part are drilled away. Direct removal of osteophyte arising from the posterolateral vertebral body is not performed. The amount of facet joint resection should not exceed 50%. Then, the intertransverse ligament is excised to expose the nerve root lateral to the foramen. The affected nerve root is then followed along the neuroforamen. Sufficient nerve root decompression must be carefully confirmed using a foraminal probe. In using this combined approach, it is possible to reach and decompress two nerve roots, if necessary. The superior nerve root is decompressed by removing the superolateral portion of the facet and upper and lateral margin of the interarticularis, and the inferior nerve root is decompressed by removing the medial part of the facet joint and lateral recess (Fig. 2).

RESULTS

Mean duration of leg and back symptoms was 10.3 months and 20.7 months, respectively. All patients complained severe radicular leg pain, and was uniformly exacerbated with lumbar extension to the painful side. Two patients had previous lumbar decompressive surgery and one had bilateral symptoms. On neurological examination, common findings incorporated a limited lumbar range of motion, especially extension. Focal motor weakness in a specific root distribution showed in five patients, Lasegue signs in four, and diminished

Surgical technique

A C-arm fluoroscopy is checked to verify the correct position of the incision. After paramedian 3cm-sized skin incision is performed, the superficial fascia is incised 1.5 cm off the midline ipsilaterally to the site of interest. This produces a fascial flap hinged on the spinous processes encompassing the interlaminar space of interest. This is done in attempt to spare injury to the bulk of the supraspinous and interspinous ligamentous complex.

The first step of operation is medial

Table 1. Summary of data obtained in patients undergoing surgery for symptomatic lumbar foraminal stenosis

Case No.	Age /Sex	Level	Symptoms and signs					Outcome	Follow-up (mo)
			Leg pain	Back pain	Sensory deficit	Motor deficit	Relief from root block		
1	50/M	L5/S1	yes	no	yes	yes	yes	excellent	15
2	49/F	L4/5	yes	yes	no	no	yes	excellent	23
3	74/M	L34/L45	yes	yes	yes	yes	no	good	13
4	62/M	L5/S1	yes	no	yes	no	yes	excellent	11
5	67/F	L34	yes	yes	yes	yes	yes	good	10
6	80/F	L34	yes	no	yes	yes	yes	fair	5
7	70/F	L5/S1	no	yes	yes	yes	yes	excellent	1

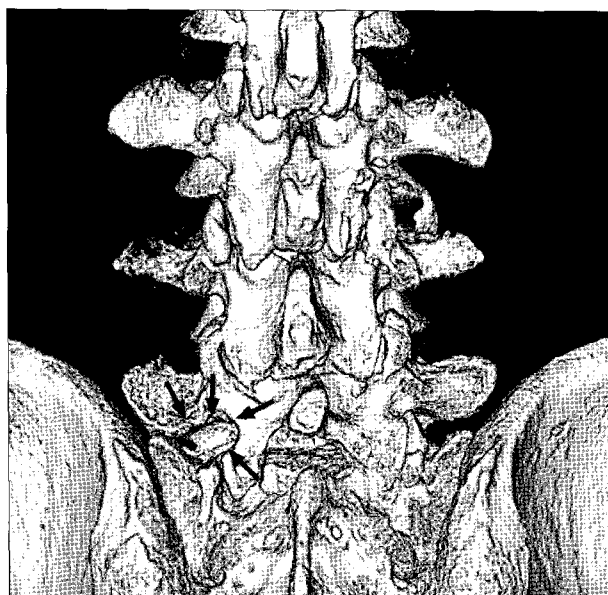


Fig. 3. Postoperative computed tomographic image of a 62-year-old man with severe left leg pain. Three-dimensional reconstruction image shows the bony resected area of lateral isthmus and superolateral portion of facet joint (arrows). A portion of left S1 lamina is also resected.

subjective sensation and reflexes in specific root distributions in six.

In three patients, CT scans demonstrated the presence of bone spurs arising from the posterolateral vertebral body extending slightly into the foramen. The MR imaging studies revealed more unique findings. All patients showed a foramen of diminished size and a paucity of perineural fat surrounding the nerve root on T1-weighted parasagittal images.

The follow-up period ranged from one to 23 months (mean 11.1 months). Outcome based on the Macnab classification were excellent in four patients, good in two, and fair in one (Table 1). There were no surgery-related complications. Plain radiographic lateral views, including flexion-extension films were available for all patients at various follow-up ranging from one to 20 months after the surgery, and no evidence of postoperative spinal instability was found. Postoperative three-dimensional reconstructed CT scanning demonstrated

the preservation of the main portion of the lumbar facet joint (Fig. 3).

DISCUSSION

The etiology of lumbar foraminal stenosis is often multifactorial. As the intervertebral disc loses height secondary to disc degeneration, the superior articular process of the inferior vertebra shifted superiorly and somewhat anteriorly, resulting in narrowing of the intervertebral foramen. Further alteration in facet biomechanical forces contributed to joint degeneration accompanied by hypertrophic changes and subsequent diminishment of neural foramen. Moreover, bulging annuli and hypertrophic changes on the vertebral end plates add to the diminishment of the area available for the exiting nerve root. In addition to these static changes, dynamic changes in the foraminal area, as with extension, might further reduce the reserve space and could lead to root compression. These changes may be a common cause of symptomatic foraminal stenosis, as seen in this study. This concept of dynamic foraminal stenosis has been supported in other studies^{6,13}. Inufusa et al.⁶ have shown that lumbar flexion causes a 12% increase in the foraminal area, whereas extension leads to a 15% decrease in the available area in the study using computed tomography scan and cryomicrotome analyses. This result suggest that lumbar flexion can reduce intervertebral translation, disc bulging, and bulging of a hypertrophied ligamentum flavum, leading to less contact with the nerve root, whereas the converse is found with extension.

The incidence of symptomatic lumbar foraminal stenosis is not known exactly but has been thought to be rare^{9,10}. Kunogi et al.⁹ showed foraminal stenosis was identified in 8% of cases of operated lumbar spinal stenosis. In one series of failed back surgery syndrome, the authors demonstrated that 56% of those who had originally been diagnosed as having a herniated disc were assumed as also having lateral spinal stenosis or as having only lateral spinal stenosis¹. In addition, in a retrospective review of 65 surgical cases of lumbar foraminal stenosis⁸, almost 50% of patients had already undergone previous surgery. However, they could not determined whether their patients showed evidence of foraminal stenosis before the earlier surgery or whether postsurgical changes contributed to later development of significant narrowings in the intervertebral foramen. These results suggest that foraminal stenosis is relatively common and that it should be considered in preoperative planning, especially for repeated surgery group failed to relieve symptoms.

Unfortunately, no single clinical finding leads to the diagnosis of foraminal stenosis, and obvious radiologic imaging evidence is uncommon. Therefore, in addition to thorough physical and neurological examination, the use of selective nerve root block may be of more benefit in the evaluation of radicular pain thought to be secondary to foraminal stenosis^{5,18}.

MRI and CT scans are essential diagnostic tools in the detection of foraminal stenosis. MRI has the advantages of superior resolution, further detection of disc and ligament changes, and lack of radiation. Suggestive MRI findings are reduced size of neural foramen and paucity of epidural fat surrounding the nerve root on T1 weighted parasagittal images. In one series, MRI correlated with the intraoperative finding of foraminal stenosis in 77% of cases⁸. The use of CT scans allow detection of bony encroachment on the zone. In a study of comparison of MRI to CT in the diagnosis of spinal stenosis, the author showed a 98% correlation with MRI in the detection of foraminal stenosis¹⁵. Although the shape of the foramen is not well seen on axial CT images, parasagittal reconstructed images, including bony and soft tissue windows, provide better clarity of the space available for the nerve root and other lesions, such as bony spur arising from vertebral body or facet. In addition, 3-dimensional reformation of the CT images allows preoperative planning and postoperative evaluation of decompression accurately and easily, as in the present study.

Various surgical approaches have been used to reach the foraminal and extra-foraminal lateral area of the lumbar spine. The main approaches for surgical decompression are divided either a midline approach including interlaminar exposure, laminotomy or laminectomy, medial facetectomy, and medial foraminotomy^{7,11} or a muscle splitting lateral approach to the foramen with foraminotomy^{16,19}. Furthermore, a combined approach may be required for complete foraminal decompression⁴.

The midline interlaminar approach is used for cases of associated compressive pathology in the central canal or lateral recess. However, the shortcomings of this medial approach are poor visual control of lateral foramen and the risk of incomplete decompression of the superior nerve root. For the decompression of the superior nerve root from medial side, most of the base of the inferior articular process and main portion of facet joint has to be removed. This bone removal may weaken the base of the articular process and may result in pars fracture and significant postoperative spinal instability, so occasionally posterolateral fusion is required^{2,3,9}. However, it is well known that the fusion may accelerate degenerative process in the adjacent disco-ligamentous structures.

The lateral paraisthmic approach may be used in selected cases of pure foraminal stenosis. Nevertheless, accompanying lesion such as other central or lateral canal pathology cannot be treated. The procedure described here allows for preservation of the major part of the facet joint and complete preservation of extensor muscle and posterior ligamentous structures, provided by minimally invasive procedure. It also provides good access to and visual control of the two nerve roots, as well as the lateral and the medial part of the intervertebral foramen, with minimal risk of nerve root injury. The superior exiting nerve root is decompressed by removing the superolateral portion of the facet joint and the superolateral margin of the interarticularis, and the inferior traversing nerve root is decompressed by removing the medial part of the facet and lateral recess. The preservation of a functional facet joint reduces the possibility of postoperative instability. The clinical results of this procedure were excellent in the majority of cases during the short duration of follow-up.

Although this approach preserves the facet joint using minimally approach, it doesn't resolve the microinstability of the facet joint, possibly leading the further facet joint and ligament hypertrophy. Therefore, complete removal of the lesion using this approach should be performed and in case of excessive removal of facet joint leading to definite instability, the fusion procedure would be considered. Moreover, for evaluating the precise prognosis of this procedure, large series of patients should be followed for long-term period.

CONCLUSION

Minimally invasive combined interlaminar and paraisthmic approach provides good outcome in carefully selected patients with symptomatic lumbar foraminal stenosis. The procedure provides good surgical trajectory to both side of neural foramen using minimally invasive approach, preserving most of functional ligamentous and bony structures. Further follow-up for large series of patients should be needed.

References

1. Burton CV, Kirkaldy-Willis WH, Yong-Hing K, Heithoff KB : Causes of failure of surgery on the lumbar spine. *Clin Orthop Relat Res* : 191-199, 1981
2. Epstein NE : Evaluation of varied surgical approaches used in the management of 170 far-lateral lumbar disc herniations : indications and results. *J Neurosurg* 83 : 648-656, 1995
3. Haher TR, O'Brien M, Dryer JW, Nucci R, Zipnick R, Leone DJ : The role of the lumbar facet joints in spinal stability. Identification of alternative paths of loading. *Spine* 19 : 2667-2670; discussion 2671, 1994
4. Hejazi N, Witzmann A, Hergan K, Hassler W : Combined transarticular lateral and medial approach with partial facetectomy for lumbar foraminal stenosis. Technical note. *J Neurosurg* 96 : 118-121, 2002
5. Herron LD : Selective nerve root block in patient selection for lumbar surgery : surgical results. *J Spinal Disord* 2 : 75-79, 1989

6. Inufusa A, An HS, Lim TH, Hasegawa T, Haughton VM, Nowicki BH : Anatomic changes of the spinal canal and intervertebral foramen associated with flexion-extension movement. *Spine* 21 : 2412-2420, 1996
7. Jackson RP, Glah JJ : Foraminal and extraforaminal lumbar disc herniation : diagnosis and treatment. *Spine* 12 : 577-585, 1987
8. Jenis LG, An HS, Gordin R : Foraminal stenosis of the lumbar spine : a review of 65 surgical cases. *Am J Orthop* 30 : 205-211, 2001
9. Kunogi J, Hasue M : Diagnosis and operative treatment of intraforaminal and extraforaminal nerve root compression. *Spine* 16 : 1312-1320, 1991
10. Lee CK, Rauschnig W, Glenn W : Lateral lumbar spinal canal stenosis : classification, pathologic anatomy and surgical decompression. *Spine* 13 : 313-320, 1988
11. Lejeune JP, Hladky JP, Cotten A, Vinchon M, Christiaens JL : Foraminal lumbar disc herniation. Experience with 83 patients. *Spine* 19 : 1905-1908, 1994
12. Macnab I : Negative disc exploration. An analysis of the causes of nerve-root involvement in sixty-eight patients. *J Bone Joint Surg Am* 53 : 891-903, 1971
13. Nowicki BH, Haughton VM, Schmidt TA, Lim TH, An HS, Riley LH 3rd, et al : Occult lumbar lateral spinal stenosis in neural foramina subjected to physiologic loading. *AJNR* 17 : 1605-1614, 1996
14. Porter RW, Hibbert C, Evans C : The natural history of root entrapment syndrome. *Spine* 9 : 418-421, 1984
15. Schnebel B, Kingston S, Watkins R, Dillin W : Comparison of MRI to contrast CT in the diagnosis of spinal stenosis. *Spine* 14 : 332-337, 1989
16. Tessitore E, de Tribolet N : Far-lateral lumbar disc herniation : the microsurgical transmuscular approach. *Neurosurgery* 54 : 939-942; discussion 942, 2004
17. Vanderlinden RG : Subarticular entrapment of the dorsal root ganglion as a cause of sciatic pain. *Spine* 9 : 19-22, 1984
18. Weiner BK, Fraser RD : Foraminal injection for lateral lumbar disc herniation. *J Bone Joint Surg Br* 79 : 804-807, 1997
19. Wiltse LL : The paraspinous sacrospinalis-splitting approach to the lumbar spine. *Clin Orthop Relat Res* : 48-57, 1973

COMMENTARY

Lateral spinal canal stenosis is known as a relatively common cause of lumbar radiculopathy nowadays. With the increased life span, more sophisticated diagnostic methods such as MRI and CT of high resolution, and our acquaintance with the abnormality, the number of patient with the disease entity is increasing continuously. Therefore, it has become an important pathological entity to identify in the patient being treated for lumbar radicular symptoms.

Various surgical approaches have been used to decompress the root entrapped by the lateral spinal stenosis as they exit from the lumbar spinal canal. The drawbacks of medial

subtotal facetectomy are poor visual control and the risk of incomplete decompression of the lateral foramen. The lateral paraisthmic approach has the advantage of easy access to the lateral foramen, but with this approach alone medial foramen couldn't be decompressed well. Several authors have advocated the complete removal of the facet joint to allow for thorough decompression and exploration of the intervertebral foramen. These steps, however, may result in spinal instability and occasionally require posterolateral fusion. Even in the absence of significant manifestation of spinal instability, the total facetectomy creates altered paths of loading in the three columns of the spine, which may cause significant postoperative low-back pain due to degeneration in the adjacent discoligamentous structures. Although facet joint destruction will not produce acute instability, it will transfer the loads to the adjacent disc and conceivably accelerate its degeneration.

The authors performed a minimally invasive combined interlaminar and paraisthmic approach for symptomatic lumbar foraminal stenosis in seven patients to maintain the integrity of the facet joint, insure sufficient exploration, and obtain sufficient decompression of the lumbar foramen. In their cases medial portion of the base of the inferior articular process of the superior vertebral body had to be removed to decompress the inferior nerve root and the superolateral portion of the facet joint and the lateral margin of the isthmus are drilled away. This bone removal may weaken the base of the articular process and could result in fracture and significant postoperative spinal instability.

Although this procedure seems to allow for preservation of the main portion of the facet joint and provides good access to and visual control of the nerve root, as well as the lateral and the medial part of the intervertebral foramen, a more large number of operation cases with longer follow-up study is necessary to prove its effectiveness and convenience.

Soo-Han Kim, M.D.
Department of Neurosurgery
Chonnam National University