

## Dural Arteriovenous Fistula Presenting with Cerebral Infarction

In Chang Hwang, M.D.,<sup>1</sup> In Sung Park, M.D.,<sup>1</sup> Dae Seob Choi, M.D.,<sup>2</sup> Jae Wook Ryoo, M.D.<sup>2</sup>

*Departments of Neurosurgery,<sup>1</sup> Diagnostic Radiology,<sup>2</sup> School of Medicine*

*Gyeongsang Institute of Health Science, Gyeongsang National University, Jinju, Korea*

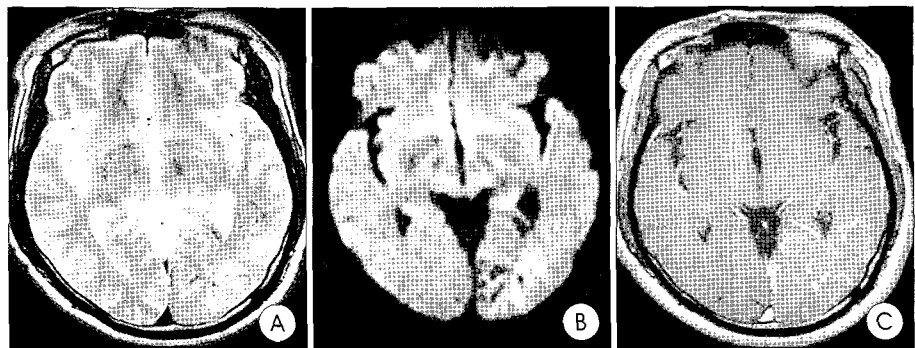
We report on a diabetic 52-year-old man who complained ocular floating sensation, headache and dizziness, in whom a left parieto-occipital dural arteriovenous fistulas (DAVFs), fed by bilateral superficial temporal arteries and occipital artery, drained into the cortical vein of the left parieto-occipital convexity. Because the patient's chief complaint was ocular symptom for diabetic retinopathy, we initially didn't consider an DAVFs until brain magnetic resonance imaging (MRI) was done. Diffusion-weighted brain MRI revealed acute cerebral infarction and microhemorrhage in the lesion. Transarterial embolization with mixture of glue and lipiodol obliterated the DAVFs completely. Although the DAVFs fed by multi-arteries, the fistulous portion has been disappeared after embolization via an only left occipital artery. Endovascular embolization of the fistula led to symptomatic improvement, except ocular discomfort.

**KEY WORDS :** Dural arteriovenous fistulas · Cerebral infarction · Embolization.

### Introduction

Intracranial dural arteriovenous fistulas (DAVFs) are rare lesions that account for 10-15% of intracranial arteriovenous malformations<sup>1)</sup>. Symptoms and signs of DAVFs include pulse-synchronous tinnitus, bruit, headache, papilledema, hemorrhage, infarction, proptosis, visual decline, an altered mental status, and transient or permanent neurological deficits. DAVFs have been managed by transarterial embolization, transvenous embolization, surgical resection, or radiotherapy. Here, we describe a unique case of transarterial embolization of DAVFs presenting with infarction.

dizziness. He had no history of a trauma or of a coagulation disorder, and laboratory findings were normal. He had a past history of diabetes mellitus for fifteen years. There were no bruit or thrill on the periorbital area. The initial impression by an ophthalmologist at another clinic was diabetic retinopathy, and initially we didn't consider AVF. In spite of treatments for diabetic retinopathy, his symptoms did not improve. Brain




**Fig. 1.** Preoperative brain MRI. A : T2-weighted image showing an ill-defined hyperintense lesion in left temporooccipital lobes. B : Diffusion-weighted imaging reveals that the hyperintense area represented acute infarction and hypointense foci represented hemorrhage. C : On contrast-enhanced T1-weighted images, multiple contrast-enhancing engorged veins are visualized within the lesion.

### Case Report

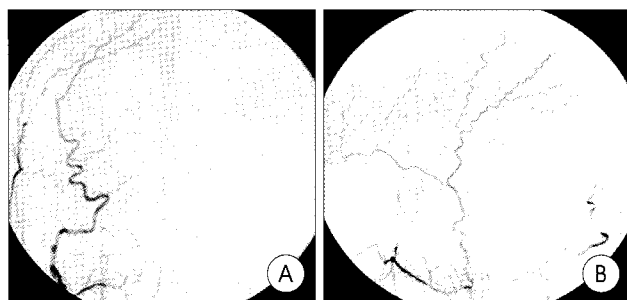
A 52-year-old man had a 7-day history of right ocular floating sensation, headache and

• Received : December 29, 2006 • Accepted : April 12, 2007

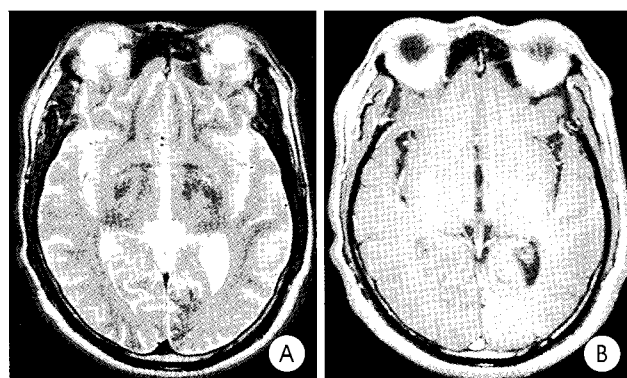
• Address for reprints : In Sung Park, M.D., Department of Neurosurgery, School of Medicine, Gyeongsang Institute of Health Science, Gyeongsang National University, 90 Chiram-dong, Jinju 660-751, Korea Tel : +82-55-750-8018, Fax : +82-55-759-0817, E-mail : gnuhpis@nongae.gsnu.ac.kr



**Fig. 2.** Preoperative external carotid angiography (A), lateral left external carotid angiographic view (B), and a lateral selective left occipital arteriographic view (C) shows a dural arteriovenous fistula in the left parietal region, fed by bilateral superficial temporal and occipital arteries. Note the venous drainage into engorged cortical veins (arrows).



**Fig. 3.** Postoperative external carotid angiography. Frontal right external carotid angiographic view (A) and lateral left external carotid angiographic view (B) show no definite residual dural arteriovenous fistula. The left occipital artery is completely occluded.



**Fig. 4.** Postoperative brain MRI obtained 9 months after embolization. A : On this T2-weighted image, the hyperintense lesion is observed on the preoperative MR image (Fig. 1A) had disappeared. B : On this contrast-enhanced T1-weighted image, as compared with preoperative brain MRI (Fig. 1C), contrast-enhancing engorged veins are reduced in number.

MRI was then evaluated that demonstrated an edematous lesion with prominent intravascular enhancement in the left temporo-parieto-occipital lobes. A hyperintense area by diffusion-weighted imaging presented acute infarction and hypointense foci represented hemorrhage (Fig. 1). The brain MR angiography revealed a prominent left occipital artery with early opacification of superior sagittal sinus and cortical veins in the parieto-occipital lobes. Both external carotid angiography (CAG) revealed DAVFs supplied by branches of the both occipital and superficial temporal artery (Fig. 2). These DAVFs drained

into a cortical vein in the left parieto-occipital convexity. First, we considered transvenous approach, but we could not introduce the microcatheter into engorged cortical vein. Then we tried to do transarterial approach via left occipital artery. We embolized the left occipital artery with mixture of glue and lipiodol via Prowler-10 microcatheter and agility-10 microguide-wire. Fortunately, after embolization,

the fistulous portion has been disappeared on the CAG (Fig. 3), and patient's symptoms were improved. However, ocular symptom has been remained. We concluded that the cause of ocular discomfort was diabetic retinopathy. The hyperintense lesion visualized in pre-embolization brain MRI was disappeared on the MRI obtained 9 months after embolization (Fig. 4).

## Discussion

The natural history of DAVFs is highly variable. Some patients become symptomatic and some experience benign symptoms for many years, and in such cases DAVFs are an incidental angiographic finding. Other fistulae may exhibit aggressive behavior and may be dangerous as much as a parenchymal AV malformation<sup>3)</sup>. The symptoms of DAVFs have been related to location and the state of venous drainage. Awad et al. statistically examined 377 fistulas and reported that the presences of leptomeningeal venous drainage, variceal or aneurysmal venous dilatations, or galenic drainage are significantly correlated with an aggressive neurological presentation<sup>2)</sup>. Congnard et al. proposed a DAVF classification system that correlates the patterns of venous drainage with the clinical presentation<sup>4)</sup>. Type I DAVFs are located in the main sinus with antegrade flow. Type II lesions are located in the main sinus with reflux into the sinus (IIa), cortical vein (IIb), or both (IIa + b). Type III lesions have direct cortical venous drainage without venous ectasia. Type IV lesions have direct cortical venous drainage with venous ectasia. Type V lesions have spinal venous drainage, which may induce progressive myelopathy. Our patient had type III DAVF with direct drainage into the cortical veins without associated venous ectasia.

Tissue hypoperfusion induced by venous hypertension can cause brain ischemia and even infarction<sup>7,9)</sup>. Iwama et al. used positron emission tomography scans to confirm that the areas of reduced regional cerebral blood flow and elevated regional oxygen extraction fractions correlated well with the areas showing retrograde venous drainage into the cortical veins

and delayed parenchymal circulation on angiogram<sup>6</sup>. This showed that venous congestion induced by the retrograde leptomeningeal venous flow might cause brain tissue ischemia or infarction. In our case, we believe that acute cerebral infarction had been induced by venous hypertension, and microhemorrhage had been secondary to the hemorrhage transformation of the venous infarction.

The therapeutic strategy for DAVF includes transarterial embolization, surgical resection, radiosurgery or transvenous embolization. Transarterial embolization of DAVFs is effective at obliterating or reducing the arterial inflow from external carotid arteries, but often cannot obliterate feeding arteries from internal carotid arteries. Although surgical excision of the involved sinus is possible, massive intraoperative hemorrhage can occur because of the rich vascularity of surrounding structures<sup>1</sup>. Radiosurgery may also be effective for treating DAVFs, although long post-treatment intervals are required before lesions are obliterated<sup>8</sup>. The transvenous endovascular obliteration of intracranial DAVFs is another therapeutic option, and may be accomplished either using endovascular techniques alone or a combination of surgical exposure and intraoperative "open" cannulation of veins draining the fistula. Transvenous embolization is directed to the thrombosis of the venous side of a lesion, including the parent sinus<sup>5,10</sup>. In our case, initial transvenous embolization could not be considered due to the presence of an engorged vein, and transarterial embolization was performed via a left occipital arterial selection. Fortunately, the fistulas were found to have disappeared on follow up angiogram after embolization of mixture of glue and lipiodol. Therefore, we didn't have to embolize via other arterial or venous selection.

The transarterial approach has a higher rate of recurrence than the transvenous approach because the fistulas has usually multiple feeding artery. Therefore, it is necessary to regular follow-up angiography. In our case, angiography was not performed because the resolution of clinical symptom was evident and clinical follow-up showed no recurrence of clinical

symptom. Moreover, there was no evidence of recurrence on the brain MRI checked 9 months after embolization.

## Conclusion

The authors experienced a rare case of Type III DAVFs that presented with infarction. The DAVFs in this case completely disappeared after transarterial embolization with a mixture of glue and lipiodol.

## References

1. Ahn JY, Kwon SO, Lee BH, Choi EW : Embolization of dural arteriovenous malformation of the jugular bulb. *J Korean Neurosurg Soc* 31 : 593-595, 2002
2. Awad IA, Little JR, Akarawi WP, Ahl J : Intracranial dural arteriovenous malformations : Factors predisposing to an aggressive neurological course. *J Neurosurg* 72 : 839-850, 1990
3. Collice M, D'Alberti G, Arena O, Solani C, Fontana RA, Talamonti G : Surgical treatment of intracranial dural arteriovenous fistulae : Role of venous drainage. *Neurosurgery* 47 : 56-67, 2000
4. Congnard C, Gobin YP, Pierot L, Bailly AL, Houdart E, Casasco A, et al : Cerebral dural arteriovenous fistulas : Clinical and angiographic correlation with a revised classification of venous drainage. *Radiology* 194 : 671-680, 1995
5. Halbach VV, Higashida RT, Hieshima GB, Rosenblum M, Cahan L : Transvenous embolization of dural fistulas involving the transverse and sigmoid sinuses. *AJNR Am J Neuroradiol* 10 : 385-392, 1989
6. Iwama T, Hashimoto N, Takagi Y, Tanaka M, Yamamoto S, Nishi S, et al : Hemodynamic and metabolic disturbances in patients with intracranial dural arteriovenous fistulas : Positron emission tomography evaluation before and after treatment. *J Neurosurg* 86 : 806-811, 1997
7. Kai Y, Hamada JI, Morioka M, Todaka T, Mizuno T, Ushio Y : Pre- and post-treatment MR imaging and single photon emission CT in patients with dural arteriovenous fistulas and retrograde leptomeningeal venous drainage. *AJNR Am J Neuroradiol* 24 : 619-625, 2003
8. Link MJ, Coffey RJ, Nichols DA, Groman DA : The radiosurgery and particulate embolization in the treatment of dural arteriovenous fistulas. *J Neurosurg* 84 : 804-809, 1996
9. Lo CP, Chen CY, Hsueh CJ, Chin SC, Kao HW : Diffusion-weighted magnetic resonance imaging of spontaneous venous infarction and cortical hemorrhage complicating dural arteriovenous fistula. *J Neuroimaging* 16 : 69-72, 2006
10. Mullan S, Johnson DL : Combined sagittal and lateral sinus dural fistulae occlusion. *J Neurosurg* 82 : 159-165, 1995
11. Newton Th, Cronqvist S : Involvement of dural arteries in intracranial arteriovenous malformations. *Radiology* 93 : 1071-1078, 1969