

Bilateral Acute Subdural Hematoma Following Evacuation of Chronic Subdural Hematoma

Seok Won Kim, M.D., Seung Myung Lee, M.D., Ho Shin, M.D.

Department of Neurosurgery, College of Medicine, Chosun University, Gwangju, Korea

Complications after surgery for chronic subdural hematoma (SDH) include recurrence of the hematoma, tension pneumoencephalus and intracerebral hematoma. We report an unusual case of development bilateral of acute subdural hematoma after drainage of chronic subdural hematoma in a 48-year-old woman. Pathophysiological mechanisms of this uncommon entity are discussed and relevant literature is reviewed.

KEY WORDS : Chronic subdural hematoma · Complication · Mechanism.

Introduction

Chronic subdural hematoma (SDH) is known to have a good prognosis with relatively simple surgical treatment⁵⁾. Although the potential for recovery from chronic subdural hematoma is very high, unexpected neurologic deterioration may occasionally complicate the postoperative course. Contralateral development of acute subdural hematoma occurring after removal of chronic SDH has been reported recently as a rare but nearly devastating postoperative complication^{4,10)}. We report a extremely rare case of a "bilateral" acute SDH occurring after evacuation of chronic SDH with review of the possible mechanism.

We report a extremely rare case of a "bilateral" acute SDH occurring after evacuation of chronic SDH with review of the possible mechanism.

Case Report

A 48-year-old woman was admitted to our institute with a history of mild head injury resulting

from a car stroke about 3 weeks previously. She had complained of severe headache and left side motor weakness. Neurologic examination revealed mild left hemiparesis (Grade V / Grade IV). The routine laboratory tests including platelet count, prothrombin time, and activated partial thromboplastin time were within normal limits. Brain computed tomography (CT) scan showed a hypodense lesion in right frontotemporal region, suggesting chronic SDH with midline shift (Fig. 1). The hematoma was evacuated through one burr hole using 5-L catheter under local anesthesia. Dark old blood was removed and no evidence of active bleeding was confirmed. The wound was then closed layer by layer after setting a simple closed system in the subdural space and operation was finished as usual manner.

However, after operation, the patient complained of more severe headache, nausea and vomiting. The CT scan taken

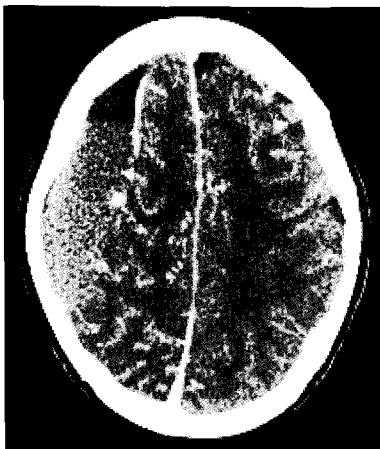


Fig. 1. Preoperative enhanced computed tomography scan showing a right sided chronic subdural hematoma.

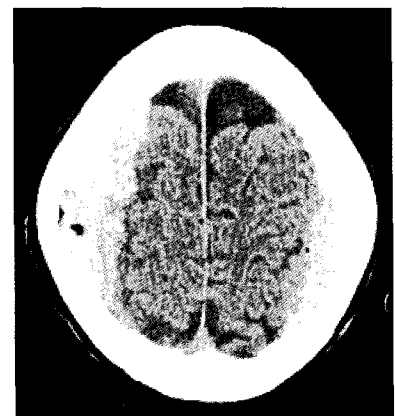


Fig. 2. Postoperative computed tomography scan demonstrates a newly developed high density area over bilateral hemisphere.

• Received : November 10, 2006 • Accepted : February 6, 2007

• Address for reprints : Seok Won Kim, M.D., Department of Neurosurgery College of Medicine, Chosun University, 588 Seosuk-dong, Dong-gu, Gwangju-city 501-717, Korea. Tel : +82-62-220-3120, 3126. Fax : +82-62-227-4575, E-mail : chosunns@hanmail.net

7 hours later demonstrated an acute bilateral acute SDH (Fig. 2). Because the amount of hematoma in left side is small, emergent craniotomy of right side was performed to evacuate the hematoma. After evacuation of hematoma, we tried to find a torn bridging vein but we couldn't find any bleeding sources. After the right side craniotomy and hematoma evacuation, the patient recovered fully and discharged 12 days later without any sequelae.

Discussion

Evacuation of chronic SDH with burr hole drainage using 5L-cath is an effective and minimally invasive technique. Although the prognosis of chronic SDH is good, some unusual and devastating complications may still occur. McKissock reported one patient who deteriorated after evacuation of a large chronic SDH and had a brain stem hematoma at autopsy⁷. Intracranial hematomas occurring after removal of chronic SDH have been reported recently as a rare but nearly devastating postoperative complication^{2,4,10}.

The pathophysiologic mechanisms of intracranial hematomas occurring after evacuation of chronic extracerebral fluid collections are not clear. There is probably no single etiologic factor. Damage to cerebral vasculature secondary to perioperative parenchymal shift, sudden increase of cerebral blood flow combined with defective vascular autoregulation, and hemorrhage into previously undetected contusion have been proposed to explain the occurrence of delayed intracranial hematomas or SDH^{6,8}. Brodersen and Gjerris found that the regional blood flow in patients with chronic SDH decreased uniformly all over the affected hemisphere and returned to normal after surgical decompression. Therefore, it seems reasonable to hypothesize that sudden restoration of normal perfusion pressure in areas of faulty cerebral vascular autoregulation may lead to the vascular damage that results in intracranial hematoma or SDH¹. Tabaddor suggested that slow decompression with twist-drill craniotomy and closed-system drainage can avoid rapid dynamic intracranial change and may prevent this undesirable complication⁹. This method is thought to decompress the brain more slowly and avoid the presumed rapid pressure shifts that may occur following other methods, which may be associated with complications such as intraparenchymal hemorrhage. Before second burr hole is made, first burr hole is drilled and opening is made in the dura to release

the subdural fluid slowly. This maneuver also prevents rapid shifts of the underlying brain³. In our case, ipsilateral bleeding from a torn bridging vein seemed to damage the cerebral vasculature and secondary perioperative parenchymal shift may have been a factor that might have caused the contralateral SDH. Delayed hematomas may become clinically apparent within hours and days after minimal invasive trephination surgery, as illustrated by our case. Because, in most instances, one may find delayed hematomas when serial CT scans are done, it is important to monitor intensively any patient with chronic SDH after surgical evacuation. Early diagnosis and immediate surgical intervention may provide the patient a chance for full recovery, even though the presence of midline shift and vessel free areas are indicators of a poor prognosis.

Conclusion

Ipsilateral and contralateral acute SDH following evacuation of chronic SDH may be an unusual complication. The clinical importance of this uncommon event is that it is potentially treatable. If the patient demonstrates an unexpected postoperative course, prompt CT scan to assess this uncommon complication may reverse the adverse outcome.

References

1. Brodersen P, Gjerris F : Regional cerebral blood flow in patients with chronic subdural hematomas. *Acta Neurol Scand* 51 : 233-239, 1975
2. D'Avella D, De Blasi F, Rotilio A, Pensabene V, Pandolfo N : Intracerebral hematoma following evacuation of chronic subdural hematomas. Report of two cases. *J Neurosurg* 65 : 710-712, 1986
3. Hamilton MG, Frizzell JB, Tranmer BI : Chronic subdural hematoma : the role for craniotomy reevaluated. *Neurosurgery* 33 : 67-72, 1993
4. Harada K, Ohtsuru K, Nakayama K, Takagi S, Shigemori M, Tokunaga T, et al : Contralateral development of acute subdural hematoma following surgery for chronic subdural hematoma--case report. *Neurol Med Chir (Tokyo)* 32 : 969-971, 1992
5. Jeong CA, Kim TW, Park KH, Chi MP, Kim JO, Kim JC : Retrospective analysis of re-operated patients after chronic subdural hematoma surgery. *J Korean Neurosurg Soc* 38 : 116-120, 2005
6. Klintworth GK : The pathogenesis of secondary brainstem hemorrhages as studied in an experimental model. *Am J Pathol* 47 : 525-536, 1965
7. McKissock W, Richardson A, Bloom WH : Subdural hematomas : a review of 389 cases. *Lancet* 1 : 1365-1369, 1960
8. Modesti LM, Hodge CJ, Barnwell ML : Intracerebral hematoma after evacuation of chronic extracerebral fluid collections. *Neurosurgery* 10 : 689-693, 1982
9. Tabaddor K, Shulmon K : Definitive treatment of chronic subdural hematoma by twist-drill craniotomy and closed-system drainage. *J Neurosurg* 46 : 220-226, 1977
10. Turgut M, Akalan N, Saglam S : A fatal acute subdural hematoma occurring after evacuation of "contralateral" chronic subdural hematoma. *J Neurosurg* 42 : 61-63, 1998