

# Progressively Enlarged Intracerebral Ependymal Cyst Presenting with Movement Disorder

Seong Jun Lee, M.D., Chang Ki Hong, M.D., Jung Yong Ahn, M.D., Kyu Sung Lee, M.D.

Department of Neurosurgery, Yonsei University College of Medicine, Seoul, Korea

Ependymal cysts are neuroepithelial cysts, typically found in the central white matter of the temporoparietal and frontal lobes. Clinical symptoms usually result from neurological deficits referable to these regions, from seizures, and chronic headaches associated with increased intracranial pressure. We describe here a case of ependymal cyst on the right fronto-parietal lobe, presenting with tremor and weakness. The cyst was resected surgically and presurgical neurological abnormalities were improved. An exploratory surgery with establishment of an adequate route of drainage and histological examination of the cyst wall are mandatory in the management of patients with a progressive and symptomatic intraparenchymal cyst.

**KEY WORDS :** Brain cysts · Ependymal cyst · Surgical treatment.

## Introduction

Intracerebral cysts without communication with the cerebral ventricles or the subarachnoid space are often referred to as ependymal or epithelial cysts<sup>2)</sup>. Their fluid content is most similar to that of cerebrospinal fluid (CSF). They are rare compared with other benign cysts and generally located in the cerebral parenchyma or juxtaventricular region<sup>5)</sup>. Most of cases are asymptomatic<sup>7)</sup>. However, some present with seizure<sup>10,14)</sup>, mass effect<sup>9,13)</sup>, or rarely movement disorders<sup>1,6,8)</sup>.

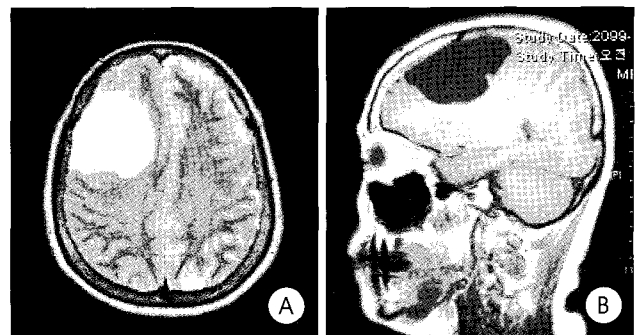
Here, we present a case of progressively enlarged ependymal cyst with a review on its pathogenesis, clinical presentation, and natural history of symptomatic intracerebral ependymal cysts and the current treatment options.

## Case Report

A 61-year-old woman presented with tremor on the left hand. The patient suffered from chronic headache for 6 months prior to admission. The patient also complained of stiffness, slowness and involuntary movements of the left arm that had progressed slowly over three months.

Neurological examination revealed normal mental status and cranial nerve function. There was a coarse tremor at rest that increased with intention. Tone was increased in the affected

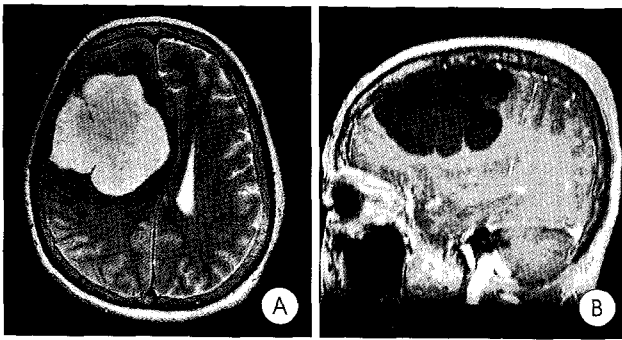
limb in a lead-pipe manner without cog-wheeling. Bilateral hyperreflexia, more pronounced in the left upper extremity was noticeable. There was mild weakness in the left arm in a pyramidal pattern. Preoperative magnetic resonance images (MRI) demonstrated a large intracerebral cyst on the right fronto-parietal area (Fig. 1). This revealed the lesion was well-defined with CSF intensity (Fig. 2). The cyst was growing compared with previous MR images and mass effect was seen on adjacent structures including basal ganglia and ventricle. There was neither surrounding brain edema nor contrast enhancement.




**Fig. 1.** Magnetic resonance images at 6 months prior to admission. T2-weighted axial (A) and T1-weighted sagittal (B) images show a large intracerebral cyst on the right fronto-parietal lobe with well-demarcated margin.

• Received : August 31, 2006 • Accepted : January 24, 2007

• Address for reprints : Jung Yong Ahn, M.D., Department of Neurosurgery, Yonsei University College of Medicine, 146-92 Dogok-dong, Gangnam-gu, Seoul 135-720, Korea Tel : +82-2-2019-3391, Fax : +82-2-3461-9229, E-mail : jyahn@yumc.yonsei.ac.kr



**Fig. 2.** Magnetic resonance images on admission. T2-weighted axial (A) and T1-weighted sagittal (B) images reveal an enlarged cyst compared with previous MRI (Fig. 1) with severe mass effect on adjacent structures.



**Fig. 3.** Histopathological examination of the cyst wall shows stratified columnar epithelium, overlying gliotic tissue, without a basement membrane (H & E: original magnification x 200).

Given the progression of her symptoms and radiologic findings, the patient underwent a right fronto-parietal craniotomy. The membrane of cyst was transparent, and the cystic fluid was clear. Approximately 20ml of clear fluid was aspirated from the cyst. No tumor or other abnormalities were evident within the cyst cavity. The cyst was marsupialized, and multiple biopsy specimens from the cyst wall were sent for pathological assessment. A postoperative CT scan showed a right parietal intracerebral hemorrhage which was remote from the cyst. Hemorrhage was evacuated immediately and the patient's neurologic condition was improved and became stable. A marked reduction in the patient's tremor was noted at 3 days after the first surgery but increased muscle tone was still present. Histopathological examination of the cyst wall showed stratified columnar epithelium, overlying gliotic tissue, without a basement membrane characteristics of ependymal cyst (Fig. 3).

## Discussion

Ependymal cysts are neuroepithelial cysts, typically found in the central white matter of the temporoparietal and frontal lobes. Friede and Yasargil<sup>6</sup> reported 15 patients, all with a short presenting history, extending for several years. Mean age at presentation was 33 years, and a slight male predominance was reported<sup>11</sup>. Most of these lesions are diagnosed incidentally<sup>7</sup>. Clinical symptoms usually result from neurological deficits referable to these lobes, from seizures, and chronic headaches associated with increased intracranial pressure. The clinical presentation of an ependymal cyst with a movement disorder is particularly uncommon. When it does occur, tremor is the most frequent manifestation as in our patient<sup>9</sup>, but hemiballismus has also been reported<sup>11</sup>. These symptoms are common in paraventricular cysts involving the basal ganglia although the physiopathological mechanisms remain unclear. In this patient, association of tremor can be explained by the mass effect of the cyst on basal ganglia. Direct pressure causing dysfunction of the basal ganglia or causing disturbance of normal metabolism of monoamines locally may be the possible mechanism of pathologic tremor in this case.

The natural history of these cysts is unknown. Follow-up examinations usually disclose no clinical or imaging changes in asymptomatic lesions. In our case, the cystic lesion was progressively enlarged and became symptomatic. Suggested mechanisms for fluid accumulation within ependymal cysts include active secretion, transcellular transport, and passive transport caused by fluid hyperosmolality<sup>12</sup>. It is thought that the size of the cyst increases gradually as secretory and breakdown products from the epithelial lining accumulate within it<sup>3</sup>.

These cysts are most often found within the parenchyma and the juxtaventricular regions, and they are lined by columnar or cuboidal cells, with or without cilia<sup>6</sup>. The diagnosis of ependymal cyst is appropriate for cysts with an epithelial lining that rests directly on brain parenchyma or a layer of astroglia, rather than a basement membrane and connective tissue. Ependymal cysts show immunoreactivity for GFAP and S-100, glial markers that are expressed by the normal ependymal epithelium<sup>4</sup>.

A multitude of treatment modalities have been suggested over the years. Conservative follow-up is recommended if the patient is asymptomatic or the symptoms can be managed medically<sup>7,10</sup>. With symptomatic lesions, particularly those with mass effect, surgical management is recommended. Surgical approaches have varied from simple stereotactic aspiration (with or without biopsy), to more invasive procedures such as endoscopic fenestration of the cyst to an adjacent CSF space<sup>12</sup>, placement of an internal cysto-subarachnoid or cysto-ventricular

shunt<sup>15</sup>), cyst resection, or open fenestration into the subarachnoid space or ventricles<sup>1)</sup>. Simple stereotactic drainage of ependymal cysts has a high recurrence rate<sup>8,9)</sup>. Although our patient had a uncommon complication, we believe a more definitive procedure to prevent the reaccumulation of fluid must be sought.

## Conclusion

Although several symptomatic ependymal cysts of the parenchyma have been cited in the literature, we believe that these ependymal cysts with movement disorder are rare. An exploratory surgery with establishment of an adequate route of drainage and histological examination of the cyst wall are mandatory in the management of patients with a progressive and symptomatic lesion.

## References

1. Bejar JM, Kepes J, Koller WC : Hemiballism and tremor due to ependymal cyst. *Mov Disord* 7 : 370-372, 1992
2. Bouch DC, Mitchell I, Maloney AFJ : Ependymal lined paraventricular cerebral cysts; a report of three cases. *J Neurol Neurosurg Psychiatry* 36 : 611-671, 1973
3. Ciricillo SF, Davis RL, Wilson CB : Neuroepithelial cysts of the posterior fossa. *J Neurosurg* 72 : 302-305, 1990
4. Coca S, Martinez A, Vaquero J, Moreno M, Martos JA, Rodriguez J, et al : Immunohistochemical study of intracranial cysts. *Histol Histopathol* 8 : 651-654, 1993
5. Czervionke LF, Daniels DL, Meyer GA, Pojunas KW, Williams AL, Haughton VM : Neuroepithelial cysts of the lateral ventricles : MR appearance. *AJNR Am J Neuroradiol* 8 : 609-613, 1987
6. Friede RL, Yasargil MG : Supratentorial intracerebral epithelial (ependymal) cysts : review, case reports, and fine structure. *J Neurol Neurosurg Psychiatry* 40 : 127-137, 1977
7. Guermazi A, Miaux Y, Majoulet JF, Lafitte F, Chiras J : Imaging findings of central nervous system neuroepithelial cysts. *Eur Radiol* 8 : 618-623, 1998
8. Heran NS, Berk C, Constantoyannis C, Honey CR : Neuroepithelial cysts presenting with movement disorders : two cases. *Can J Neurol Sci* 30 : 393-396, 2003
9. Markwalder TM, Zimmerman A : Intracerebral ciliated epithelial cyst. *Surg Neurol* 11 : 195-198, 1979
10. Morioka T, Nishio S, Suzuki S, Fukui M, Nishiyama T : Choroidal fissure cyst in the temporal horn associated with complex partial seizure. *Clin Neurol Neurosurg* 96 : 164-167, 1994
11. Nakase H, Ishida Y, Tada T, Sakaki T, Goda K, Tunoda S, et al : Neuroepithelial cyst of the lateral ventricle : Clinical features and treatment. *Surg Neurol* 37 : 94-100, 1992
12. Pant B, Uozumi T, Hirohata T : Endoscopic resection of intraventricular ependymal cyst presenting with psychosis. *Surg Neurol* 46 : 573-578, 1996
13. Park HM, Jang SJ, Jeong SH, Song JK, Lim SC, Lee SM, et al : Ependymal cyst of the sylvian fissure. *J Korean Neurosurg Soc* 28 : 1372-1375, 1999
14. Tamayo JA, Ojea T, Hervas M, Leon A, Fernandez O : Neuroepithelial cyst of the choroids sulcus as a probable cause of symptomatic focal epilepsy. *Rev Neurol* 25 : 2070-2071, 1997
15. Wester K, Pedersen PH : Benign intracerebral cysts treated with internal shunts : review and report of two patients. *Neurosurgery* 30 : 432-436, 1992