

Downbeat Nystagmus Associated With Brainstem Compression by Vertebral Artery

Ki-Hyoung Moon, M.D.,¹ Sang-Ahm Lee, M.D.,² Jae-Sung Ahn, M.D.,¹ Byung-Duk Kwun, M.D.¹

Departments of Neurosurgery,¹ Neurology,² Asan Medical Center, University of Ulsan College of Medicine, Seoul, Korea

Rarely, downbeat nystagmus can occur due to compression of the lower brainstem by the ectatic vertebral artery and be resolved by microvascular decompression. We present a case of a 67-year-old man with downbeat nystagmus associated with brainstem compression by ectatic vertebral artery. He presented with oscillopsia and vertigo. When he turned his head upward, his symptoms were aggravated and a gait disturbance occurred. Magnetic resonance imaging and computed tomographic angiography demonstrated compression of the medulla oblongata by the left ectatic vertebral artery and other medical causes of downbeat nystagmus were ruled out. Retromastoid craniotomy was performed and after lifting the vertebral artery off the medulla, a trough-shaped indentation in the lower brainstem was identified. The ectatic vertebral artery was repositioned and a Teflon was inserted between the brainstem and the ectatic vertebral artery. Postoperatively, downbeat nystagmus had disappeared.

KEY WORDS : Downbeat nystagmus · Ectatic vertebral artery · Microvascular decompression.

Introduction

Downbeat nystagmus (DBN) is a specific sign associated with drug intoxication^{2,6}, or lesion in the region of the cervicomedullary junction^{4,5,9,11,17,19}. Rarely, DBN occurs due to compression of the lower brainstem by the dolichoectatic vertebral artery, although the mechanism is unknown^{7,10}.

We report a case in which after a variety of causes of DBN was ruled out, the cause of DBN was localized by magnetic resonance imaging (MRI) and DBN disappeared after microvascular decompression.

Case Report

A 67-year-old man presented with oscillopsia and vertigo. Oscillopsia tends to develop with position as his symptom aggravates on upward head turning. This is accompanied by gait disturbance. After visual fixation, oscillopsia disappears in 1-3 minutes. The symptoms first appeared 3 months previously following hyperextension of his neck during work. He had no other medical histories except hypertension.

On neurologic examination, DBN was evoked on upward

or left-sided stare, and there was no fatigue phenomenon. On electronystagmography, DBN was seen at 3-5 Hz and the slow-eye velocity was 13 degrees per second. There was left-sided dysdiadochokinesia but no other neurologic abnormalities.

MRI demonstrated no parenchymal lesion. However, compression of the medulla oblongata by the left ectatic vertebral artery was demonstrated, and the brainstem was deviated contralaterally beyond the midsagittal line (Fig. 1). Computed tomographic angiography demonstrated ectasia of the left vertebral artery (Fig. 2).

Retromastoid craniotomy was pe-

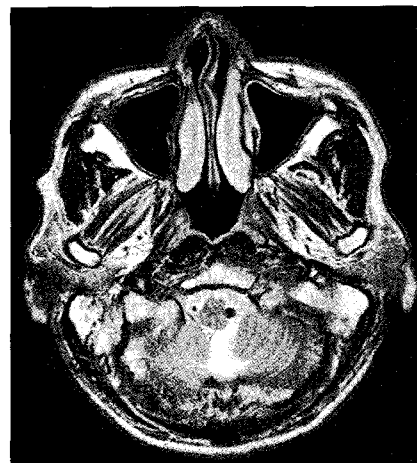

Fig. 1. Preoperative T2-weighted magnetic resonance image showing compression of the medulla by medial deviation of the vertebral artery.

• Received : May 17, 2006 • Accepted : December 29, 2006

• Address for reprints : Byung-Duk Kwun, M.D., Department of Neurosurgery, Asan Medical Center, University of Ulsan College of Medicine, 388-1 Pungnap-dong, Songpa-gu, Seoul 138-736, Korea Tel : +82-2-3010-3550, Fax : +82-2-476-6738, E-mail : bdkwun@amc.seoul.kr

formed in the park-bench position by a far-lateral approach, and the left intradural vertebral artery was exposed. The vertebral artery was confirmed as ectatic, compressing the lower brainstem. Lifting the left vertebral artery off the medulla revealed a trough-shaped indentation in the lower brainstem, after which the artery was repositioned and a Teflon was inserted between the brainstem and the ectatic vertebral artery (Fig. 3). After microvascular decompression, DBN gradually diminished and disappeared within 1 month postoperatively.

Discussion

DBN is enhanced by reciprocal interaction with the peripheral vestibular apparatus, vestibular nuclei, and vestibulocerebellum¹⁾, and is associated with a variety of clinical disorders. DBN can be caused by thiamine deficiency¹⁴⁾, ma-

gnesium deficiency¹⁸⁾, anticonvulsants²⁾, and lithium intoxication⁶⁾ as manifestation of toxic disturbances, and by encephalitis, infarction¹⁵⁾ and cerebellar degeneration³⁾ as manifestation of organic disturbances.

Cogan and Barrows reported that 8 of 27 patients presenting with DBN had platybasia or the Arnold-Chiari malformation⁴⁾, and Kobayashi et al. reviewed the clinical and oculomotor findings in 62 patients with DBN, and reported that the two most common causes were cerebellar ectopia (25%) and cerebellar degeneration (25%)⁹⁾. The majority of cases were due to congenital malformations such as Chiari malformation and basilar impression^{4,5,9,11,17,19)}.

The pathogenesis of DBN is still uncertain. Baloh and Spooner argued that DBN was a type of central vestibular nystagmus, resulting from a lesion at the floor of the fourth ventricle (by interruption of the tonic excitatory activity to the inferior rectus ocular muscle) or a lesion flocculus (which would lead to an increase in tonic excitatory activity to the superior rectus ocular muscle)¹⁾. Also, it was reported that DBN might be caused by a pursuit imbalance favoring a slow drift of the eye in the upward direction²⁰⁾.

In rare cases, DBN is associated with compression of the lower brainstem by a dolichoectatic vertebral artery. Jacobson and Corbett investigated a possible relationship between dolichoectasia of the vertebrobasilar artery and DBN cases of unknown cause⁸⁾. They reported that the cause of DBN could not be determined in 12 (29%) of 41 cases with DBN and that 2 of 12 cases had dolichoectasia of the vertebrobasilar artery as the only identifiable abnormality, and argued that compression of the caudal brainstem by an enlarged and tortuous vertebrobasilar artery system can cause DBN. Compression and indentation of the anterior and lateral surface of the caudal brainstem by enlarged and tortuous vertebral and basilar arteries has been confirmed at surgery and autopsy in patients with symptomatic dolichoectatic vertebrobasilar arteries^{13,16)}.

Improvement in DBN after surgical treatment in patients with structural lesions such as Arnold-Chiari malformation in the cervicomedullary junction has been reported^{9,11,17)}. Baloh and Spooner suggested that abnormality of eye movement in Arnold-Chiari malformation is due to compression of the herniating cerebellum against the caudal brainstem and is not a congenital aberrancy of the oculomotor pathway¹⁷⁾. They studied abnormal eye movements in five patients with Arnold-Chiari malformation, and in three patients with DBN the lower brainstem was fo-

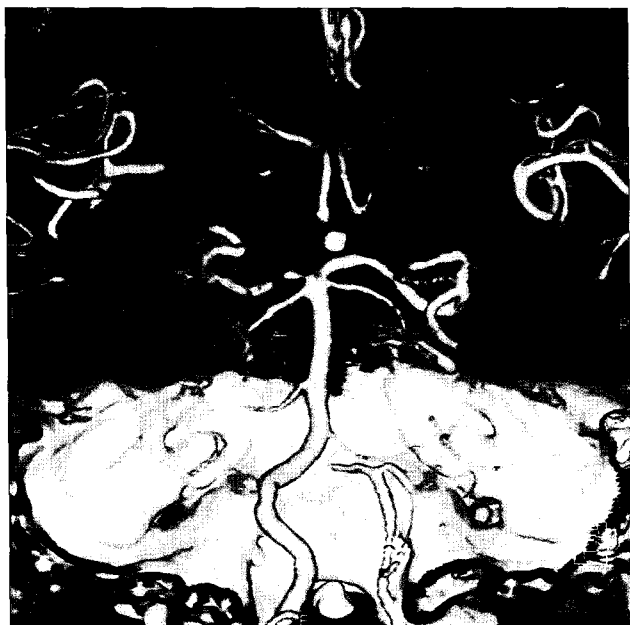

Fig. 2. Computed tomography angiography (PA view) revealing the left vertebral artery that is ectatic and medially deviated.

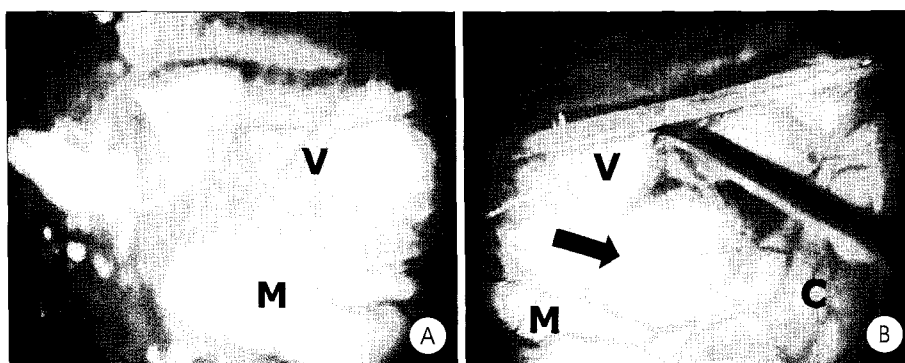


Fig. 3. Intraoperative findings. A: The left vertebral artery depressing the lateral surface of the medulla. B: The left vertebral artery has been lifted off the medulla, leaving a distinct indentation (arrow). V indicates vertebral artery; M, medulla; C, cerebellum.

und intraoperatively to be compressed by the cerebellar tonsil. Decompressive surgery resulted in the disappearance of DBN. Also, Kobayashi et al. reported that DBN disappeared after decompressive surgery in patients with compression of the medulla oblongata due to medial deviation of the vertebral arteries⁹⁾.

Interestingly, Himi et al.⁷⁾ and Lee¹⁰⁾ have emphasized that DBN may result from compression by dolichoectatic vertebral artery against the caudal brainstem in patients without malformation of cervicomedullary junction. Himi et al. performed surgery that resulted in the disappearance of DBN after several months. In our case, there was no dolichoectatic change of the vertebral artery, but the lower brainstem was compressed by the ectatic vertebral artery and surgical repositioning of the vertebral artery succeeded in resolving the DBN within one month.

Other than compression of the caudal brainstem by the vertebral artery, DBN can also be caused by flow reduction in the vertebral artery. Rosengart et al. reported the development of intermittent DBN due to transient obstruction of the dominant vertebral artery by an osteophyte of the cervical transverse foramen when the neck was rotated¹²⁾. Surgical removal of the osteophyte relieved DBN in such case.

Conclusion

In any patient who has unexplained DBN, compression of the lower brainstem by the vertebral artery should be considered in the differential diagnosis after various causes of DBN are first ruled out. These patients can be successfully treated by the microvascular decompression as in this case.

References

1. Baloh RW, Spooner JW : Downbeat nystagmus : a type of central vestibular nystagmus. *Neurology* 31 : 304-310, 1981

2. Berger JR, Kovacs AG : Downbeat nystagmus with phenytoin. *J Clin Neuroophthalmol* 2 : 209-211, 1982
3. Chambers BR, Ell JJ, Gresty MA : Case of downbeat nystagmus influenced by otolith stimulation. *Ann Neurol* 13 : 204-207, 1983
4. Cogan DG : Downbeat nystagmus. *Arch Ophthalmol* 80 : 757-768, 1968
5. Cogan DG, Barrows JL : Platybasia and the Arnold-Chiari malformation. *Arch Ophthalmol* 52 : 13-29, 1959
6. Coppeto JR, Monteiro MLR, Lessell S, Bear L, Martinez-Maldonado M : Downbeat nystagmus, Long-term therapy with moderate-dose lithium carbonate. *Arch Neurol* 40 : 754-755, 1983
7. Himi T, Kataura A, Tokuda S, Sumi Y, Kamiyama K, Shitamichi M : Downbeat nystagmus with compression of the medulla oblongata by the dolichoectatic vertebral arteries. *Am J Otol* 16 : 377-381, 1995
8. Jacobson DM, Corbett JJ : Downbeat nystagmus associated with dolichoectasia of the vertebral artery. *Arch Neurol* 46 : 1005-1008, 1989
9. Kobayashi T, Ogawa A, Kameyama M, Uenohara H, Yoshimoto T : Chiari malformation with compression of the medulla oblongata by the vertebral arteries. *J Neurosurg* 77 : 307-309, 1992
10. Lee AG : Downbeat nystagmus associated with caudal brainstem compression by the vertebral artery. *J Neuroophthalmol* 21 : 219-220, 2001
11. Perderson RA, Troost TT, Abel LA, Zorub D : Intermittent downbeat nystagmus and oscillopsia reversed by suboccipital craniectomy. *Neurology* 30 : 1239-1242, 1980
12. Rosengart A, Hedges TR III, Teal PA, DeWitt LD, Wu JK, Wolpert S, et al : Intermittent downbeat nystagmus due to vertebral artery compression. *Neurology* 43 : 216-218, 1993
13. Sacks JG, Lindenburg R : Dolicho-ectatic intracranial arteries : symptomatology and pathogenesis of arterial elongation and distension. *Johns Hopkins Med J* 125 : 95-106, 1969
14. Saul RF, Selhorst JB : Downbeat nystagmus with magnesium depletion. *Arch Neurol* 38 : 650-652, 1981
15. Shaw HE, Smith JL : Downbeat nystagmus, A clinical update in Smith JL (ed), *Neuro-ophthalmology Update 1980* : 433-436, 1979
16. Smoker WRK, Corbett JJ, Gentry LR, Keyes WD, Price MJ, McKusker S : High-resolution computed tomography of the basilar artery, 2 vertebral arteries : clinical-pathologic correlation and review. *Am J Neuroradiol* 7 : 61-72, 1986
17. Spooner JW, Baloh RW : Arnold-Chiari malformation improvement in eye movements after surgical treatment. *Brain* 104 : 51-60, 1981
18. Traviesa DC : Magnesium deficiency, A possible cause of thiamine refractoriness in Wernicke-Korsakoff encephalopathy. *J Neurol Neurosurg Psychiatry* 37 : 959-962, 1974
19. Yee RD, Baloh RW, Honrubia V : Episodic vertical oscillopsia and downbeat nystagmus in a Chiari malformation. *Arch Ophthalmol* 102 : 723-725, 1985
20. Zee DS, Friendlich AR, Robinson DA : The mechanism of downbeat nystagmus. *Arch Neurol* 30 : 227-237, 1974