

Clinical Experience of Traumatic C7-T1 Spondyloptosis

Dong-Geun Lee, M.D., Soo Hyun Hwang, M.D., Chul Hee Lee, M.D., Dong-Ho Kang, M.D.

Department of Neurosurgery, Gyeongsang National University College of Medicine, Jinju, Korea

Two unusual cases of traumatic spondyloptosis of the cervical spine at the C7-T1 level are reported. One patient was treated with a single-stage combined anterior-posterior and anterior operation to achieve realignment of the cervical spondyloptosis, decompression of the spinal cord and keep of a three-column stabilization of the spine. The other patient was treated with conservative management that consisted of a rigid neck collar and pain control for two months. The patients were managed successfully and both had good neurological outcomes. We present here a summary of the clinical presentations, the surgical technique and results, and a review of the relevant literature.

KEY WORDS : Cervical spondyloptosis · Spinal fusion · Spinal cord compression.

Introduction

The term spondyloptosis is another form of the spine dislocations or advanced spondylolisthesis, in which one spine is lodged in anterior or posterior space of the other one⁷. The frequent causes are trauma, neoplastic, and congenital. Cervical spondyloptosis are rare. Only a few cases have been reported in the literature^{1,10}. The treatment methods may be different depending on the neurologic deficits at the time of the initial examination and the general medical condition of the patient. In this report, we describe two cases of cervical spondyloptosis that were successfully managed, one with surgical treatment and the other with conservative treatment.

Case Report

Case 1

The first case involved a 65-year-old man who fell from a 1.5m height and was transported to our emergency room with complaints of severe neck pain, shoulder pain and a tingling sensation in the right arm. On the neurological examination, the hand grip and finger extension of the right upper extremity were determined to be grade IV and grade III, respectively. Lateral X-rays of the cervical spine revealed a nearly total spondyloptosis at the C7-T1 level. Computed tomography (CT) of the cervical spine disclosed a C7 anterior dislocation (cervical spondyloptosis at C7-T1), locking of the facet joints, a left

lamina fracture, a right pedicle fracture, and a spinous process fracture of C2 (Fig. 1). On a magnetic resonance imaging (MRI) study that was performed 3 days later, progressive spondylolisthesis was detected in addition to the finding of mild cord compression (Fig. 1). Therefore, we decided to perform surgery because of the above mentioned neurological deficits and the radiological instability. We chose to perform anterior decompression before the posterior procedure for the following reasons : first, the ruptured disc material behind spondyloptic corpus should be removed in order to prevent spinal cord compression, and second, a higher rate of solid C7-T1 fusion can be expected with a combined anterior and posterior approach that restores cervical spondyloptosis.

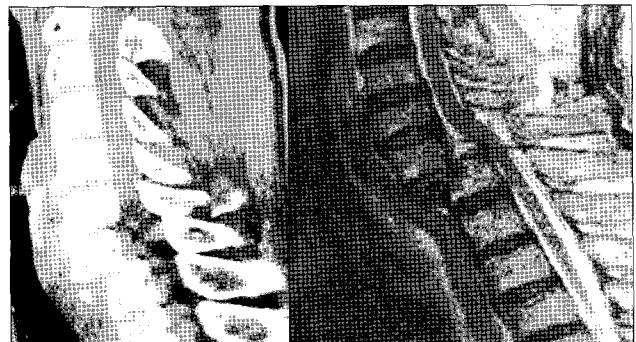


Fig. 1. Computed tomography scan of the cervical spine with sagittal three-dimensional reconstruction and sagittal T2-weighted magnetic resonance image scan demonstrates a large disc compressing the lower cervical cord. There is also a fracture of C7 with an anterior dislocation.

• Received : June 5, 2006 • Accepted : September 20, 2006

• Address for reprints : Dong-Ho Kang, M.D., Department of Neurosurgery, Gyeongsang National University College of Medicine, 90 Chiram-dong, Jinju 660-702, Korea Tel : +82-55-750-8112, Fax : +82-55-759-0817, E-mail : ns4793@hanmail.net

Under the supine position, the fiberoptic intubation was performed, and the neck was extended slightly. An oblique skin incision was performed and the prevertebral space was approached by dissecting the neck muscles. There was a contusion of the longus coli muscle, a stepwise dislocation at C7-T1 and a T1 vertebral body fracture was also found. There was a large amount of ruptured disc material compressing the cord behind the C7 vertebral body. The C7 vertebral body and the ruptured disc material behind the C7 corpus were removed. However, normal cervical alignment was not achieved due to the locked facets of C7-T1. For this reason, a posterior approach was performed after the anterior procedure. After the fractured C7 lamina was removed, an additional C7 laminectomy and bilateral facetectomy were performed because it allowed realignment of the spine. After removal of the fractured lamina, a dural defect and leakage of cerebrospinal fluid (CSF) were detected at the root sleeve and the dural defect was partially repaired partially and this was reinforced with gelform and fibrin glue. Posterior stabilization of C5 to T2 was performed with the C5-C6 lateral mass and T1-T2 transpedicular screws fixation and rod reconstructs. Again, under the supine position of the patient, the C6 and T1 vertebral bodies were exposed, and a C6-T1 anterior interbody fusion was performed with PYRA MESH that was filled with the cancellous bone from the iliac bone and an allobone chip was inserted into the C7 corpectomized site (Fig. 2). On the third day after surgery, bulging and leakage of CSF at the wound site were detected, and so a lumbar puncture was performed and drained for 2 weeks. During the postoperative periods, the patient's tingling sensation of the right arm and the neck and shoulder pain were improved, and the motor power improved to a level higher than the grade IV (hand grip and finger extension). The patient had an uneventful postoperative period and a rigid neck collar was maintained for 2 months.

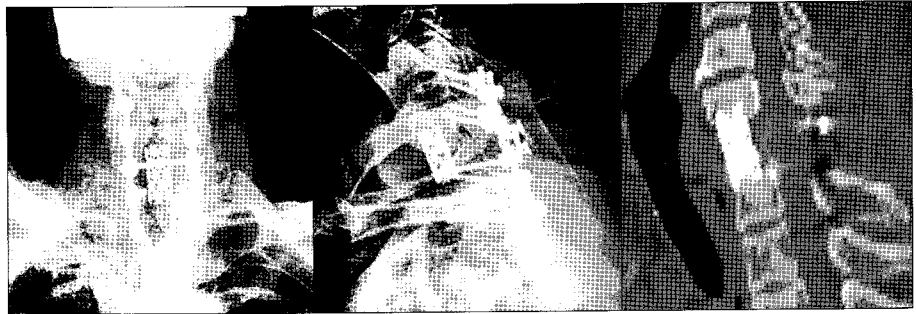


Fig. 2. Postoperative plain radiograph and computed tomography reconstruction of the cervical spine with physiological realignment and anterior and posterior fusion.



Fig. 3. Computed tomography scan of the cervical spine with sagittal three-dimensional reconstruction and sagittal T2 weighted magnetic resonance image scan. There is a fracture of C7 with an anterior dislocation and a large amount of disc material compressing the cervical cord.

the tingling sensation in both arms persisted, an operation was not performed because of refusal on the part of the patient and patient's guardians. Thus, we decided to apply a rigid neck collar without surgery. The tingling sensation improved with conservative management which included active pain control. The patient was discharged and currently he has been followed for 3 months.

Discussion

There are only a few cases of spondyloptosis of the cervical spine reported in the literature^{1,3,8,10}. The etiology of the spondyloptosis in our patients was trauma. This generally results in crushing the spinal cord, which could lead to quadriplegia. Our patients did not have a total cord injury because the posterior element fractures led to a spontaneous dorsal decompression of the spinal canal and this allowed the cord to move posteriorly. Most of the cases of cervical spondyloptosis that were reported in the literature were treated either conservatively^{9,11} or by a posterior fusion alone^{2,4}. In view of the severe degree of displacement, attempting an anatomical reduction was considered to be hazardous. We decided to perform an anterior decompression to prevent any damage to the spinal cord. For our surgical management, a one-stage anterior, posterior and anterior correction, and fusion-stabilization procedure

Case 2

A 72-year-old man who fell from a 5m height off a bridge was transported to our emergency room. The neurological examination revealed complaints of neck pain without motor weakness, but there was a mild tingling sensation in both arms. Lateral X-rays of the cervical spine showed an anterior dislocation (cervical spondyloptosis at C7-T1) and a CT of the cervical spine disclosed locking of the facet joints and focal hyperintensity in the cervicothoracic cord junction (Fig. 3). There was no motor weakness or sensory changes. Although

was performed in order to achieve realignment of the spine without preoperative cervical traction. This surgical method removed the disc material behind the spondyloptic corpus, decreased the risk of spinal cord compression in traction and it allowed solid stabilization of the fusion. Posterior fusion alone was thought to be hazardous. As mentioned above, there are may be any damage to the spinal cord by traumatic disc material with performing only posterior traction, and there must be progression to kyphotic changes that result from instability. Also wide lateral decompression was beneficial in terms of root release, as evidenced by the neurological recovery. This surgical method is the relatively safe due to its low rate of neurologic complications combined with minimal operative disruption. And the one stage anterior, posterior, and anterior fusion could also have allowed the patient to be mobilized very early. Our patient had an excellent short-term neurologic and functional recovery. For the patient who was treated with conservative management, decisive factors such as age and the general physical condition, the degree of neurologic deficits, and the wishes of the patient and the guardians were very important. In our case without a neurologic deficit, and despite meeting the requirements of aggressive surgical treatments (because of a high possibility of developing a delayed onset neurologic deficit and a high risk of developing a neurologic deficit from a subsequent minor trauma), the patient was treated with medical management method because the patient and the patient's guardians did not want surgery. Also including such as this case, progressed spondylolisthesis in the aging chronically without neurologic deficit and spontaneous healing (reduction) of spondylolisthesis¹¹⁾ was treated with medical management. Each cases received either surgical or conservative management, and they were both considered to have been successfully treated.

Conclusion

We report two rare cases of cervical spondyloptosis at C7-T1. The available clinical and morphologic data,

the wishes of the patient, and one's own experience and abilities should be carefully taken into considerations in making a treatment plan. The authors believe that a one-stage operation for correction and fusion-stabilization procedure may a method of great help to the mechanical stabilization and psychological stabilization in future.

References

1. Akay KM, Ersahin Y, Tabur E : Cervical spondyloptosis : case report. *Minim Invas Neurosurg* 45 : 169-172, 2002
2. Bellamy R, Liober A, Smith SD : Congenital spondylolisthesis of the sixth cervical vertebra : case report and description of operative findings. *J Bone Joint Surg (Am)* 56 : 405-407, 1974
3. Bhojraj SY, Orth D, Orth FCPS, Orth MS, Shahane SM, Orth MS : Posttraumatic cervical spondyloptosis at C6-7 with late onset cord compression : a new clinical entity. case report. *J Neurosurg* 77 : 792-794, 1992 : 734-735, 1956
4. Durbin FC : Spondylolisthesis of the cervical spine. *J Bone Joint Surg (Br)* 38 : 734-735, 1956
5. Garneti N, Dunn D, El Gamal E, Williams DA, Nelson IW, Sandemon DR : Cervical spondyloptosis caused by aneurysmal bone cyst : case report. *Spine* 28 : 68-70, 2003
6. Goffin J, Grob D : Spondyloptosis of the cervical spine in neurofibromatosis : case report. *Spine* 24 : 587-590, 1999
7. Lee CW, Hwang SC, Im SB, Kim BT, Shin WH : Traumatic thoracic spondyloptosis : case report. *J Korean Neurosurg Soc* 35 : 622-624, 2004
8. Menku A, Kurtsoy A, Tucer B, Oktem IS, Akdemir H : The surgical management of traumatic C6-7 spondyloptosis in a patient without neurological deficits : case report. *Minim Invas Neurosurg* 47 : 242-244, 2004
9. Perlman R, Hawes LE : Cervical spondylolisthesis. *J Bone Joint Surg (Am)* 33 : 1012-1013, 1951
10. Shah KC, Rajshekhar V : Successful management of posttraumatic C7-T1 spondyloptosis with uninstrumented ventral surgery : case report. *Surg Neurol* 62 : 431-434, 2004
11. Sulla I, Mach P : A patient with spontaneous healing of traumatic spondylolisthesis of the cervical vertebrae : case report. *Rozhl Chir* 80 : 217-219, 2001
12. Wild A, Jager M, Werner A, Eulert J, Krauspe R : Treatment of congenital spondyloptosis in an 18-month-old patient with a 10-year follow-up : case report. *Spine* 26 : 502-505, 2001