

Follow-up Comparison of Two Different Types of Anterior Thoracolumbar Instrumentations in Trauma Cases : Z-plate vs. Kaneda Device

Jung Keun Park, M.D., Keun Su Kim, M.D.

Department of Neurosurgery, Yonsei University College of Medicine, Yongdong Severance Spine Hospital, Seoul, Korea

Objective : In a variety of thoracolumbar diseases, corpectomy followed by interbody bone graft and anterior instrumentation has allowed direct neural decompression and reconstruction of the weight-bearing column by short segments fusion. In this study, we compared spinal stability of the two different anterior thoracolumbar instruments : Z-plate and Kaneda device representing plate and two-rods type, respectively.

Methods : A retrospective review was performed for all the patients with thoracolumbar diseases or traumas treated with anterior corpectomy, autologous iliac bone graft, and fixation with instruments from 1996 to 2000. For the anterior instrumentation, Z-plate or Kaneda device was used for 24 (M:F=5:9, average age=37) and 12 (M:F=9:3, average age=41) patients, respectively. The plain AP and lateral flexion-extension films were taken immediately after surgery and at each follow-up. The sagittal and coronal Cobb's angles at the operation segments were used to observe the change of initial fixation status. The surgical time length and bleeding amount of the two groups were compared. Intra-operative and post-operative instrument-associated complications were evaluated. Student t-test was used for statistical analysis and p-value less than 0.05 was considered to be significant.

Results : Mean follow-up durations for Z-plate and Kaneda device were 24 and 21 months, respectively. The fusion rate was 91% for Z-plate and 100% for Kaneda device. Two cases of Z-plate group showed instrumentation failure during the follow-up period, in which additional surgery was necessary. The mean differences of sagittal Cobb's angles among the AP images immediate after surgery and at follow-up were 7 and 2 degrees for Z-plate and Kaneda device, respectively ($p < 0.05$). The mean differences of coronal Cobb's angles were 5 and 2 degrees for Z-plate and Kaneda device, respectively ($p < 0.05$). No intra-operative complication has occurred in both groups. There was no difference in surgery time and bleeding amount between two groups.

Conclusion : We think that Kaneda device (rod type) is stronger than Z-plate (plate type) to keep the spinal stability after anterior thoracolumbar surgery.

KEY WORDS : Kaneda device · Z-plate · Anterior thoracolumbar surgery · Thoracolumbar trauma.

Introduction

There have been a variety of options in selecting a surgical technique to treat thoracolumbar spinal trauma. Anterior approach for the thoracolumbar spinal trauma is one of the excellent choices. Many investigators have reported favorable results from anterior decompression by direct removal of the fragments of the vertebral body from the spinal canal^[2,7,11,13,14,17,18]. The anterior approach provides more visibility of many forms of surgical pathology and easier procedure to achieve acceptable reduction and fixation than the other fixation procedures in

thoracolumbar injuries.

Most anterior spinal instrumentation systems are composed of screws and screw-connecting instruments. Screw-connecting systems can be divided into two styles, plate or dual rods. These two major types of anterior plates and dual rod systems have been readily accepted for their versatility and ease of use, and each has advantages. Many authors have reported on the biomechanical characteristics of various anterior spinal instrumentation systems^[1,5,6,8,12]. However there have been a few published reports on comparing the anterior plate styles with rod styles in terms of clinical follow-up.

• Received : June 28, 2006 • Accepted : October 4, 2006

• Address for reprints : Keun Su Kim, M.D., Department of Neurosurgery, Yonsei University College of Medicine, Spine Center, 146-92 Dogok-dong, Gangnam-gu, Seoul 135-720, Korea Tel : +82-2-3497-3390 Fax : +82-2-3461-9229, E-mail : spinekks@yumc.yonsei.ac.kr

In this study, we compared spinal stability with the two different types of anterior thoracolumbar instruments : Z-plate (SofamorDanek, Memphis, TN). and Kaneda device (DePuy spine, Raynham, MA) representing plate and two-rods type, respectively.

Materials and Methods

A retrospective review was carried out for the patients with thoracolumbar traumas treated by anterior surgery from May 1996 to July 2000. Thirty-six patients were treated by anterior thoracolumbar approach. All surgical procedures were performed through transthoracic, extrapleural retroperitoneal combined or retroperitoneal approach. Autologous iliac bone graft and anterior instrumentation were performed after corpectomy of fractured vertebrae for all patients.

The fractured thoracolumbar levels were one T5, one T9, one T10, four T12, nineteen L1 and ten L2. According to the Denis classification system, fracture types were as followed; 2 compression fractures, 32 burst fractures, and 2 fracture-dislocations. The causes of injuries were fall down in 14 of patients, motor-vehicle accidents in 20, paragliding trauma in 1, and a direct crushing injury during the job in 1.

All the patients had preoperative AP and lateral radiographs and CT scans. For the anterior instrumentation, the patients were divided into two groups : Z group of 24 patients for Z-plate system (M : F = 15 : 9, average age = 37) and K group of 12 patients for Kaneda device (M : F = 9 : 3, average age = 41). The selection of instrument was decided randomly without any consideration of injury site or patient status. The plain AP and lateral flexion-extension films taken immediately after surgery were compared with the films taken at the time of follow-up. Sagittal and coronal Cobb's angles at the operation segments were used to observe the change of initial fixation status. The fusion status was estimated using flexion and extension dynamic plain X-ray films.

The criteria for successful interbody fusion were that there were no radiolucent gap between vertebral bodied and grafts and no more than 5-degree difference between flexion and extension lateral X-ray images. Intra-operative and post-operative instrument-associated complications were evaluated. Student t-test was used for statistical analysis and p-value less than 0.05 was considered to be significant.

Table 1. Change of Cobb's angles, operation time and blood loss for Kaneda device and Z-plate

	Kaneda device (12 patients)	Z-plate (24 patients)
Sagittal Cobb's Angle	2°*	7°
Coronal Cobb's Angle	2°*	5°
Operation time (hours)	4.2 ± 0.7 **	3.8 ± 0.8
Blood loss (ml)	580 ± 160 **	650 ± 200

* p<0.05 vs. Z-plate, ** p>0.05 vs. Z-plate

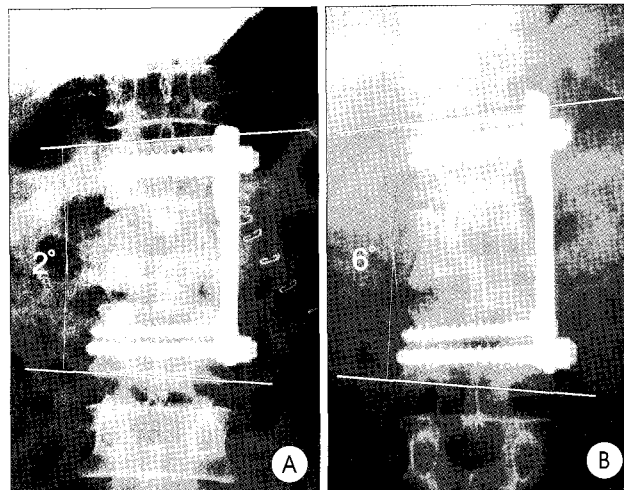


Fig. 1. Change of coronal Cobb's angle with Z-plate fixation for L1 burst fracture. Two degrees of coronal angle immediate after surgery (A) increased to 6 degrees at 23 months after surgery (B).

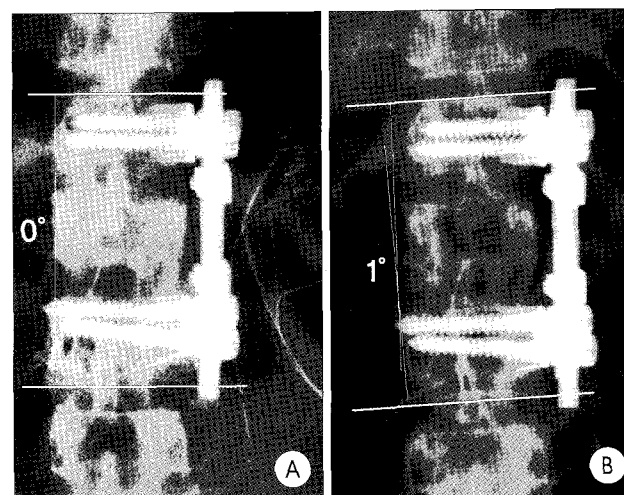


Fig. 2. Change of coronal Cobb's angle with Kaneda device fixation for L1 burst fracture. Coronal Cobb's angle shows no deformity immediate after surgery (A) while it shows 1 degree of angle change 19 months after surgery (B).

Results

Mean follow-up durations for Z and K group were 24 and 21 months, respectively. The mean differences of coronal Cobb's angles were 5 and 2 degrees for Z and K group, respectively (p < 0.05) (Table 1) (Fig. 1, 2). The mean differences of sagittal Cobb's angles between the AP images immediate after surgery and follow-up were 7 and 2 degree for Z and K group, respectively (p < 0.05) (Table 1) (Fig. 3, 4). No intra-operative complication has occurred in both groups. The mean surgical time was 3.8 ± 0.8 hours in Z group, and 4.2 ± 0.7 hours in K group. Mean estimated blood loss

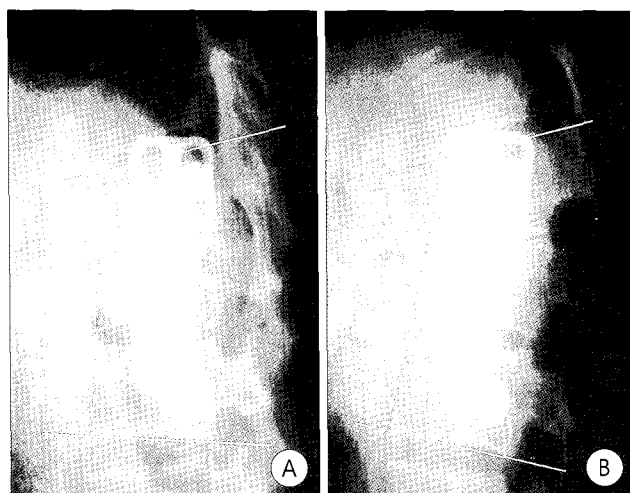


Fig. 3. Change sagittal of Cobb's angle with Z-plate fixation for L1 burst fracture. Nineteen degrees of sagittal angle immediate after fixation (A) increased to 28 degrees at 18 months after surgery (B).

was 650 ± 200 ml in Z group and 580 ± 160 ml in K group. There was no difference in surgical time length and bleeding amount between two groups ($p > 0.05$) (Table 1). The fusion rate was 91% for Z group and 100% for K group. Two instrumentation failure occurred in Z-plate group during the follow-up period, in which additional surgery was necessary (Fig. 5).

Discussion

Many authors contend that anterior surgery results in more complete and reliable decompression of the spinal canal and offers superior mechanical stability in thoracolumbar fractures^{2,7,11,13,14,17,18}. Thus, in cases where canal clearance is mandatory, direct decompression by an anterior or lateral approach is generally recommended¹⁵. In various types of thoracolumbar fractures, reconstruction of weight-bearing anterior column and instrumental stabilization is indicated after neural decompression. The use of spinal instrumentation for internal fixation of the anterior column has improved fusion rates, decreased the rate and relative severity of postoperative deformities, and improved the immediate stability of anterior corpectomies^{2,7,11,13}.

The ideal device for anterior instrumentation requires durable material maintaining the structure of instrumentation until bone fusion, high pull-out strength of the screws, and no effects around the normal anatomical structures. Also it should have the advantages of easy handling and possible post-operative MRI scanning. There is a large array of devices available for internal fixation of the anterior thoracolumbar column, but most systems are designed as either a plate or dual rods system. In this study we compared the Kaneda device with Z-plate. Kaneda et al. developed an anterior fixation device that uses vertebral body staples and screws connected by two longitudinal

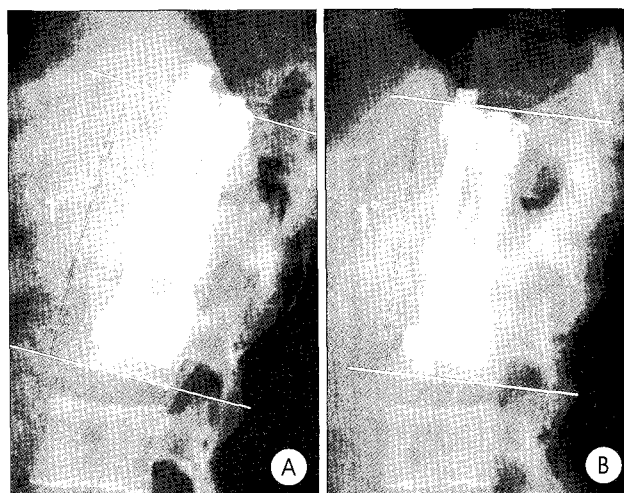


Fig. 4. Change of sagittal Cobb's angle with Kaneda device fixation for L1 burst fracture. Sagittal Cobb's angle (1 degree) shows no change between immediate (A) and 15 months (B) after surgery.

rods that are cross-linked^{10,11}. Z-plate system designed by Z-deblich is consisted of a low-profile plate with two slots and two holes through which bolts and screws are placed^{2,13}.

There have been controversies about stiffness, fatigue fracture, and long-term stability in various anterior thoracolumbar instruments. In biomechanical tests, dual rod designs are known to offer greater adjustability and control over screw placement, increased load sharing and stability than plate system^{1,6,8,12}. Faro et al. compared biomechanically the two different design concepts for anterior thoracolumbar instrumentation; Antares double rods system (Medtronic Sofamor-Danek, Memphis, TN) and Z-plate. The results showed that Antares double rods system was significantly stiffer than Z-plate in flexion, extension, and lateral bending. Hitchon et al compared biomechanically Kaneda device with Synthesis Anterior Thoracolumbar Locking Plate (ATLP, Synthes, Paoli, PA) using human thoracolumbar spine obtained cadaver. They tested flexion, extension, and lateral bending, which showed significantly stiffer Kaneda device than plate system in flexion, extension, and lateral bending. An et al. studied the biomechanical evaluation of four anterior thoracolumbar spinal instrumentation systems (Kaneda device, Z-plate, TSRH, and University Anterior Plating System), in which showed that the Kaneda device was the best particularly in restoring the torsional stability¹. However, Dick et al showed that Z-plate system was less prone to fatigue failure than Kaneda device and TSRH⁹. Brodke et al. studied the thoracolumbar instrumentation and showed that, for both load sharing and stiffness, there is more influence from the design of the instrumentation system than whether it is a plate or rod style system⁴.

Sometimes the result of laboratory biomechanical test could be different from clinical long-term follow up results. So far, there have been a few clinical reports about the comparison

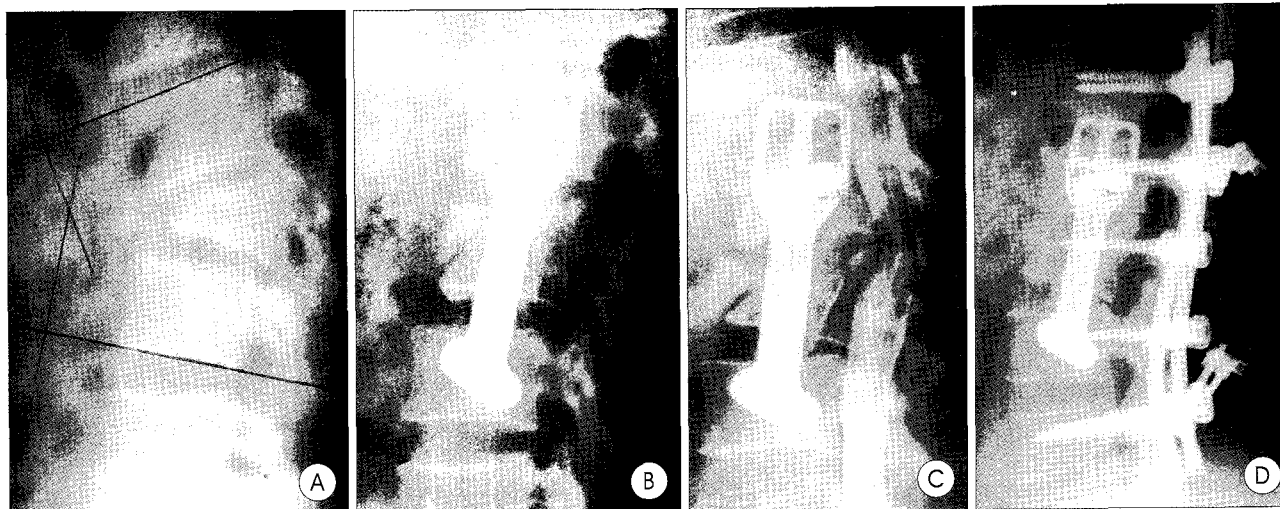

Fig. 5. Z-plate fixation for L1 fracture–dislocation by flexion injury. Single anterior Z-plate fixation for three–column injury (A, B) resulted in instrument failure 13 months later that needed secondary surgery of posterior fusion and instrumentation (C, D).

of long-term stability between these two different systems³⁾. We did this study to confirm the hypothesis that the rod type device might be stiffer than the plate type. We think that there is strong relationship between long-term stiffness of instrument and preservation of initial instrumentation status. The rods of Kaneda device are connected each other with one or two cross-linker, which results in one unified segment of device. The body of Z-plate system is already made of one metallic plate, however, its thickness is less than the diameter of rod of Kaneda device. In this study, Kaneda device showed more stable durability of initial rod-screw angle than Z-plate, which means that screws connected with big diameter rods are stronger than screws with thin plate. In other words, this can be explained by the fact that rod-screw of Kaneda device has larger contact surface than plate-screw surface of Z-plate.

In spite of weakness of Z-plate in long-term clinical stability, it has still advantages like low profile and easy instrumentation^{2,3,13)}. Actually, in this study, most Z-plate system showed stable fused segments even though Z-plate showed more deformed sagittal and coronal screw-plate angle changes than Kaneda device. Thus, it seems reasonable to suggest that because most of the common anterior instrumentation designs share similar characteristics, ease of use and surgeon's familiarity with a particular system may be more important than the material capabilities of each particular implant. However, in our cases, the major instability problems of Z-plate occurred in the surgery of unstable 3-column injuries (Fig. 5). Anterior and posterior combined surgery is usually more recommended than any single anterior or posterior approach in 3-column injury because it provides the highest strength^{9,16)}. In certain clinical situations, a surgeon may want single anterior surgery. In those situations, we think that rod type instrument is suitable for the single anterior surgery of 3-column thoracolumbar injury.

The surgical time length and bleeding amount is almost the same in both Z-plate and Kaneda device. Kaneda device requires additional time, about 20 minutes more than Z-plate, to fix vertebral spike plate and cross-linker connection. However, we think it is not clinically significant. The fusion rates of these two systems have been reported as 93-100%^{2,3,11,13)}. In our study, Kaneda device showed better fusion rate than Z-plate. The fusion rate can be different from each other due to surgical technique, graft material or the instrument device. But we consider that the different characteristics of instruments determining long-term stabilization can be one of the factors contributing a better fusion rate.

Conclusion

Kaneda device (rod type) is better for stabilization than Z-plate (plate type) maintaining the spinal reconstruction status with a higher fusion rate after anterior thoracolumbar surgery.

References

1. An HS, Lim TH, You JW, Hong JH, Eck J, McGrady L : Biomechanical evaluation of anterior thoracolumbar spinal instrumentation. *Spine* 20 : 1979-1983, 1995
2. Aydin E, Solak AS, Tuzuner MM, Benli IT, Kis M : Z-plate instrumentation in thoracolumbar spinal fractures. *Bull Hosp Jt Dis* 58 : 92-97, 1999
3. Benli IT, Alanay A, Akalin S, Kis M, Acaroglu E, Ates B, et al : Comparison of anterior instrumentation systems and the results of minimum 5 years follow-up in the treatment of tuberculosis spondylitis. *Kobe J Med Sci* 50 : 167-180, 2004
4. Brodke DS, Golligly S, Bachus KN, Alexander Mohr R, Nguyen BK : Anterior thoracolumbar instrumentation : stiffness and load sharing characteristics of plate and rod systems. *Spine* 28 : 1794-1801, 2003
5. Dick JC, Brodke DS, Zdeblick TA, Bartel BD, Kunz DN, Rapoff AJ : Anterior instrumentation of the thoracolumbar spine. A biomechanical comparison. *Spine* 22 : 744-750, 1997
6. Faro FD, White KK, Ahn JS, Oka RS, Mahar AT, Bawa M, et al : Bio-

- mechanical analysis of anterior instrumentation for lumbar corpectomy. *Spine* 28 : E468-471, 2003
7. Ghanayem AJ, Zdeblick TA : Anterior instrumentation in the management of thoracolumbar burst fractures. *Clin Orthop Relat Res* : 89-100, 1997
 8. Hitchon PW, Goel VK, Rogge T, Grosland NM, Torner J : Biomechanical studies on two anterior thoracolumbar implants in cadaveric spines. *Spine* 24 : 213-218, 1999
 9. Kanayama M, Ng JT, Cunningham BW, Abumi K, Kaneda K, McAfee PC : Biomechanical analysis of anterior versus circumferential spinal reconstruction for various anatomic stages of tumor lesions. *Spine* 24 : 445-450, 1999
 10. Kaneda K, Abumi K, Fujiya M : Burst fractures with neurologic deficits of the thoracolumbar-lumbar spine. Results of anterior decompression and stabilization with anterior instrumentation. *Spine* 9 : 788-795, 1984
 11. Kaneda K, Taneichi H, Abumi K, Hashimoto T, Satoh S, Fujiya M : Anterior decompression and stabilization with the Kaneda device for thoracolumbar burst fractures associated with neurological deficits. *J Bone Joint Surg* 79A : 69-83, 1997
 12. Korani Y, Cunningham BW, Parker LM, Kanayama M, McAfee PC : Static and fatigue biomechanical properties of anterior thoracolumbar instrumentation systems. A synthetic testing model. *Spine* 24 : 1406-1413, 1999
 13. McDonough PW, Davis R, Tribus C, Zdeblick TA : The management of acute thoracolumbar burst fractures with anterior corpectomy and Z-plate fixation. *Spine* 29 : 1901-1908; discussion 1909, 2004
 14. Park SY, Lee WG, Kim KH, Choi JH, Lee IC, Bae SD, et al : Clinical analysis of anterolateral approach with instrumentation for the thoracolumbar lesions. *J Korean Neurosurg Soc* 28 : 203-208, 1999
 15. Shono Y, McAfee PC, Cunningham BW : Experimental study of thoracolumbar burst fractures. A radiographic and biomechanical analysis of anterior and posterior instrumentation systems. *Spine* 19 : 1711-1722, 1994
 16. Wilke HJ, Kemmerich V, Claes LE, Arand M : Combined anteroposterior spinal fixation provides superior stabilisation to a single anterior or posterior procedure. *J Bone Joint Surg* 83B : 609-617, 2001
 17. Woo BG, Bae JH, Kim SH, Kim OL, Choi BY, Cho SH : Clinical evaluation of anterolateral surgical decompression and instrumentation in thoracolumbar bursting fracture. *J Korean Neurosurg Soc* 28 : 174-180, 1999
 18. Yoo CJ, Kang DS, Chung HY, Kim YB, Ahn SG, Park CW : Anterolateral instrumentation and spinal stabilization of thoracolumbar burst fracture. *J Korean Neurosurg Soc* 25 : 1217-1222, 1996

Commentary

This study showed a good comparative result of two different devices for the anterior thoracolumbar instrumentation. Despite of the outstanding effort, a few points need to be added. The fractures were classified by the Dennis classification, which is classical and easy classification. Although

the Dennis classification gains the popularity, recent understanding of the biomechanics requires new description for the classification. Moreover, the author reported 32 burst fractures, no distraction injury, and 2 fracture-dislocations. The fracture-dislocation is three-column injury. The anterior instrumentation without posterior augmentation for this injury is generally not recommended. The indication for the anterior instrumentation for this study had to be defined according to the injury classification.

Recent understandings of biomechanics of the spine emphasize the integrity of the posterior ligamentous complex for the spinal stability, which includes the supraspinal ligament, interspinous ligament, ligamentum flavum, and facet joint capsule¹⁾. Injured posterior ligamentous complex is recommended the posterior instrumentation instead of anterior approach²⁾. 2 failed-fusion cases of Z-plate were L1 burst fracture and L1 fracture-dislocation. Because L1 vertebra is thoracolumbar junction, it is placed under unique forces and mobility. If 2 failed cases had been injured the posterior ligamentous complex, the anterior-only instrumentation would be prone to the fusion failure. The circumferential or posterior fusion could restore the stability instead of the anterior approach. Therefore, it is suggested that the responsibility of the fusion failure would not be the instrument type but the selection of the approach.

Ki-Hong Cho, M.D.

Department of Neurosurgery, Ajou University Hospital

References

1. Lee JY, Vaccaro AR, Lim MR, Oner FC, Hulbert RJ, Hedlund R, et al : Thoracolumbar injury classification and severity score : a new paradigm for the treatment of thoracolumbar spine trauma. *J Orthop Sci* 10 : 671-675, 2005
2. Vaccaro AR, Lim MR, Hurlbert RJ, Lehman RA Jr, Harrop J, Fisher DC, et al : Spine Trauma Study Group : Surgical decision making for unstable thoracolumbar spine injuries : results of a consensus panel review by the Spine Trauma Study Group. *J Spinal Disord Tech* 19 : 1-10, 2006