

Microsurgical Selective Obturator Neurotomy for Spastic Hip Adduction

Yeul-Bum Park, M.D.,¹ Seong-Ho Kim, M.D.,¹ Sang-Woo Kim, M.D.,¹
Chul-Hoon Chang, M.D.,¹ Soo-Ho Cho, M.D.,¹ Sung-Ho Jang, M.D.²

Departments of Neurosurgery,¹ Rehabilitation Medicine,² College of Medicine, Yeungnam University, Daegu, Korea

Objective : Cerebral palsy may induce harmful spastic hip adduction. We report the result of microsurgical selective obturator neurotomy, performed on 12 spastic hip adductions of 6 patients, followed clinically for at least 26 months postoperatively.

Methods : Microsurgical selective obturator neurotomies, involving microsurgical resection of the anterior obturator nerve branches were performed on 6 patients from January 2000 through June 2003. All patients presented with the inability to sit and 2 patients complained of persistent, intractable pain. We used intraoperative bipolar stimulation to identify selected motor branches.

Results : The procedure was performed bilaterally in all patients. In the 3 patients in whom contractures were present, microsurgical selective obturator neurotomies were accompanied by an additional tenotomy of the adductor muscles. Selective tibial neurotomy was performed on three of six patients who originally presented with a spastic ankle. Postoperatively, all spastic hip adductions were corrected more than 60 degrees in passive abduction-adduction amplitude. However, one patient who did not receive active postoperative physiotherapy demonstrated a decreased passive abduction-adduction amplitude upon follow-up. There were no surgical complications.

Conclusion : We think microsurgical selective obturator neurotomy may be an effective procedure in the treatment of localized, harmful spastic hip adduction after failure of well conducted conservative treatment. As muscular contractions are often associated with spasticity of the hip adductors, an adjunctive tenotomy may be an option. Comprehensive postoperative physiotherapy is essential to improve long-term results.

KEY WORDS : Cerebral palsy · Spasticity · Hip adduction · Microsurgical selective obturator neurotomy.

Introduction

In children with cerebral palsy, spasticity is a severe handicapping sequelae¹⁹⁾. Despite early, regular physical therapy and rehabilitation associated with antispasmodic medications and various local block techniques, the effects of spasticity on the growing body in many cerebral palsy children will lead to a severe motor handicap, making standing and walking impossible¹⁹⁾. The main features of the spastic hip include adduction, flexion, and internal rotation. They are harmful at rest and during walking, and threaten the stability of the hip. Adduction especially can lead to coxa valga, subluxation, and subsequent hip dislocation.

An adductor tenotomy, with an anterior obturator neurotomy is a considerable procedure to correct spasticity²⁵⁾. This approach provides an alignment of the hip for the crutch gait,

prevents subluxation and dislocation of the hip, and facilitates nursing care. Here, we report the long-term results of microsurgical selective obturator neurotomy performed on six patients with spastic hip adduction, followed clinically for at least 24 months postoperatively.

Materials and Methods

From January 2000 through June 2003, twelve spastic hip adductions of six patients treated for correction of adduction and internal rotation of the hip were included in this study. Cerebral palsy was the cause of each patient's spasticity. All patients had received prolonged physical therapy and most were referred to neurosurgery from the rehabilitation clinic. Complete assessment of each patient was completed by both the neurosurgeon and the physiotherapist. The examiners

• Received : August 21, 2006 • Accepted : September 30, 2006

• Address for reprints : Seong-Ho Kim, M.D., Department of Neurosurgery, College of Medicine, Yeungnam University, 317-1 Daemyeong-dong, Nam-gu, Daegu 705-717, Korea Tel : +82-53-620-3790 Fax : +82-53-620-3770, E-mail : shkim@med.yu.ac.kr

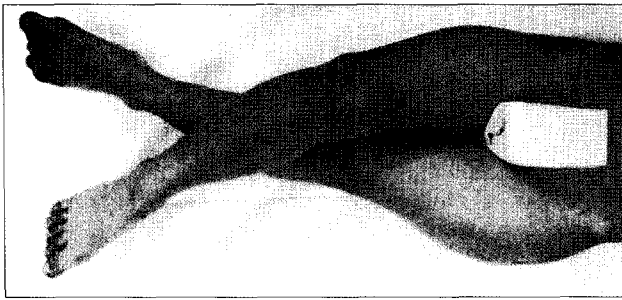


Fig. 1. Preoperative spastic hip joints photograph. It shows crossing of the legs.

took careful note of other features of cerebral palsy, such as motor weakness, trunk control, poor balance and fixed contractures, all of which are factors affected by the final results of the neurotomy. X-rays were taken of involved joints, and in some patients total spine and pelvic x-rays were taken, as well. The population composed of 3 males and 3 females, and mean age was 14 years old from 5 to 33 aged. All patients had crossing of the legs and were unable to sit and walk (Fig. 1). In addition, both adults had fixed bilateral hip joint contractures with persistent intractable pain. One child had right hip dislocation (Table 1).

The goal of the microsurgical selective obturator neurotomy was to microsurgically resect 50~75% of the anterior branches of the obturator nerve (Fig. 2). Coagulation of the proximal nerve ending was performed in order to prevent the re-growth and possible neuroma formation. We used intraoperative bipolar stimulation to identify selected motor branches, innervating the selected spastic muscles responsible for the patient's abnormal posture and functional handicaps. An additional tenotomy of adductor muscles was performed in cases in which immediate post-neurotomy passive abduction-adduction amplitude did not exceed 60 degrees. A selective tibial neurotomy

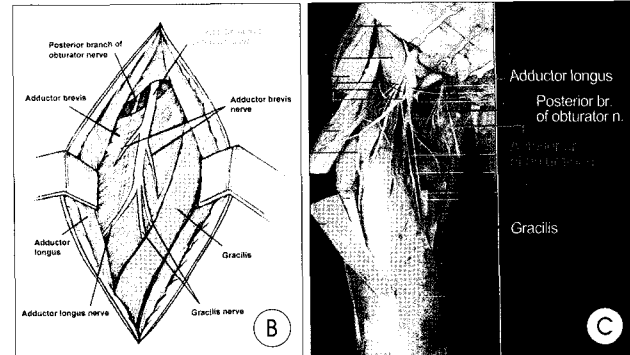
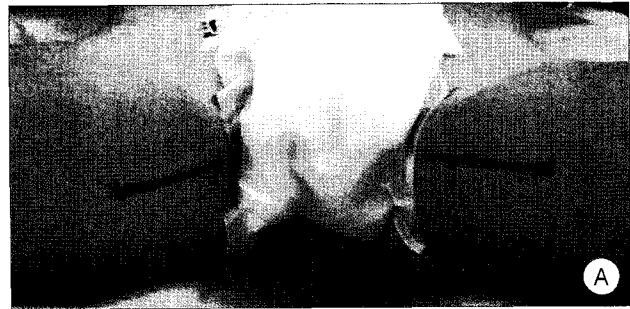


Fig. 2. A : The skin incision of bilateral selective obturator neurotomy. B : Schematic diagram demonstrating the dissection of the anterior branch of the right obturator nerve. The adductor longus is retracted laterally and the gracilis medially. The anterior branch of the obturator nerve lies under the adductor brevis. The posterior branch of the obturator nerve lies under the adductor longus. C : The anterior branch of the obturator nerve in cadaver from Rohen and Yokochi(eds) : Color atlas of anatomy. Igaku-Shion, New York, 1983, p387.

was performed after the obturator neurotomy on those patients with a spastic ankle who did not have concomitant fixed contractures or dislocations.

The surgical outcome was rated both immediately after operation and at last out patient department follow up as follows : "Good" if passive abduction-adduction amplitude was consistently greater than 60 degrees; "Fair" if 41-60 degrees; and, "Poor" if less than 40 degrees.

Physiotherapy was started two weeks after surgery, with the application of an electrical stimulation program component for most of the patients.

Results

Postoperatively, all patients had improved weight-bearing in the sitting position and a decrease in the severity of the intractable pain (Fig. 3). The two adults who had bilateral hip joint contractures and the one child who had a right hip dislocation showed immediate

Table 1. Long-term surgical results of microsurgical selective obturator neurotomy

No	Age/Sex	Etiology	Obturator neurotomy	Additional tenotomy	STN	Cx.	F/U	Final Result
1	7/F	CP	Rt.	Yes	No	-	48Mo	Good*
			Lt.	No	No			Good
2	6/F	CP	Rt.	No	Yes	-	43Mo	Good
			Lt.	No	Yes			Good
3	33/F	CP	Rt.	Yes	No	-	35Mo	Fair†
			Lt.	Yes	No			Fair†
4	25/M	CP	Rt.	Yes	No	-	32Mo	Good
			Lt.	Yes	No			Good
5	8/M	CP	Rt.	No	Yes	-	29Mo	Good
			Lt.	No	Yes			Good
6	5/M	CP	Rt.	No	Yes	-	26Mo	Good
			Lt.	No	Yes			Good

CP, cerebral palsy; Rt., right; Lt., left; STN, selective tibial neurotomy; Cx., complications; F/U, follow-up; Mo, months; Good* : passive abduction-adduction amplitude greater than 60 degrees, Fair† : from 41 to 60 degrees (good at immediate postoperative and 16 months follow-up but decreased passive abduction-adduction amplitude over 60 degrees to 45 degrees at 35 months follow-up)



Fig. 3. Postoperative photograph shows good weight-bearing in the sitting position.

post-neurotomy passive abduction-adduction amplitude not exceeding 60 degrees. In this five obturator neurotomies requiring additional tenotomy of the adductor muscles, the amplitude exceeded 60 degrees. Three of the children who did not have fixed hip joint contractures or dislocations showed immediate postneurotomy passive abduction-adduction amplitude over 60 degrees. After obturator neurotomy wound care, the children with spastic ankle underwent bilateral selective tibial neurotomy. After active physiotherapy, each child was able to walk without major difficulty.

There were no surgical complications. However, at a 35 months postoperative follow-up examination, one female patient experienced a decreased in the passive abduction-adduction amplitude, from approximately 60 degrees to 45 degrees. She did not receive active physiotherapy postoperatively. Nevertheless, she was pain-free (Table 1).

Discussion

Hip adduction is the most commonly affected movement in patients with cerebral palsy³². In those who are severely affected and unable to walk, it gradually but inexorably leads to subluxation and subsequent dislocation, resulting in disastrous functional consequences^{14,27,30}. Hip dislocations lead to difficulty sitting, intractable pain, and perineal care problems^{18,29}. Many factors contribute to hip subluxation and dislocation, such as coxa valga, pelvic obliquity, and acetabular shallowness secondary to the absence of weight-bearing^{3,18,29}. The main factor, however, is muscle imbalance, which produces adduction and flexion deformities, shifting the axis of rotation of the hip towards the lesser trochanter and decreasing femoral head coverage^{9,18,29}.

The incidence of dislocation of the hip in patients with severe cerebral palsy is between 60% and 80%^{10,14,20}. It has also been shown that as many as 50% of these dislocated hips become painful for the patients²⁷. Physical therapy, oral pharmacologic therapy, subarachnoid infusion of baclofen^{1,6}, chemical ne-

urolytic blocks³¹, cryoneurolysis¹² and orthopedic and neurosurgical techniques have been used to manage spasticity due to cerebral palsy. Oral pharmacologic therapy is frequently ineffective or only partially effective or associated with untoward and intolerable side effects. Some authors reported that this may be the reason for the increasing popularity of implanted systems for subarachnoid infusion of baclofen³¹. However, under our national medical insurance, this procedure is not covered; therefore, this procedure is not commonly used. Chemical neurolysis with alcohol or phenol is frequently used to manage spasticity but is associated with the risk of neuralgia, deafferentation pain, and unintentional soft-tissue injury secondary to neurolytic agent spread to adjacent tissues³¹. Dorsal root entry zontomy by the selective destroying mainly the laterally located nociceptive and centrally located myotactic afferent fibers within the posterior root relieves the spasticity of the limbs¹³. Selective posterior rhizotomy can also be applied to cerebral palsy spasticity^{5,11}.

Microsurgical selective peripheral neurotomy in patients with cerebral-palsy is considered an effective surgical treatment for many localized forms of handicapping spasticity^{8,28}. Microsurgical techniques have improved over the years, intraoperative stimulation which contributes largely to the functional improvement has become an important adjunct procedure¹⁹. The stimulation provides a very precise degree of spasticity release and is highly selective since it involves the fascicles in close proximity to the innervated muscle. This advantage helps the avoid excessive manipulation of sensitive fascicles that may result in possible painful and trophic side effects. The 7 to 10mm nerve resection with proximal resection end coagulation helps prevent re-growth and possible neuroma formation. Recurrence is becoming very rare with this technique, as was already demonstrated by Sindou and Mertens²⁸. Cooperation with the physiotherapist is very important in order to achieve optimal postoperative results. In our study, the one patient that did not receive physiotherapy decreased passive abduction-adduction amplitude from approximately 60 degrees to 45 degrees.

The patient with total involvement has marked spasticity in all four extremities, rarely is able to walk, and frequently has deformities of both the spine and the hips. For a patient with cerebral palsy, sitting requires at least 90 degrees of flexion in the hip joint and a relatively straight back. Either scoliosis or a painful dislocated hip, or both, can decrease the patient's ability to sit. The hip deformities in the patient with total involvement may progress to painful dislocations which can affect the ability to sit for long periods and complicate perineal care^{21,22}. Spastic deformities are initially the result of muscle tone alone. The degree of muscle tone is difficult to quantitate, as it varies with the position of adjacent joints and body posture. Eventually, the spastic deformities can result in fixed musc-

ulotendinous contractures that may progress to fixed joint contractures. Finally the hip may dislocate, the usual direction is posterior, due to the overactivity of the adductors and flexors of the hip⁹.

In patients who are able to walk, overactive adductors may cause a decrease in the width of the gait, which can increase the likelihood of crossing of the legs and tripping. Release of the adductor longus or gracilis or adductor transfers to the ischium are both accepted methods of increasing the width of gait when adductor tone alone is the problem^{23,24,26}. Problems related to hyperabduction after anterior obturator neurotomy have received attention in the literature. However, hyperabduction of the hip due to postoperative hip adductor insufficiency presents several problems. An anterior obturator neurotomy may destroy all function of the gracilis, adductor longus, and adductor brevis¹⁶. Total dysfunction of these adductors combined with iliopsoas division leads to adduction insufficiency and, hence, hyperabduction.

The adductor brevis plays an important role in the stability of the hip. Clinically, once the adductor brevis no longer functions after obturator neurotomy, movement worsens, resulting in a broad-based gait. Reconstructive surgery is extremely difficult¹⁵. Some authors reported that an anterior branch obturator neurotomy should be avoided in children who can walk because of the potential for developing a wide based gait and hyperabduction¹⁷ and should be reserved for patients who have marked fixed contractures with subluxation or recurrent contractures⁹. However, in patients who also have a fixed adductor contracture that prohibits abduction of more than 30 degrees, whether or not the patient is able to walk, the adductor brevis should be released and an obturator neurotomy should be considered³². The participants in our study did not develop hyperabduction or broad-based gait. Another possible complication of the procedure in non-ambulatory patients is the production of a fixed extension contracture⁴, resulting in difficulty with sitting and eventual anterior dislocation of the hip. Thus, these procedures should be done with care in such patients and only when there are fixed contractures in flexion, without extensor thrust.

It is hoped that the use of appropriate soft-tissue procedures, when necessary, will prolong their ability to walk and decrease their pain over the years. And orthopedic surgeries including osteotomies and hip joint surgery are considered in cases involving severe contracture and in cases of insufficient of soft tissue surgery.

Conclusion

We think microsurgical selective obturator neurotomy may be an effective procedure in the treatment of loc-

alized harmful spastic hip adduction after failure of well-conducted conservative treatment associating physiotherapy and antispasmodic medications. We believe that this procedure must be performed at a young age, before the fixed deformities and other orthopedic complications like as contracture and hip joint dislocation compromising walking ability. For muscular contractions, associated with hip adductor spasticity, a tenotomy may be an effective adjunct to the obturator neurotomy for good result. Intensive pre- and post-operative physiotherapy is necessary to achieve maximal postoperative results.

References

- Albright AL, Barron WB, Fasick P, Polinko P, Janosky J : Continuous intrathecal baclofen infusion for spasticity of cerebral origin. *JAMA* 270 : 2475-2477, 1993
- Bagg MR, Farber J, Miller F : Long-term follow-up of hip subluxation in cerebral palsy patients. *J Pediatr Orthop* 13 : 32-36, 1993
- Black BE, Griffin PP : The cerebral palsied hip. *Clin Orthop* 338 : 42-51, 1997
- Bowen JR, MacEwen GD, Mathews PA : Treatment of extension contracture of the hip in cerebral palsy. *Dev Med Child Neurol* 23 : 23-29, 1981
- Choi JU, Yoon SH, Kim EY, Kim SH, Park CI : Selective Posterior Rhizotomy in the Cerebral Palsy Spasticity. *J Korean Neurosurg Soc* 22 : 715-722, 1993
- Chung YK, Lim CS, Chung HS, Lee HG, Lee KC, Chu JW : Effects of Intrathecal Baclofen on Spasticity. *J Korean Neurosurg Soc* 18 : 59-65, 1989
- Cooperman DR, Bartucci E, Dietrick E, Millar EA : Hip dislocation in spastic cerebral palsy : long term consequences. *J Pediatr Orthop* 7 : 268-276, 1987
- Decq P, Filippetti P, Feve A, Djindjian M, Saraoui A, Keravel Y : Peripheral selective neurotomy of the brachial plexus collateral branches for treatment of the spastic shoulder : Anatomical study and clinical results in five patients. *J Neurosurg* 86 : 648-653, 1997
- Hoffer MM : Management of the hip in cerebral palsy. *J Bone Joint Surg Am* 68 : 629-631, 1986
- Howard CB, McKibbin B, Williams LA, Mackie I : Factors affecting the incidence of hip dislocation in cerebral palsy. *J Bone Joint Surg Br* 67 : 530-532, 1985
- Kim BI, Choi HY, Kim YH, Lee JC : Selective Posterior Rhizotomy (SPR) for Treatment of Spasticity in the Patient with Cerebral Palsy. *J Korean Neurosurg Soc* 23 : 1268-1275, 1994
- Kim PS, Ferrante FM : Cryoanalgesia: a novel treatment for hip adductor spasticity and obturator neuralgia. *Anesthesiology* 89 : 534-536, 1998
- Kim YS, Kim BT, Shin WH, Choi SK, Byun BJ : The Efficacy of Dorsal Root Entry Zone (DREZ) Lesions Making for Intractable Pain and DREZotomy for Intractable Spasticity. *J Korean Neurosurg Soc* 24 : 143-150, 1995
- Lonstein JE, Beck K : Hip dislocation and subluxation in cerebral palsy. *J Pediatr Orthop* 6 : 521-526, 1986
- Matsuo T, Hajime T, Tada S, Fujii T, Hara H : The role of hip adductors for adduction contracture of the hip in cerebral palsy[in Japanese]. *Seideigeka(Orth Surg)* 35 : 1265-1272, 1984
- Matsuo T, Tada S, Hajime T : Insufficiency of the hip adductor after anterior obturator neurotomy in 42 children with cerebral palsy. *J Pediatr Orthop* 6 : 686-692, 1986
- Miller F, Dias RC, Dabney KW, Lipton GE, Triana M : Soft-tissue release for spastic hip subluxation in cerebral palsy. *J Pediatr Orthop* 17 : 571-584, 1997
- Moreau M, Cook PC, Ashton B : Adductor and psoas release for subluxation of the hip in children with spastic cerebral palsy. *J Pediatr Orthop* 15 : 672-676, 1995
- Msaddi AK, Mazroue AR, Shahwan S, al Amri N, Dubayan N, Livinston D, et al : Microsurgical selective peripheral neurotomy in the treatment

- of spasticity in cerebral-palsy children. *Stereotact Funct Neurosurg* 69 : 251-258, 1997
20. Onimus M, Allamel G, Manzone P, Laurain JM : Prevention of hip dislocation in cerebral palsy by psoas and adductors tenotomies. *J Pediatr Orthop* 11 : 432-435, 1991
 21. Pritchett JW : The untreated unstable hip in severe cerebral palsy. *Clin Orthop* 173 : 169-172, 1983
 22. Rang M, Douglas G, Bennet GC, Koreska J : Seating for children with cerebral palsy. *J Pediatr Orthop* 1 : 279-287, 1981
 23. Reimers J, Poulsen S : Adductor transfer varus tenotomy for stability of the hip in spastic cerebral palsy. *J Pediatr Orthop* 4 : 52-54, 1984
 24. Root L, Spero CR : Hip adductor transfer compared with adductor tenotomy in cerebral palsy. *J Bone Joint Surg Am* 63 : 767-772, 1981
 25. Samilson RL : Current concepts of surgical management of deformities of the lower extremities in cerebral palsy. *Clin Orthop* 158 : 99-107, 1981
 26. Schultz RS, Chamberlain SE, Stevens PM : Radiographic comparison of adductor procedures in cerebral palsied hips. *J Pediatr Orthop* 4 : 741-744, 1984
 27. Scrutton D, Baird G : Hip dysplasia in cerebral palsy. *Dev Med Child Neurol* 35 : 1028-1030, 1993
 28. Sindou M, Merten P : Selective neurotomy of the tibial nerve for treatment of the spastic foot. *Neurosurgery* 23 : 738-744, 1988
 29. Spruit M, Fabry G : Psoas and adductor release in children. *Acta Orthop Belg* 63 : 91-93, 1997
 30. Vidal J, Deguillaume P, Vidal M : The anatomy of the dysplastic hip in cerebral palsy related to prognosis and treatment. *Int Orthop* 9 : 105-110, 1985
 31. Wassef MR : Interadductor approach to obturator nerve blockade for spastic conditions of adductor thigh muscles. *Reg Anesth* 18 : 13-17, 1993
 32. Wheeler ME, Weinstein SL : Adductor tenotomy-obturator neurectomy. *J Pediatr Orthop* 4 : 48-51, 1984