

## Penetrating Gunshot Injuries to the Brain

Tae-Won Kim, M.D., Jung-Kil Lee, M.D., Kyung-Sub Moon, M.D.,  
Sung-Pil Joo, M.D., Jae-Hyoo Kim, M.D., Soo-Han Kim, M.D.

*Department of Neurosurgery, Chonnam National University Hospital, Medical School, Gwangju, Korea*

**Objective :** Civilian gunshot injuries to the brain are relatively rare and study of these injuries has been neglected in South Korea. We present our experience with penetrating gunshot injuries to the brain and review the outcome of surgical management, as well as other clinical predictors influencing the prognosis.

**Methods :** We present a retrospective analysis of 13 patients with penetrating gunshot injuries to the brain who were treated at our hospital over a period of 22 years.

**Results :** The Glasgow Coma Scale(GCS) score on admission was recorded to be : 3-5 in 1 patient, 6-8 in 3 patients, 9-12 in 2 patients and 13-15 in 7 patients. There were 11 patients who underwent surgical treatment, and the surgical mortality rate was 0%. The admission GCS score was the most valuable prognostic factor. The best results were found to be in patients admitted with an initial GCS higher than 13. There were no favorable outcomes in patients admitted with a GCS of 8 or lower. There was a correlation between the presence of a transventricular or bihemispheric trajectory and poor outcome. The patients admitted with unilobar wounds resulted in better outcome than those with bilobar or multilobar wounds. Retained deep intracranial bone or metal fragments were the most common postoperative complication. However, retained fragments did not increase the risk of infection or seizure.

**Conclusion :** Our results suggest that a less aggressive approach, consisting of minimal local debridement and removal of the bone and metal fragments that are easily accessible, can be successfully used in civilian gunshot wounds to the brain.

**KEY WORDS :** Gunshot wounds · Brain injury · Glasgow coma scale · Outcome.

### Introduction

Penetrating gunshot wounds frequently produce devastating injuries to the brain, and are associated with a high mortality rate, despite appropriate medical and surgical interventions. In general, the mortality rate after surgery is approximately 20%<sup>13)</sup>. The level of consciousness on admission appears to be the most important factor for predicting survival. In addition to the neurological status, many other factors have been considered important for the prognosis including : hemodynamic and respiratory status of the patient on admission, lesions resulting from suicidal attempts, the missile type, the pupil diameter and its reactivity, and computed tomography (CT) findings<sup>11)</sup>. High-velocity injuries also cause secondary damage due to fragmentation of bone, which is shattered by the missile on impact. This secondary damage can be more serious than that cause by the bullet itself<sup>5)</sup>. Civilian gunshot injuries to the head tend to have less damage to the brain and

a favorable outcome<sup>12,13)</sup>. This is because they are usually inflicted by small caliber, low velocity bullets, with a lower destructive power than injuries from high velocity missiles fired from military guns. The purpose of this retrospective study was to review the outcome of surgical management, as well as other clinical predictors, influencing the prognosis of penetrating gunshot injuries to the brain.

### Materials and Methods

We retrospectively reviewed all patients with traumatic brain injuries caused by penetrating injuries that were treated between 1983 and 2005 in our hospital. We identified thirteen patients in whom CT scans documented penetrating gunshot injuries to the brain. We retrospectively analyzed data obtained from these patients' admission charts, follow-up clinical notes, outpatient clinic notes, and brain CT scans. Individuals who were dead on arrival or who had gunshot

• Received : June 5, 2006 • Accepted : September 30, 2006

• Address for reprints : Jung-Kil Lee, M.D., Department of Neurosurgery, Chonnam National University Hospital, Medical School, 8 Hak-dong, Dong-gu, Gwangju 501-757, Korea Tel : +82-62-220-6602, Fax : +82-62-224-9865, E-mail : jklee0261@yahoo.com

**Table 1.** Summary of cases of penetrating gunshot injuries to the brain

No	Age/ Sex	Initial GCS	Pupils	Entry site	Lodging site	Transventricular or bihemispheric injury	Bi or multilobar injury	Comments on injury	Extent of removal	GOS	Complications
1	37/F	12	Normal	Rt.F	Rt.F	Yes	Yes	T-ICH on both F & Lt.T T-SAH, IVH	Partial	3	Retained foreign body
2	39/M	12	Normal	Rt.O	Rt.T,O	No	Yes	T-ICH on Rt.T-O	Partial	5	Retained foreign body
3	30/M	6	Normal	Lt.F	Rt.P	Yes	Yes	ASDH on Rt.F-T-P, T-SAH, falx Hrr	Partial	3	Retained foreign body
4	24/F	14	Normal	Submandibular	Cbll	No	No	Pneumocephalus	-	5	-
5	39/M	4	Dilated unreactive	Rt.T	Lt.P	Yes	Yes	T-ICH on both O, ASDH on Rt.T, T-SAH	-	1	-
6	8/M	15	Normal	Lt.F	Lt.F	No	No	-	Total	5	-
7	37/M	13	Normal	Lt.F	Rt.O	Yes	Yes	T-ICH on Rt.O,T-SAH,IVH	Total	5	Seizure, brain abscess
8	23/M	13	Normal	Submandibular	Cbll	No	No	-	Total	5	-
9	16/M	8	Anisocoria 4+/5-	Lt.F	Lt.O	No	Yes	T-ICH on F, O, T-SAH	Total	3	Seizure, meningitis
10	14/M	15	Normal	Rt.F	Rt.F	No	No	-	Total	5	-
11	9/M	14	Normal	Rt.T	Rt.T	No	No	ASDH on Rt.F-T-P	Total	5	CSF leak
12	17/M	8	Normal	Lt.F	Lt.F	No	No	-	Total	3	-
13	20/M	13	Normal	Rt.t	Lt.T	yes	No	ASDH on Lt.T, T-SAH, T-ICH on Rt.T	Partial	5	CSF leak, skin defect

Rt : right, Lt : left, F : frontal, T : temporal, P : parietal, O : occipital, Cbll : cere bellum, T-ICH : traumatic intracerebral hematoma, T-SAH : traumatic subarachnoid hemorrhage, IVH : intraventricular hemorrhage, ASDH : acute subdural hematoma, Hrr : hemorrhage, GCS : Glasgow Coma Scale, GOS : Glasgow Outcome Scale

wounds of the scalp that did not penetrate the calvaria were excluded from the study.

There were 11 men and 2 women and the age ranged between 8 and 39 years (mean 24.1 years). All patients were assessed for patency of the airway, breathing pattern and circulatory status. According to necessity, patients received the usual protection of the airways, endotracheal tube placement and venous access with infusion of volume to reach hemodynamic stabilization. After these maneuvers, neurological assessment was performed using the Glasgow Coma Scale (GCS) score, papillary size and reaction, as well as other brain stem reflexes and limb movements. Plain radiographs of skull and CT were checked in all patients.

There were 11 patients who were underwent surgery immediately after hospital admission. The surgical treatment included : resection of necrotic tissue, removal of any intracranial bone and metal fragments, evacuation of hematomas and appropriate repair of dura, bone, and soft tissues. All patients received third generation cephalosporins and aminoglycoside for 2 weeks postoperatively. In addition, parenteral anticonvulsant was started. Mannitol was given if features of raised intracranial pressure were seen on imaging studies.

At the time of hospital discharge, patients were classified into 5 groups according to the Glasgow Outcome Scale (GOS) : 1 (death), 2 (persistent vegetative state), 3 (severe disability), 4 (moderate disability) and 5 (good recovery). Patients with

favorable outcomes were defined as those with GOS scores of 5 or 4, whereas an unfavorable outcome was defined as GOS scores of 3,2 or 1. Data were analyzed using the SPSS program for Windows V11.0 (SPSS, Chicago, IL, U.S.A.). Between-group comparisons were conducted using the chi-square test. For all analyses, a *p*-value of <0.05 was considered statistically significant.

## Results

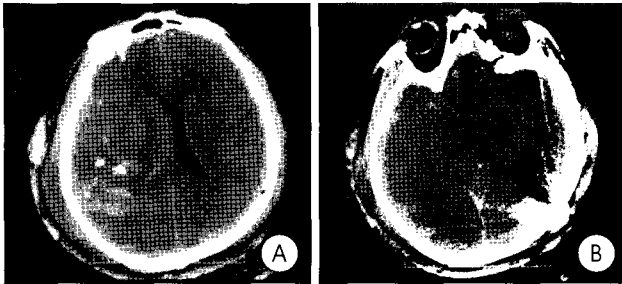
Thirteen cases with the diagnosis of gunshot wound to the brain were identified (Table 1). The series included 11 men (84.6%) and 2 women (15.4%) with a mean age of 24.1 years (range, 8~39 years). The mean GCS score on admission was 11.3 (range 4~15). There were 7 patients (53.8%) who were admitted to our institution with a GCS score of 13~15 : 2 patients (15.4%) had a GCS score of 9~12, 3 (23.1%)

**Table 2.** The mortality and GOS according to GCS on admission

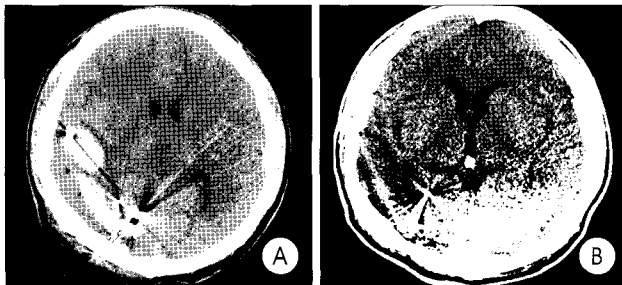
GCS	No of patients (%)					Total
	GOS 5	GOS 4	GOS 3	GOS 2	GOS 1	
GCS 13~15	7 (100.0)	0	0	0	0	7 (53.8)
GCS 9~12	1 (50.0)	0	1 (50.0)	0	0	2 (15.4)
GCS 5~8	0	0	3 (100.0)	0	0	3 (23.1)
GCS 3~5	0	0	0	0	1 (100.0)	1 (7.7)
Total	8 (61.5)	0	4 (31.8)	0	1 (7.7)	13

GCS : Glasgow coma scale, GOS : Glasgow outcome scale

*P*<0.05



**Fig. 1.** Case 5. A, B : Computed tomography scan showing severe brain swelling, acute subdural hematoma and retained fragments at the right temporal lobe, and intracerebral hematoma at the left occipital lobe. The bullet trajectory was characterized as bihemispheric and multilobar injuries.



**Fig. 2.** Case 2. A : Preoperative computed tomography(CT) scan showing intracerebral hematoma at the right tempo-occipital lobe. B : CT scan 5 months after surgery demonstrating retained fragments at the right occipital lobe.

**Table 3.** Bullet entry site and lodging site

Site	Entry site (Cases)	Lodging site (Cases)
Frontal	7	5
Temporal	3	5
Parietal	0	1
Occipital	1	4
Cerebellum	0	2
Submandibular	2	0

had GCS scores of 6~8 and 1 (7.7%) had GCS scores less than 5. GOS results showed that 1 patient died, 4 patients were severely disabled and 8 patients had a good recovery at the time of discharge. The overall mortality rate was 7.7% (1 of 13 patients). A patient admitted with a GCS of 4, and multilobar missile trajectory, died three days later because of severe brain swelling due to extensive brain tissue injury (Fig. 1). The GOS according to the admission GCS score is summarized in Table 2. Of the 9 patients with a GCS score of more than 8, all but one patient (Case 1) (Fig. 2, 3) survived with favorable outcomes (8 had a good recovery and 1 had severe disability); of the 4 patients with a GCS score of less than 8, all had unfavorable outcomes (1 died, and 3 had severe disability);  $p < 0.05$  between the 2 GCS groups (Fig. 4).

Brain CT scan was helpful in assessing the extent of brain damage and location of bone fragments and missiles. The entry site of cranial penetration and the site of material involved

**Table 4.** Details of CT scan findings and GOS

Injuries	No. of patients (%)					Total	P value
	GOS 5	GOS 4	GOS 3	GOS 2	GOS 1		
Transventricular or bihemispheric injury	2 (40.0)	0 (0.0)	2 (40.0)	0 (0.0)	1 (20.0)	5	0.225
Not transventricular or bihemispheric injury	6 (75.0)	0 (0.0)	2 (25.5)	0 (0.0)	0 (0.0)	8	
Bi- or multilobar injury	2 (33.3)	0 (0.0)	3 (50.0)	0 (0.0)	1 (16.7)	6	0.068
unilobar injury	6 (85.7)	0 (0.0)	1 (14.3)	0 (0.0)	0 (0.0)	7	

GOS : Glasgow outcome scale

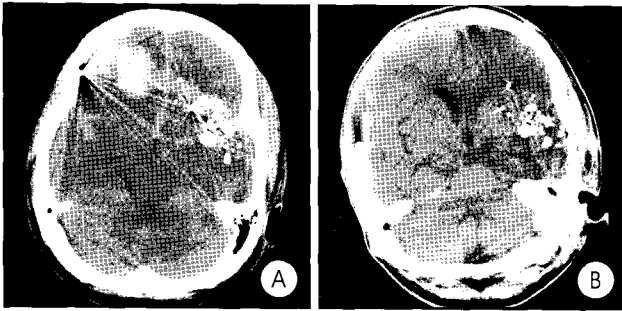
**Table 5.** Postoperative complications

Complications	No. of cases (%)
Retained intracranial bone or metal fragments	4 (36.4)
CSF leak	2 (18.2)
Seizure	2 (18.2)
Cerebral abscess	1 (9.1)
Meningitis	1 (9.1)

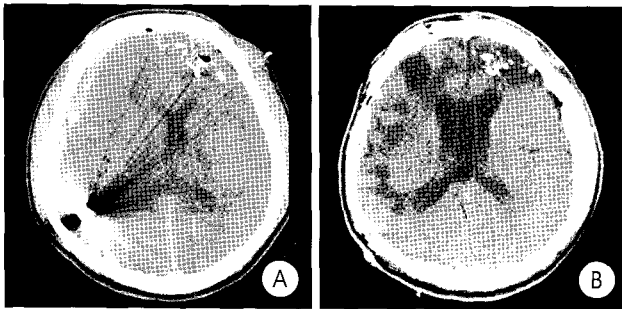
were identified, as shown in Table 3. In our study, the most frequently injured brain area was the frontal lobe.

Details of CT scan findings are given in Table 4. The patients admitted with transventricular or bihemispheric injuries had an unfavorable outcome when compared to those without these types of injuries. In 8 cases in which the bullet trajectory was not characterized as transventricular or bihemispheric, 6 patients had a favorable outcome (75.0%). Among 5 patients with transventricular or bihemispheric injuries, 3 patients had an unfavorable outcome (60.0%). In addition, the rate of satisfactory outcome was higher in 7 patients with unilobar injury than in 6 patients with bi- or multilobar injury, although the correlation was not statistically significant (85.7% vs. 33.3%;  $p < 0.068$ ). In the group of bi- or multilobar injuries (6 cases), 4 patients presented with an unfavorable outcome (66.7%). The incidence of unfavorable outcome decreased to 14.3% (1 case) in the group with unilobar injuries (7 cases).

Most patients (11) except for 2 (Case 4, 5), were taken to surgery for evacuation of hematomas, removal of any intracranial bone or metal fragments, necrotic tissue, as well as wound debridement and reconstruction. The postoperative complications are shown in Table 5. The most frequent postoperative complication was retained deep intracranial bone or metal fragments; this occurred in 4 patients (36.4%). None of these 4 patients developed intracranial infection. However, intracranial infection, such as cerebral abscess or meningitis, was unexpectedly noted in 2 patients in whom total removal of intracranial bone or metal fragments was achieved. Seizures occurred in 2 patients who had the complications of brain abscess and meningitis. Anticonvulsants were used routinely in all patients and continued for an additional 6 months or longer if seizures were reported. In 2 patients with seizures,



**Fig. 3.** Case 1. A : Preoperative computed tomography(CT) scan showing intracerebral hematoma at both frontal lobes and hemorrhagic contusion at the left temporal lobe and subarachnoid hemorrhage with a bihemispheric bullet injury. B : CT scan 1 month after surgery demonstrating retained bone fragments at the left temporal lobe.



**Fig. 4.** Case 3. (A) Preoperative computed tomography(CT) scan showing right fronto-parietal acute subdural hematoma and retained bone fragments at the left frontal lobe and (B) CT scan 1 year after surgery.

anticonvulsants were maintained for 2 years. There was no correlation between presence of retained fragments and subsequent development of intracranial infection or epilepsy. A cerebrospinal fluid(CSF) leak was noted in 2 cases during the postoperative period. They were successfully treated with controlled lumbar drainage of CSF, and there was no development of infection.

## Discussion

Gunshot wounds to the head have a high morbidity and mortality. The mortality rates in the literature range from 23 to 92% and are considerably higher (87~100%) in patients admitted in a poor neurologic state<sup>11</sup>. Rosenfeld<sup>15</sup> reported only an 8.1% survival among civilian victims presenting with GCS 3~5; however, higher GCS is associated with a significantly improved survival : GCS 6~8, 35.6% and GCS 9~15, 90.5%. The GCS score on admission was the main determinant of outcome in our series. Other important prognostic factors were hemodynamic and respiratory status at admission, the pupil diameter and its reactivity, and the presence of coagulation abnormalities<sup>11,12</sup>. Many other radiological factors including bilateral hemispheric injury, multi-lobe injury, transventricular trajectory, brain stem injury, in-

tracerebral hematoma/cerebral contusion with an associated mass effect, and missile and bony fragmentation away from the bullet's path, usually indicate an unfavorable outcome and high mortality<sup>7,12</sup>. In accordance with other authors, the presence of bilobar or multilobar, central bihemispheric, and transventricular lesions were related with an unfavorable outcome. In the group of transventricular or bihemispheric injuries and bi- or multilobar injuries, 60.0% and 66.7% of patients had an unfavorable outcome in our study.

There is controversy concerning aggressive surgical management for patients with a GCS of 3~5. Clark et al.<sup>5</sup> reported that there were no survivors among patients treated conservatively with a GCS scores of 3 as well as among patients who underwent surgery with a preoperative score of 4~5. Grahm et al.<sup>8</sup> recommended patients with a post-resuscitation GCS of 3~5 should not be treated with surgery unless there is an operable hematoma. Levy et al.<sup>10</sup> evaluated 190 patients with craniocerebral gunshot injuries who had a GCS 3~5 and concluded that patients with a GCS 3~5 on admission may have a better survival with surgery but outcomes are generally poor. There may be a small subgroup of patients with GCS 3~5 who have reactive pupils, no fragmentation, no bihemispheric injury with ventricular involvement and no subarachnoid hemorrhage who would have a reasonable chance of a good outcome with aggressive management and surgery. However, Stone et al.<sup>16</sup> recommended that if the pupils are reactive and the patient is hemodynamically stable, surgery should proceed, even if the GCS is 3. A patient with clinical or radiological evidence of a mass effect from a hematoma on CT should have immediate surgery. In our study, although a small number of cases were investigated, the only patient who died had a GCS score of 4.

The degree of debridement required is also controversial. Aggressive intracranial debridement with an effort to remove all bone and any metallic fragments which are reasonably accessible has been recommended for craniocerebral gunshot wounds<sup>13</sup>. Stone et al.<sup>13</sup> recommended aggressive debridement of devitalized tissue to reduce edema and irrigation of the track to wash out fragments and debris. On the other hand, others have recommended a less aggressive surgical approach, consisting of minimal local debridement and removal of the bone and metal fragments easily accessible<sup>3,6,17</sup>. With the availability of the CT scan, a less aggressive surgical approach have been used successfully in civilian gunshot wounds to the brain. The intracranial bone and metallic fragments that are not removed may to be associated with infection<sup>3,6,13</sup>. Aarabi<sup>11</sup> reported that retained bone fragments led to a greater number of infections, but the correlation was not statistically significant. Experimental studies by Pitlyk et al.<sup>14</sup> revealed that bone fragments did not increase the infection rate itself, but that when scalp

or hair accompanied these pieces the rate was 10-fold higher. The bone fragments have a much greater chance of causing late infection than metallic fragments (probably because of indrawn scalp, hair and dirt). In addition, scalp wound dehiscence greatly increases the chance of intracranial infection<sup>17)</sup>. In our study, there was no case of postoperative infection in 4 patients with deep retained intracranial bone or metal fragments. Therefore, prospective studies analyzing limited versus radical debridement are necessary to assess the impact of these therapies on the prevention of infection and seizure development.

CSF fistulas are associated with a higher infection rate, although its risk is very low with complete dural closure. Aarabi reported a 20-fold higher infection rate in cases with CSF fistulas compared to those without this injury<sup>1,2,6)</sup>. Contamination with micro-organisms through on-going CSF fistulas is unavoidable, even with the early initiation of antibiotics therapy. In our series, we encountered two cases of CSF fistula that were successfully treated with controlled lumbar drainage and were not complicated with intracranial infection.

Post-traumatic epilepsy is another complication, which reflects the extent of brain damage and is positively correlated with the level of coma<sup>4)</sup>. From combined series, the risk of epilepsy ranges from 1.3% to 24%<sup>4)</sup>. In our series, epilepsy developed in two patients without any intracranial fragments. Although the retained bone and metallic fragments in the brain are thought to be responsible for epileptic seizures, our experience indicates that those fragments themselves are not necessary for the development of epileptic seizures.

Vascular injury such as venous sinus injury, traumatic aneurysm, arterial dissection, arterial occlusion, and arteriovenous fistula may occur in patients with a gunshot wound to the brain. The incidence of traumatic aneurysm is 2~8%<sup>4)</sup>. Undetected traumatic aneurysms are likely to bleed, resulting in high mortality. Therefore, angiography should be performed within a few days when the missile track passes through the sylvian fissure or other vascular areas, and is indicated if delayed intracerebral hemorrhage occurs.

CT scanning provides a quick, noninvasive method of assessing the intracranial contents, and the routine use of CT has had a significant effect on the management of these wounds. The CT scan has several features that aid in the diagnosis and evaluation of penetrating gunshot injuries, and can identify the lesion extension, presence of hematoma and other associated lesions, determine the missile track, provide useful information for the planning of the surgical procedure, and usually helps define patient prognosis<sup>9,11)</sup>. Coronal sections may be helpful for gunshot injury in the skull base or high convexity. Magnetic resonance imaging may not provide adequate imaging of bone, and it is also contraindicated in cases with intracranial metallic foreign bodies because of the

potential risk for migration and further injury. Therefore, its use in the gunshot injuries is limited.

Our approach to a gunshot wound to the brain consists of the following protocol: If the vital signs are unstable on admission, early aggressive resuscitation is needed. The vital functions must be closely monitored in the intensive care unit. If the state of consciousness deteriorates, CT scans, ICP monitoring and mechanical ventilation should be applied as needed. Broad-spectrum antibiotics, anticonvulsant and tetanus prophylaxis are also administered. Patients with a post-resuscitation GCS higher than 5, should receive urgent surgery as soon as possible. Careful exploration of the wound, removal of any intracranial hematomas causing a mass effect, debridement of necrotic brain tissue, removal of bullet or bone fragments only when they are accessible and do not require an approach through uninjured cerebral tissues. Deep bone and metal fragments or those in intraventricular locations are left in place, because they are not associated with higher rates of infection and their removal does not reduce the incidence of seizure. Complete closure of the dura either primarily or using a graft is performed, followed by postoperative control of intracranial pressure. When CSF leakage occurs after dural repair, lumbar drainage is carried out to prevent CSF fistula formation and intracranial infection. In cases where retained bone and metal fragments do not produce signs of infection, the patient should be periodically followed-up with CT scans. When there is evidence of infection on the follow-up CT, immediate surgery must be performed. In addition, cerebral angiography is mandatory in missile injuries where the potential for major vascular injury exists. If an intracerebral hematoma is detected on CT scan, angiography should be done at once because hematoma may harbor and simultaneously obscure an aneurysm.

## Conclusion

This small group of thirteen patients demonstrates that a GCS of 8 or less, the presence of bilobar or multilobar, bihemispheric, and transventricular lesions were related significantly with a poor outcome in patients with penetrating craniocerebral gunshot injuries.

There was no correlation between the presence of retained bone or metallic fragments and subsequent development of intracranial infection or epilepsy. Our results suggest that a less aggressive approach, consisting of minimal local debridement and removal of the bone and metal fragments easily accessible, can be successfully used in civilian gunshot wounds to the brain. Early surgical management with vigorous control of intracranial pressure offers the best chance of achieving a satisfactory outcome.

## References

1. Aarabi B : Causes of infections in penetrating head wounds in the iran-iraq war. *Neurosurgery* 25 : 923-926, 1989
2. Aarabi B : Comparative study of bacteriological contamination between primary and secondary exploration of missile head wounds. *Neurosurgery* 20 : 610-616, 1987
3. Brandvold B, Levi L, Feinsod M, George ED : Penetrating craniocerebral injuries in the israeli involvement in the lebanese conflict, 1982-1985. Analysis of a less aggressive surgical approach. *J Neurosurg* 72 : 15-21, 1990
4. Caveness WF, Meierowsky AM, Rish BL, Mohr JP, Kistler JP, Dillon JD, et al : The nature of posttraumatic epilepsy. *J Neurosurg* 50 : 545-553, 1979
5. Clark WC, Muhlbauer MS, Warridge CB, Ray MW : Analysis of 76 civilian craniocerebral gunshot wounds. *J Neurosurg* 65 : 9-14, 1986
6. Cosar A, Gonul E, Kurt E, Gonul M, Tasar M, Yetiser S : Craniocerebral gunshot wounds : Results of less aggressive surgery and complications. *Minim Invasive Neurosurg* 48 : 113-118, 2005
7. Gonul E, Erdogan E, Tasar M, Yetiser S, Akay KM, Duz B, et al : Penetrating orbitocranial gunshot injuries. *Surg Neurol* 63 : 24-31, 2005
8. Graham TW, Williams FC Jr, Harrington T, Spetzler RF : Civilian gunshot wounds to the head : a prospective study. *Neurosurgery* 27 : 696-700, 1990
9. Kim SM, Shin YS, Lee KS : Surgical Cases of Penetrating Brain Injury by Foreign Body. *J Korean Neurosurg Soc* 26 : 1025-1030, 1997
10. Levy ML, Masri LS, Lavine S, Apuzzo ML : Outcome prediction after penetrating craniocerebral injury in a civilian population : aggressive surgical management in patients with admission glasgow coma scale scores of 3, 4, or 5. *Neurosurgery* 35 : 77-85, 1994
11. Martins RS, Siqueira MG, Santos MT, Zanon-Collange N, Moraes OJ : Prognostic factors and treatment of penetrating gunshot wounds to the head. *Surg Neurol* 60 : 98-104, 2003
12. Nathoo N, Chite SH, Edwards PJ, Van Dellen JR : Civilian infratentorial gunshot injuries : outcome analysis of 26 patients. *Surg Neurol* 58 : 225-233, 2002
13. Ozkan U, Kemaloglu S, Ozates M, Aydin D : Analysis of 107 civilian craniocerebral gunshot wounds. *Neurosurg Rev* 25 : 231-236, 2002
14. Pitlyk PJ, Tolchin S, Stewart W : The experimental significance of retained intracranial bone fragments. *J Neurosurg* 33 : 19-24, 1970
15. Rosenfeld JV : Gunshot injury to the head and spine. *J Clin Neurosci* 9 : 9-16, 2002
16. Stone JL, Lichtor T, Fitzgerald LF : Gunshot wounds to the head in civilian practice. *Neurosurgery* 37 : 1104-1112, 1995
17. Taha JM, Haddad FS, Brown JA : Intracranial infection after missile injuries to the brain : report of 30 cases from the lebanese conflict. *Neurosurgery* 29 : 864-868, 1991