

## Loss of infectivity of *Neospora caninum* oocysts maintained for a prolonged time

Rosangela Soares UZEDA<sup>1</sup>, Kattyane De Souza COSTA<sup>1</sup>, Sara Lima SANTOS<sup>1</sup>,  
Alexandre Moraes PINHEIRO<sup>1</sup>, Maria Angela Ornelas De ALMEIDA<sup>1</sup>,  
Milton M. McALLISTER<sup>2</sup> and Luis Fernando Pita GONDIM<sup>1</sup>\*

<sup>1</sup>Universidade Federal da Bahia, Escola de Medicina Veterinária, Departamento de Patologia e Clínicas,  
Avenida Ademar de Barros, 500, Ondina, Salvador, Bahia, 40170-110, Brazil

<sup>2</sup>University of Illinois, Department of Veterinary Pathobiology, 2001 South Lincoln Avenue, Urbana, Illinois 61802, USA

**Abstract:** The purpose of this study was to investigate whether sporulated *Neospora caninum* oocysts, which had been stored for 46 mo in a 2% sulfuric acid solution at 4°C, remain morphologically viable and infective to gerbils (*Meriones unguiculatus*). Six gerbils were orally inoculated with doses of 400 or 1,200 oocysts. Two mo after inoculation, the animals did not show any clinical signs, had no histological lesions, and were seronegative for *N. caninum* at 1: 50 in an immunofluorescent antibody test. PCR using the brain from each gerbil did not reveal *N. caninum* specific DNA. We conclude that oocysts preserved for 46 mo are not infective, despite being morphologically intact.

**Key words:** *Neospora caninum*, oocysts, Mongolian gerbils, *Meriones unguiculatus*, infectivity

*Neospora caninum* is a protozoan parasite that infects a wide range of domestic (Dubey and Lindsay, 1996) and wild animals (Gondim, 2006). Neosporosis is the most important cause of abortion in cattle in many geographic regions (Anderson et al., 2000) and is responsible for neuropathy in dogs (Barber and Trees, 1996). Intermediate hosts of *N. caninum* can be infected transplacentally from dam to fetus (Dubey, 2003), or horizontally by ingestion of oocysts shed by a definitive host, such as dogs or coyotes (McAllister et al., 1998; Gondim et al., 2004c).

Mongolian gerbils (*Meriones unguiculatus*) have been shown to be susceptible to *N. caninum* infection.

The parasite was successfully isolated from dogs through peritoneal inoculation of *N. caninum*-infected dog tissues in gerbils; isolation failed when the same tissues were inoculated into mice, guinea pigs, hamsters, and rabbits (Cuddon et al., 1992). Several passages of *N. caninum* tachyzoites were achieved through peritoneal inoculations of the parasite in gerbils (Gondim et al., 1999). Gerbils were also demonstrated to be susceptible to oral inoculation with *N. caninum* oocysts (Dubey and Lindsay, 2000; Basso et al., 2001; Gondim et al., 2001); this rodent species can be infected by a single oocyst (Trees et al., 2002). The purpose of this study was to investigate if *N. caninum* oocysts remain infective to gerbils after prolonged storage at 4°C in an acidified solution.

*Neospora caninum* oocysts (NC-beef strain) were produced in a previous experiment (Gondim et al., 2002), and feces containing oocysts were homogenized and

• Received 2 May, accepted after revision 17 August 2007.

• This work was supported by FAPESB (Fundação de Amparo à Pesquisa do Estado da Bahia) and JICA (Japan International Cooperation Agency).

\*Corresponding author (e-mail: pita@ufba.br)

suspended in 2% sulfuric acid at 4°C, without purification of oocysts. In July 2004, a total of 30,000 sporulated *N. caninum* oocysts were purified by flotation in Sheather's solution, counted, divided in 4 plastic tubes (2 ml-size) in 2% sulfuric acid solution, and stored at 4°C. In June 2005, oocysts were washed 4 times with sterile phosphate buffer solution (PBS) to remove the sulfuric acid, and recounted. Oocysts (46-mo-old) were resuspended in sterile PBS and distributed in 6 tubes of 1 ml each. Three tubes contained 400 oocysts each, and the other 3 tubes contained 1,200 oocysts each.

Fourteen female Mongolian gerbils, 8-12 weeks old, were purchased from Universidade Federal da Bahia. Six gerbils were orally inoculated with *N. caninum* oocysts using an esophageal cannula. An additional 6 uninoculated gerbils served as negative controls. All animals were anesthetized in a plastic chamber with isoflurine before oral inoculation. In the test group, 3 animals were administered 400 oocysts each, and 3 gerbils received 1,200 oocysts each. The negative control gerbils were orally administered 1 ml of PBS each. After oral inoculation, animals were observed daily for clinical signs. Two mo after inoculations all animals were killed. Samples of blood and brain were collected from each gerbil. Three-fourths of the brain was used for DNA extraction and one fourth was fixed in 10% neutral buffered formalin.

A group of 3 gerbils and 3 pregnant cows that had been previously inoculated with oocysts (stored in 2% sulfuric acid at 4°C up to 108 days) (Gondim et al., 2002; 2004a) produced by the same dogs, that originated the oocysts for the current experiment, were considered as positive controls. The 3 gerbils were orally inoculated with 30 oocysts each, and infection was confirmed in the 3 animals by serology and PCR (Gondim et al., 2002). The 3 pregnant cows received 1,500 oocysts each, and 2 of 3 cows became infected (Gondim et al., 2004a).

Two gerbils were subcutaneously inoculated with 7,500 *N. caninum* tachyzoites in 0.5 ml of PBS each in order to produce positive control tissues for PCR and positive sera for serology. One gerbil was killed 9 days after infection, and the other animal was killed

30 days after infection.

Pre- and post-inoculation sera were tested for *N. caninum* antibody using an indirect fluorescent antibody test (IFAT), as described by Dubey et al. (1988) with minor modifications. A 1: 50 cut-off dilution was employed and a commercial fluorescein isothiocyanate labeled anti-mouse IgG was used as secondary antibody (Sigma, St. Louis, Missouri, USA). IFAT reactions were only considered positive if the whole tachyzoite surface was fluorescent.

Pre- and post-infection sera were obtained from 2 gerbils, which had been subcutaneously infected with *N. caninum* tachyzoites, and used as negative and positive controls. Serology and PCR (described below) evaluations were performed in positive controls to demonstrate that all techniques functioned properly.

Three-fourth of the total brain was homogenized with a pestle and mortar in liquid nitrogen. DNA extraction was performed using an Easy-DNA™ kit (Invitrogen, São Paulo, Brazil). DNA from *N. caninum* and *Toxoplasma gondii* tachyzoites of NC-Bahia and RH strains were used as positive controls and ultrapure water as a negative control. A 100 bp DNA ladder (Invitrogen) was used as a marker.

PCR reactions were performed in 25  $\mu$ l volumes containing the NP6/NP21 primer pair (Yamage et al., 1996), a PCR Master Mix (Promega, Madison, Wisconsin, USA), and the template. Reaction conditions were 1 cycle at 94°C for 2 min; 40 cycles of 94°C for 30 sec, 53°C for 30 sec, 72°C for 30 sec; and a final 72°C for 5 min. A reamplification of the PCR products was done using the same conditions. PCR for *T. gondii* was performed similarly, except by using the primer pair TgB1-1 and TgB1-4 (Burg et al., 1989) and an annealing temperature of 55°C. PCR products were analyzed by electrophoresis on a 2% agarose gel stained with ethidium bromide and visualized under ultraviolet light.

One-fourth of each gerbil brain that was fixed in 10% neutral buffered formalin was processed for histological examination and stained with hematoxylin and eosin (H-E). Nine stained sections from each gerbil were analyzed for lesions or parasite stages.

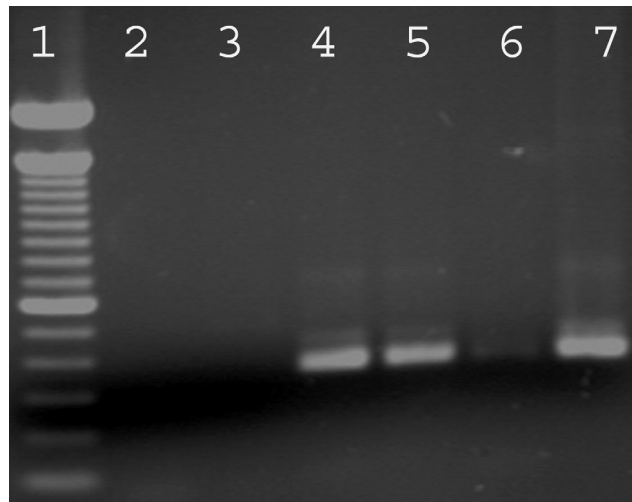
Sporulated *N. caninum* oocysts which had been stor-

age for 46 mo were orally inoculated to 6 gerbils. The animals did not show any clinical signs, had no histological brain lesions, and did not have specific antibodies at a 1: 50 cutoff by IFAT. PCR using brain from each gerbil did not reveal *N. caninum* specific DNA. In contrast, results of IFAT (titers of 1: 400 and 1: 6,400) and PCR (Fig. 1) were positive in the gerbils that had been inoculated with *N. caninum* tachyzoites, demonstrating that the procedures were sensitive enough to detect infection of gerbils. The 6 gerbils used as negative controls did not present any clinical signs or lesions and were negative for *N. caninum* infection by IFAT and PCR.

Gerbils were inoculated with 400 or 1,200 morphologically intact oocysts each. Oocysts in storage were counted in 2 occasions, immediately before inoculation and 1 year earlier. The number of sporulated *N. caninum* oocysts observed dropped from 30,000 to 4,800 during this interval.

Horizontal transmission of *N. caninum* by ingestion of parasite oocysts is associated with abortion outbreaks in cattle (McAllister et al., 1996, 2000; Jenkins et al., 2000), and has been demonstrated to be necessary to sustain *N. caninum* infection in bovine herds (McAllister, 1999). After dogs were identified as definitive hosts of *N. caninum* (McAllister et al., 1998), several studies involving experimental infection with oocysts have been done (De Marez et al., 1999; Dubey and Lindsay, 2000; O'Handley et al., 2002; Trees et al., 2002; Gondim et al., 2004a, 2004b; Rodrigues et al., 2004), however, the biology of *N. caninum* oocysts remains poorly understood. Before the a present experiment, there was no information regarding infectivity of *N. caninum* oocysts maintained for a prolonged time. Similar protozoal oocysts, such as those of *T. gondii*, are infective for several years in 2% sulfuric acid at 4°C (reviewed by Dumetre and Darde, 2003).

In the present study, *N. caninum* oocysts, which had been stored for 46 mo in 2% sulfuric acid solution at 4°C, were orally inoculated in gerbils. The oocysts were first counted when they were 2 years old, and then recounted when they were nearly 4 years old; during this interval, the number of oocysts dropped



**Fig. 1.** PCR for *Neospora caninum* using Np21-Np6 primers (Yamage et al., 1996). Lanes (1) A 100 bp DNA ladder; (2) Negative control; (3) Empty lane; (4-5) Brains from 2 gerbils infected with *N. caninum* tachyzoites; (6) Empty lane; (7) *N. caninum* DNA (positive control).

from 30,000 to 4,800. It is possible that a portion of this reduction in oocyst numbers may have been a consequence of successive centrifugations to rinse away sulfuric acid. The oocysts appeared morphologically normal immediately before inoculation; however, they were not infective to gerbils.

The oocysts used in the current experiment were the remaining part of the oocysts used in other 2 studies (Gondim et al., 2002, 2004a). The oocysts, when used after a few weeks of storage at 4°C in 2% sulfuric acid, were infective to gerbils that received 30 sporulated oocysts each (Gondim et al., 2002). Part of the oocysts stored up to 108 days at the same conditions, were infective to cows, which were orally administered 1,500 oocysts each (Gondim et al., 2004a).

In another experiment, Trees et al. (2002) used doses of 1, 10, and 100 *N. caninum* oocysts to infect 6 gerbils; all animals seroconverted and *N. caninum* DNA was detected in 5 of 5 tested gerbils. Because gerbils have been previously demonstrated to be highly susceptible to infection with *N. caninum* oocysts, yet in the present study gerbils did not become infected with oocysts preserved for 46 mo at 4°C in dilute sulfuric acid. We conclude that *N. caninum* oocysts do not survive 46 mo in these conditions,

however, further studies are necessary to accurately determine the exact time point when the oocysts lose their infectivity.

## ACKNOWLEDGMENTS

The authors wish to thank Dr. Paulo Maiorka for helping with histopathological analyses and Fundação de Amparo à Pesquisa do Estado da Bahia (FAPESB) for the scholarship master degree to R.S. Uzeda.

## REFERENCES

- Anderson ML, Andrianarivo AG, Conrad PA (2000) Neosporosis in cattle. *Anim Reprod Sci* **60-61**: 417-431.
- Barber, JS, Trees AJ (1996) Clinical aspects of 27 cases of neosporosis in dogs. *Vet Rec* **139**: 439-443.
- Basso W, Venturini L, Venturini MC, Hill DE, Kwok OC, Shen SK, Dubey, JP (2001) First isolation of *Neospora caninum* from the feces of a naturally infected dog. *J Parasitol* **87**: 612-618.
- Burg JL, Grover CM, Pouletty P, Boothroyd JC (1989) Direct and sensitive detection of a pathogenic protozoan, *Toxoplasma gondii*, by polymerase chain reaction. *J Clin Microbiol* **27**: 1787-1792.
- Cuddon P, Lin DS, Bowman DD, Lindsay DS, Miller TK, Duncan ID, deLahunta A, Cummings J, Suter M, Cooper B, et al. (1992) *Neospora caninum* infection in English Springer Spaniel littermates. Diagnostic evaluation and organism isolation. *J Vet Intern Med* **6**: 325-332.
- De Marez T, Liddell S, Dubey JP, Jenkins MC, Gasbarre L (1999) Oral infection of calves with *Neospora caninum* oocysts from dogs: humoral and cellular immune responses. *Int J Parasitol* **29**: 1647-1657.
- Dubey JP (2003) Review of *Neospora caninum* and neosporosis in animals. *Korean J Parasitol* **41**: 1-16.
- Dubey JP, Hattel AL, Lindsay DS, Topper MJ (1988) Neonatal *Neospora caninum* infection in dogs: isolation of the causative agent and experimental transmission. *J Am Vet Med Assoc* **193**: 1259-1263.
- Dubey JP, Lindsay DS (1996) A review of *Neospora caninum* and neosporosis. *Vet Parasitol* **67**: 1-59.
- Dubey JP, Lindsay DS (2000) Gerbils (*Meriones unguiculatus*) are highly susceptible to oral infection with *Neospora caninum* oocysts. *Parasitol Res* **86**: 165-168.
- Dumetre A, Darde ML (2003) How to detect *Toxoplasma gondii* oocysts in environmental samples? *FEMS Microbiol Rev* **27**: 651-661.
- Gondim LF, Pinheiro AM, Santos PO, Jesus EE, Ribeiro MB, Fernandes HS, Almeida MA, Freire SM, Meyer R, McAllister MM (2001) Isolation of *Neospora caninum* from the brain of a naturally infected dog, and production of encysted bradyzoites in gerbils. *Vet Parasitol* **101**: 1-7.
- Gondim LFP (2006) *Neospora caninum* in wildlife. *Trends Parasitol* **22**: 247-252.
- Gondim LFP, Gao L, McAllister MM (2002) Improved production of *Neospora caninum* oocysts, cyclical oral transmission between dogs and cattle, and in vitro isolation from oocysts. *J Parasitol* **88**: 1159-1163.
- Gondim LFP, McAllister MM, Anderson-Sprecher RC, Bjorkman C, Lock TF, Firkins LD, Gao L, Fischer WR (2004a) Transplacental transmission and abortion in cows administered *Neospora caninum* oocysts. *J Parasitol* **90**: 1394-1400.
- Gondim LFP, McAllister MM, Mateus-Pinilla NE, Pitt WC, Mech LD, Nelson ME (2004b) Transmission of *Neospora caninum* between wild and domestic animals. *J Parasitol* **90**: 1361-1365.
- Gondim LFP, McAllister MM, Pitt WC, Zemlicka DE (2004c) Coyotes (*Canis latrans*) are definitive hosts of *Neospora caninum*. *Int J Parasitol* **34**: 159-161.
- Gondim LFP, Saeki H, Onaga H, Haritani M, Yamane I (1999) Maintenance of *Neospora caninum* tachyzoites using Mongolian gerbils (*Meriones unguiculatus*). *New Zeal Vet J* **47**: 36.
- Jenkins MC, Caver JA, Bjorkman C, Anderson TC, Romand S, Vinyard B, Uggla A, Thulliez P, Dubey JP (2000) Serological investigation of an outbreak of *Neospora caninum*-associated abortion in a dairy herd in southeastern United States. *Vet Parasitol* **94**: 17-26.
- McAllister MM (1999) Uncovering the biology and epidemiology of *Neospora caninum*. *Parasitol Today* **15**: 216-217.
- McAllister MM, Bjorkman C, Anderson-Sprecher R, Rogers DG (2000) Evidence of point-source exposure to *Neospora caninum* and protective immunity in a herd of beef cows. *J Am Vet Med Assoc* **217**: 881-887.
- McAllister MM, Dubey JP, Lindsay DS, Jolley WR, Wills RA, McGuire AM (1998) Dogs are definitive hosts of *Neospora caninum*. *Int J Parasitol* **28**: 1473-1478.
- McAllister MM, Huffman EM, Hietala SK, Conrad PA, Anderson ML, Salman MD (1996) Evidence suggesting a point source exposure in an outbreak of bovine abortion due to neosporosis. *J Vet Diagn Invest* **8**: 355-357.
- O'Handley R, Liddell S, Parker C, Jenkins MC, Dubey JP (2002) Experimental infection of sheep with *Neospora caninum* oocysts. *J Parasitol* **88**: 1120-1123.

Rodrigues AA, Gennari SM, Aguiar DM, Sreekumar C, Hill DE, Miska KB, Vianna MC, Dubey JP (2004) Shedding of *Neospora caninum* oocysts by dogs fed tissues from naturally infected water buffaloes (*Bubalus bubalis*) from Brazil. *Vet Parasitol* **124**: 139-150.

Trees A, McAllister M, Guy C, McGarry J, Smith R, Williams D (2002) *Neospora caninum*: oocyst challenge of pregnant

cows. *Vet Parasitol* **109**: 147-154.

Yamaga M, Flechtner O, Gottstein B (1996) *Neospora caninum*: specific oligonucleotide primers for the detection of brain "cyst" DNA of experimentally infected nude mice by the polymerase chain reaction (PCR). *J Parasitol* **82**: 272-279.