

## Intestinal and Mesenteric Lymphosarcoma on Alcohol Liver Disease in the Mice

Dong-Wei Yuan, Hai-Jie Yang, Il-Hwa Hong, Mi-Ran Ki, Jin-Kyu Park, Moon-Jung Goo,  
Hye-Rim Lee, Seung-Eun Yoo<sup>1</sup> and Kyu-S hik Jeong\*

Department of Veterinary Pathology, Collage of Veterinary Medicine, Kyungpook National University, Daegu 702-701, Republic of Korea

<sup>1</sup>Korea Research Institute of Chemical Technology, Daejeon, Republic of Korea

Received October 10, 2007 / Accepted November 12, 2007

In the study of investigate the expression and effects of adrenomedullin (AM) in the tissue injured by ethanol in our laboratory, there were lymphosarcomas involving mesenteric lymph node and intestine discovered in experimental mice. Lymphosarcoma is probably the second most common spontaneous neoplastic disease, the incidence of which is dependent on the strain of mouse. The diagnosis of lymphosarcoma was based on gross and light microscopic studies. Grossly, the excised intestine and mesentery showed soft-to-firm, cream-colored, displayed protuberance into the lumen. The neoplastic cells had mainly infiltrated into the mucosal and mesenteric lymph node, and have round hyperchromatic nuclei and a small amount of cytoplasm. The origin of these tumor cells was determined by immunohistochemistry positive of CD20, CD3 and Vimentin.

**Key words** : Intestine, mesentery, mice, lymphosarcoma

### Introduction

Lymphosarcoma is probably the second most common spontaneous neoplastic disease, the incidence of which is dependent on the strain of mouse [5]. Lymphosarcoma is a neoplastic proliferation of lymphocytes, is relatively common in many domestic and laboratory animal species [4]. The major forms of lymphosarcoma in animals, were grouped according to anatomical locations of tumor involvement [1]. The proportional distribution of anatomic forms varies from species to species, such as multicentric lymphosarcoma, thymic lymphosarcoma, alimentary lymphosarcoma, dermal lymphosarcoma and solitary lymphosarcoma [2]. Alimentary lymphosarcoma, the predominant lesions in the alimentary form are in the gastrointestinal tract and its regional nodes. The superficial lymph nodes are usually not affected. Other abdominal organs, especially the kidney, liver, and spleen, can also be affected, but other organs are rarely involved [3].

In this paper, we describe a case of alimentary lymphosarcoma in the mice of the research on the expression and effects of Adrenomedullin (AM) to the Alcohol induced liver disease (ALD).

### Case report

Progress in understanding the pathogenesis of ALD is critically dependent on the availability of suitable experimental models, AM wild type mice and AM deficient mice were used. In order to induce disease, pure alcohol was diluted in the drinking water: 10% (v/v) alcohol for 12 weeks.

The timing of sacrifice for the study of liver damage, we found that the tumor masses on the mesentery and intestine (Fig. 1A). Grossly, the excised intestine and mesentery showed markedly multinodular masses (Fig. 1B, 1C), and soft-to-firm, cream-colored, displayed protuberance into the lumen (Fig. 1D), intestine severely thickened (Fig. 1D) and the spleen was also enlarged (Fig. 1A). Tissue samples from the neoplastic masses of mesenteric lymph nodes, small intestine, and the liver and other representative parenchymal organs were fixed in 10% phosphate buffered neutral formalin, processed routinely, and stained with Hematoxylin and Eosin (H&E) for light microscopic examination.

Histologically, the mesenteric lymph nodes were composed of a dense population of neoplastic lymphoid cells resulting in the complete obliteration of the normal architecture of the lymph nodes (Fig. 2A). Neoplastic cells infiltrated multiple organs, the cells were well-differentiated lymphocytes which had round hyperchromatic nuclei and

\*Corresponding author

Tel : +82-53-950-5975, Fax : +82-53-950-5955

E-mail : jeongks@knu.ac.kr

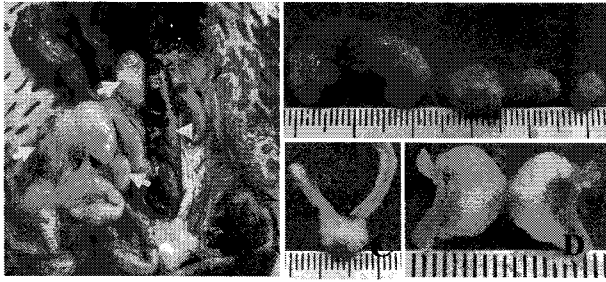


Fig. 1. A, Gross finding of the neoplastic masses of mesenteric lymph node and small intestine (*arrow*), the spleen was enlarged (*arrow head*). B, Note the neoplastic masses in the mesenteric lymph nodes. C, Note the neoplastic mass in the intestine, displayed protuberance into the lumen. D, Note the soft-to-firm, cream-colored cut surface of the tumor mass in the intestine, and the intestinal wall marked thickening.

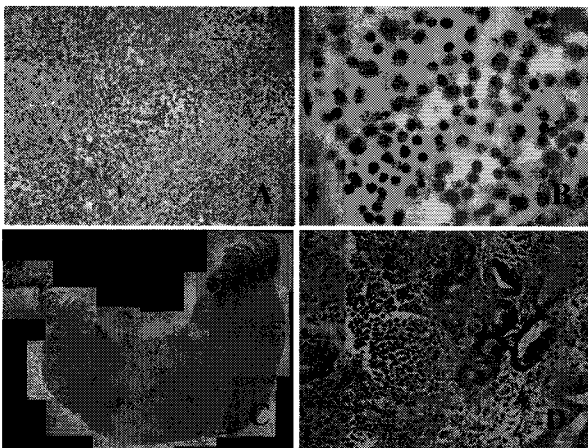


Fig. 2. A, Lymphosarcoma in the mesentery, note the neoplastic cells are round and have hyperchromatic nuclei with a small amount of cytoplasm. H&E stain,  $\times 33$ . B, Lymphoblastic lymphocytes that have hyperchromatic nuclei with a small amount of cytoplasm and macrophages and mitotic figures were seen. H&E,  $\times 132$ . C, Note the neoplastic cells were mainly infiltrated into mucosa and submucosa of the small intestine, and they had diffusely invaded the mucosa. H&E,  $\times 33$ . D, Note the infiltration of neoplastic lymphocytes into the small intestine mucosa. H&E,  $\times 132$ .

a small amount of cytoplasm with distinct borders (Fig. 2A, 2B). The frequency of mitotic figures was low (Fig. 2B). The neoplastic lymphocytes invaded and infiltrated into the mucosa, submucosa and muscle layer of the small intestine (Fig. 2C, 2D) and were also present in the liver which infiltrate in the portal areas and sinusoids (Fig. 3D). No neoplastic infiltrates were found in other organs.

To identify the cell origin of the neoplastic lymphocytes,

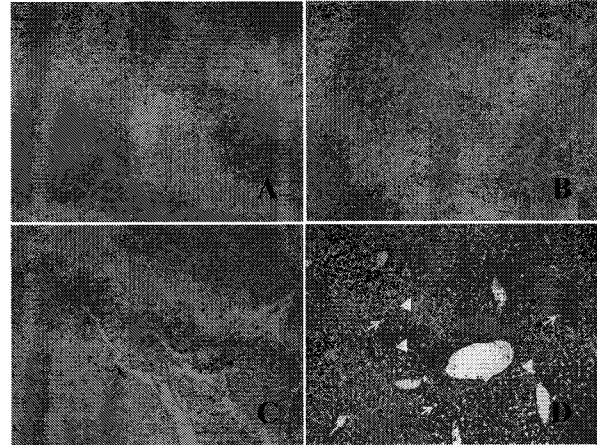


Fig. 3. A, Neoplastic cells were positively stained for the CD20 antibody in the tumorous lesions of mesentery and small intestine,  $\times 66$ . B, Immunohistochemical stain for vimentin antibody, the positive cytoplasmic distributed around the neoplastic cells,  $\times 66$ . C, Note the positive cells of CD3, local positive in the tumor mass,  $\times 66$ . D, Neoplastic lymphocytes infiltrated in the liver in the portal areas and sinusoids (*arrowhead*), and mild fatty change was seen (*arrow*). H&E,  $\times 66$ .

consecutive sections were stained immunohistochemically with using the avidinbiotin-peroxidase complex method (Vectastain ABC kit; Vector, USA). The primary antibodies we used included monoclonal CD20 antibody (1:100; DakoCytomation, USA) as the B-cell marker and CD3 (1:100; NeoMarkers, USA) as T lymphocytes marker, and the antibody of Vetamin (1:00, clone V9, DAKO) as for distinguishing non-epithelial from epithelial derived neoplasm. On the immunohistochemical results, the tumor cells were diffusely positive for CD20 (Fig. 3A) and vimentin (Fig. 3B), and local positive for CD3 (Fig. 3C).

## Discussion

Alcohol-induced liver disease (ALD) comprises various stages from fatty liver to alcohol hepatitis culminating with the development of cirrhosis [7]. In the study of investigating the expression and effects of AM in the liver injured by ethanol in our laboratory, there were lymphosarcomas involving mesenteric lymph node and intestine discovered in wild experimental groups.

Lymphosarcoma is the most common neoplasm of most animals [4]. In the present case, a diagnosis was made on the basis of gross findings, cytology, light microscopic features and immunohistochemistry. Therefore, the diagnosis

determined that the experimental mice of ethanol administered had malignant lymphosarcoma associated with mixture of B cells and T cells. An interesting aspect of gastrointestinal tumors is their frequent association with environmental carcinogens [8]. In our study, ethanol may be the factor of the tumor in the intestine and mesentery.

In lymphosarcomas of dogs, the cell types most commonly encountered are histiocytic and poorly differentiated; whereas in cats the predominant cell types are either prolymphocytic, histiocytic or mixed lymphocyte-histiocytic types in multicentric lymphomas [6]. There were some significant cytological differences between this case and the lymphosarcoma documented above. We found predominant infiltration in the liver, and the neoplastic cells well-differentiated, had round hyperchromatic nuclei and a small amount of cytoplasm with distinct borders. Based on the immunohistochemistry, the tumor cells positively expressed anti-CD20 antibody and anti-CD3 antibody, it is a mixture lymphosarcoma. Herein, this case is a malignant mixed lymphosarcoma in the intestine and mesentery in the experimental mice associated with the Alcohol-induced liver disease. It is hoped that this will be a topic for future investigation.

### Acknowledgment

This research was supported by a grant (code: CBM 31-B3003-01-01-00) from the Center for Biological Modulators of the 21st Century Frontier R&D Program, the Ministry of

Science and Technology, Korea.

### References

1. Anderson, L. J., W. F. H. Jarrett and G. W. Crighton. 1969. A classification of lymphoid neoplasms of domestic mammals. pp. 343-353, *In: Lingeman, C. H. and Garner, F. M. (eds), Comparative morphology of hematopoietic neoplasms.* National Cancer Institute Monograph 32, U. S. Government Printing Office.
2. Anderson, L. J., A. T. Sandison and W. F. H. Jarrett. 1969. A British Abattoir Survey of Tumors in Cattle, Sheep and Pigs. *Vet. Rec.* **84**, 547-551.
3. Jack, E. M. 1978. *Tumors in domestic animals.* pp. 150-196, 2nd eds., The Regents of the University of California, London, England.
4. Jones, T. C., R. D. Hunt and N. W. King. 1997. *Veterinary pathology,* pp. 1034-1042, 6th eds., Williams and Wilkins, Baltimore, Maryland.
5. Jubb, K. V. F., P. C. Kennedy and N. Palmer. 1993. *Pathology of Domestic Animals.* pp. 611-612, 4th eds., Academic Press, San Diego, California.
6. Moulton, J. E. and J. W. Haevey. 1990. *Tumors of the lymphoid and hematopoietic tissues. In: Tumors in domestic animals,* pp. 231-307, 3rd eds., University of California Press, Berkeley, California.
7. Nanji, A. A. and D. Zakim. 1996. *Hepatology: A Textbook of Liver Disease.* pp. 911-913, 3rd eds., W. B. Saunders Co., Philadelphia.
8. Radaszkiewicz, T., B. Dragosics and P. Bauer. 1992. Gastrointestinal malignant lymphomas of the mucosa-associated lymphoid tissue: factors relevant to prognosis. *Gastroenterology* **102**, 1628-1638.

### 초록 : 알코올성 간질환 마우스에서 발생한 장 내 및 장간막 림프육종

위엔동웨이 · 양해걸 · 홍일화 · 기미란 · 박진규 · 구문정 · 이혜림 · 유성은<sup>1</sup> · 정규식\*  
(경북대학교 수의과대학 병리학교실, <sup>1</sup>한국화학연구원)

알코올 유도성 조직 손상에 있어서 adrenomedullin의 발현 및 그 영향에 대한 연구 중, 실험 마우스 중의 한 개체에서 장간막 림프종과 장 내에서 림프육종이 발생한 것을 확인하였다. 림프육종은 마우스 계통에 따라 발생률이 다르지만 알려진 바로는 두 번째로 발생률이 높은 자발성 종양 질환 중 하나이다. 본 증례에서 육안적인 관찰 결과, 절제된 장에서 다소 경도가 높거나 연한 경도를 가지는 부분이 혼재된 크림색의 mass가 내강으로 돌출된 것과 함께 장간막에서 역시 동일한 형태의 mass가 관찰되었다. 종양성 세포들은 주로 점막 내로 침습하고 있는 모습을 나타내고 있으며 원형의 과염색성 핵과 소량의 세포질을 함유하고 있었다. 본 림프계 종양에 있어서 그 세포들의 기원은 CD20, CD3, vimentin에 대한 면역염색을 실시하여 확인하였다.