

Bone reaction to bovine hydroxyapatite grafted in the mandibular defects of beagle dogs.

Yu-Kyung Byun · Jun-Beom Park · Tae-Il Kim · Yang-Jo Seol · Yong-Moo Lee ·
Young Ku · Hye-Ja Lee · Chong-Pyoung Chung · Soo-Boo Han · In-Chul Rhyu

Department of Periodontology, College of Dentistry, Seoul National University

I. Introduction

Guided bone regeneration(GBR) is a well-established technique, both in the re-constructing of atrophic alveolar bone prior to implant placement and around exposed implant surfaces at the time of implant installation.¹⁻⁴⁾ For this promising technique, two basic components are needed - membrane and graft material.

The membranes itself placed and closely adapted around the defects can inhibit the nonosteogenic soft tissue cells and allow angiogenic and osteogenic cells from adjacent bone marrow to resolve the defects with bone tissue. But GBR therapy using membrane alone has encountered some complications. One of them is a membrane collapse due to the soft tissue pressure during healing period, causing decreased the

volume of created space.

Several attempts have been made to solve the membrane collapse. The use of stiffer membrane, i.e. titanium-reinforced e-PTFE membrane⁵⁾, or membrane supporting devices such as stainless steel microscrew¹ is one of them. Another method is the utilization of graft material. The graft material beneath the barrier membrane can support the occlusive membrane, stabilize the blood clot, and reduce the membrane shrinkage. In addition to its physical advantage, the graft material can influence the host response during healing.

Graft materials are used for the purpose of encouraging new bone formation by a variety of process - osteogenesis, osteoinduction, osteoconduction.⁶⁾ Autogenous bone is the only graft material known to induce bone formation through osteogenesis. Allogenic

*Corresponding author : In-Chul Rhyu, Department of Periodontology, College of Dentistry, Seoul National University, 28 Yongon-dong, Chongno-Ku, Seoul, 110-749, Korea, E-mail : icrhyu@snu.ac.kr

bone is thought to be osteoinductive because of the presence of growth factors. Xenografts and alloplastic substitutes are regarded to guide bone formation by osteoconduction. Although the use of autogenous bone is suggested as a 'gold standard' for effecting bone regeneration, the comparable results can be obtained using nonautogenous grafting materials.⁷⁾

Among available graft materials, natural bone mineral of bovine origin has shown good osteoconductive properties in various types of defects.⁸⁻¹²⁾

In this study, histologic and histomorphometric observations of bone sections obtained from defect sites at surgically created mandibular defects of beagle dogs that had been augmented with new bovine hydroxypapatite/collagen membrane are reported.

II. Materials and Methods

Surgical procedure in beagle dog mandible

Four beagle dogs were used in this study. All animals enrolled in this study were cared and processed in accordance with the Seoul National University Guidelines for the care and use of laboratory animals.

Every surgical procedure was done under general (ketamine, 7.5mg/kg, Yuhan Co., Korea and rompun, 3.5mg/kg, Bayer Korea, Korea) and local (lidocaine with 1:100,000 epinephrine, Yuhan Co., Korea) anesthesia. A sulcular incision was placed in the premolar, molar regions on both sides of the mandible. Buccal-lingual full thickness flaps

were elevated. The 2nd/4th premolars on both sides of the mandible were carefully extracted. In the extraction sockets, the defects sized 8mm*6mm*5mm were made using carbide round bur under copious saline irrigation and the flaps were closed with interrupted sutures. Intramuscular injections of antibiotics were given for 3 days. The sutures were removed after 2 weeks.

After 4 weeks of healing, sulcus-crestal incisions were placed in the edentulous ridge and premolar, molar regions. Buccal-lingual full thickness flaps were elevated. The defect size was measured and the correction was done in case that the defect size was diminished.

Each defect was randomly assigned to 3 different groups : 'Graft(G)' group, 'Graft+ Membrane(GM)' group, and 'Non-graft(NG)' group. Defects of 'G' group were grafted with OCS-B® (Nibec Co., Seoul, Korea) and secured with interrupted sutures. Defects of 'GM' group were filled with OCS-B® and covered with Bio-Gide® (Geistlich Pharma AG., Wolhusen, Switzerland). In 'NG' group, the flaps were replaced and sutured without any graft material or membrane. Intramuscular injections of antibiotics were given for 3 days. The sutures were removed after 2 weeks.

Specimen preparation

The two dogs were sacrificed 4 and 6 weeks after graft procedure. The mandibles were removed and placed in the 10% neutral buffered formalin fixative. The extraction sites were dissected into blocks. The tissue

blocks were rinsed with water, dehydrated in a graded series of increasing ethanol concentrations and embedded in super low-viscosity embedding media (Polyscience Inc., Warrington, PA). Sections were prepared in the buccolingual plane and parallel with the long axis of the extraction socket using Exakt cutting-grinding system (Exakt Appreateb, Hamburg, Germany) set to a thickness of 30 μ m. The sections were stained in haematoxylin and eosin and examined under light microscope.

Histologic findings and histomorphometric analysis

After specimen preparation, conventional examination was done under light microscope(Olympus BH-2 light micro scope, Olympus Optical Co., Osaka, Japan) equipped with a digital camera(Olympus C-3030ZOOM, Olympus Optical Co., Osaka, Japan). Defect morphology resolved after healing was traced and its area was measured using an automated image analysis system(TDI Scope Eye, Seoul, Korea). Histomorphometric measurements of newly formed bone were confined to the central portions of the defect. The margin of new bone tissue in the identified portion of the defect was traced and the enclosed area was determined in average area fraction. All specimens were measured 3 times in random order by one researcher, and the means (\pm standard deviation) were determined.

Statistical analysis

The overall data was statistically analyzed with repeated measures of ANOVA with posthoc(Tukey)($p < 0.01$).

III. Results

<Histologic findings>

Non-graft(NG) group

The new bone primarily consisted of intensely stained woven bone. However, the regenerated bone close to the pre-existing bone exhibited a more lamellar structure. The defect showed a continued bone formation at 6 weeks.

Newly formed peripheral bone, mainly at the lower half of the defect, resulted in a significant bony defect, which primarily healed by connective tissue repair(Figure 1-A).

Graft(G) group

Newly formed bone was well evident in the defects filled with bovine hydroxyapatite. The grafted materials are in direct contact with the newly formed bone as well as with connective tissue(Figure 2-A). The osseous tissue around the grafted particles presented numerous osteocytes, typical to a woven bone pattern. At 6 week, the bridging of new bone tissue around graft particle was observed(Figure 3-A). However, at periphery of the defect, the new bone tissue was sparse compared to the center of the defect.

The defect was not collapsed as severely as 'NG' group and maintained its shape, but some specimens showed the slight ridge deformities(Figure 1-B).

Graft+Membrane(GM) group

Bone regeneration was similar to 'G' group(Figure 2-B, 3-B). However, the newly formed bone mass was more pronounced at the membrane-protected defects. New bone tissue was noticed peripherally, particularly under the membrane. A typical phenomenon was newly formed bone bridging the graft particles. The defect morphology was perfectly maintained in 'GM' group. The collagen membrane was clearly distinguished from soft tissue in 6 weeks specimen, but its degradation was detected in a few specimens.

<Histomorphometric analysis>

Recovered defect area (Table 1, Figure 4)

Table 1. Defect area square measurement(mm2).

| Group | 6 weeks |
|----------------|--------------|
| Non-Graft | 5.73±1.06 |
| Graft | 20.6±1.72* |
| Graft+Membrane | 21.7±3.18*.# |

*p<0.01, as compared with 'Non-Graft'

#statistical insignificance compared with 'Graft'

The square measurement of healed bony morphology at 6 weeks was 5.73(±1.06), 20.6(±1.72), and 21.7(±3.18) mm² for 'NG', 'G', and 'GM' group, respectively. Statistical significance was recorded between 'NG' group versus 'G' group or 'GM' group. However, no significant difference was found with regard to the use of membrane.

Regenerated bone area(Bone area fraction)
(Table 2, Figure 5)

Average bone area fraction of 'G' group in-

Table 2. Bone area fraction(%)

| Group | 4 weeks | 6 weeks |
|----------------|---------------|-------------------|
| Non-Graft | 15.24±3.47 | 20.51±5.98\$ |
| Graft | 26.08±4.58* | 32.33 ±2.66*.\$ |
| Graft+Membrane | 27.51±9.70*.# | 35.13 ±1.55*.#,\$ |

*p<0.01, as compared with 'Non-Graft'

statistical insignificance compared with 'Graft'

\$p<0.01, as compared with 4 weeks

creased with time: 26.08%(±4.58) and 32.33% (±2.66) at 4 and 6 weeks, respectively. Statistical difference between 4 to 6 weeks was found. Bone area fraction of 'GM' group averaged 27.51%(±9.70) and 35.13%(±1.55) at 4 and 6 weeks respectively and difference was significant.

No statistically significant difference was noted between 'G' group and 'GM' group in bone area fraction at 4(26.08% versus 27.51%), 6(32.33% versus 35.13%) weeks.

Average bone area fraction of 'NG' group increased 15.24%(±3.47) and 20.51%(±5.98) at 4 and 6 weeks respectively and it was statistically significant. But 'NG' group showed smaller regenerated bone area than 'G' group and 'GM' group, and the difference between 'NG' group and 'G' group or 'GM' group was statistically significant.

IV. Discussion

Bovine hydroxyapatite used in this study was capable of completely restoring experimental defects in dogs. The border between the old and newly formed bone was clearly distinguishable. Newly formed bone was observed in the grafted sites, as well as

in the non-grafted sites. Close observation indicated that bone formation started around the graft particles and then filled in the space between graft particles at a later time. Regenerated bone was intimately contact with the grafted particles.

At 6 weeks, the grafted defects showed full restoration to its original shape regardless of the membrane, but the non-grafted sites presented a significant concave surface. Most of the defect was packed with the particle in surgical site with graft material and barrier membrane. In grafted site without membrane, varying amounts of the particles extended beyond the defect boundaries, probably due to fluids or pressure of tongue or intraoral soft tissue. However, histologically, bovine hydroxyapatite grafted and uncovered sites showed comparable findings to the grafted and covered sites. This could be attributed to the excellent graft osteoconductivity that accelerated new bone formation. Furthermore, particle aggregation by itself may serve as a type of physical barrier that may inhibit soft tissue cell migration into the defect.

The clinical and histological success of bovine bone mineral was reported in many animal and human studies.

Araújo et al.¹³⁾ reported the successful lateral ridge augmentation using bovine-derived bone substitute in canine model. Compared to the autogenous block bone graft which underwent marked resorption, the biomaterial could retain its dimension, and allowed amounts of new bone to be formed within the graft material.

In Hockers's animal study¹⁴⁾, the deprote-

nized bovine bone mineral yielded similar results as autogenic bone grafts with respect to vertical bone regeneration, new bone-to-implant contact, area density of bone in the vicinity of the grafts, and bone-to-graft contact.

Zitzmann et al.¹⁵⁾ used Bio-oss® for alveolar ridge augmentation with collagen membrane, Bio-Gide® in humans. After 6 to 7 months following grafting, the histologic analysis revealed an intimate contact between woven bone and graft particle along 37% of the particle surfaces.

Anorganic bovine bone used in sinus augmentation procedures was also showed a good osteoconductivity.¹⁶⁾ Specimens retrieved from humans after varying healing periods from 6 months to 4 years after surgery showed that the graft particles were surrounded for the most part by mature, compact bone. No gaps were present at the interface between the bovine bone particle and neighboring newly formed bone.

Carmagnola and his colleagues¹⁷⁾ investigated the healing of human extraction sockets filled with Bio-Oss® particles and covered by Bio-Gide® membrane. After 7 months, 34.4% of new bone tissue was measured in specimens and average 40.3% of the particles was in contact with bone tissue.

Biocompatibility and osteoconductivity are two mandatory prerequisites for a bone substitute material applied in guided bone regeneration technique.¹⁸⁾ Xenografts derived from other species are processed to remove their antigenicity by various chemical and preparation techniques. These materials are

fabricated from the inorganic portion of bone from animals: the most common source is bovine. With the removal of the organic component, concerns about immunological reactions become nonexistent. The remaining inorganic structure provides a natural architectural matrix as well as an excellent source of calcium.²⁰⁾ So, bovine derived bone mineral may fulfill the requirements as a graft material. Some investigators emphasize the slow resorption rate of bovine bone^{18,19)} as a weakness of bovine bone mineral, but the slow resorption rate can be an advantage in specific clinical situations¹³. And the resorption rate itself is controversial, because some studies reported a predictable resorption of particle after 12 to 13 months postoperative in augmented sinus and extraction socket^{21,22)}.

In this study, new bovine hydroxyapatite was proved to be an excellent osteoconductive agent in grafted sites, which biologically incorporated with newly formed osseous tissue. Further studies about the resorption rate of bovine hydroxyapatite and its safety in humans are needed.

V. References

1. Buser D, Dula K, Belser U, Hirt H-P, Berthold H. Localized ridge augmentation using guided bone regeneration. I. Surgical procedure in the maxilla. *Int J Periodontics Restorative Dent* 1993;13: 29-45.
2. Buser D, Dula K, Hirt H-P, Schenk RK. Lateral ridge augmentation using autografts and barrier membranes: A clinical study with 40 partially edentulous patients. *J Oral Maxillofac Surg* 1996; 54:420-422.
3. Nevins M, Mellonig JT. The advantages of localized ridge augmentation prior to implant placement: A staged event. *Int J Periodontics Restorative Dent* 1994; 14:97-111.
4. Fugazzotto PA, Shanaman R, Manos T, Shectman R. Guided bone regeneration around titanium implants: Report of the treatment of 1,503 sites with clinical reentries. *Int J Periodontics Restorative Dent* 1997;17:292-299.
5. Jovanovic S, Nevins M. Bone formation utilizing titanium - reinforced barrier membranes. *Int J Periodontics Restorative Dent* 1995;15:57-69.
6. Norton MR, Odell EW, Thompson ID, Cook RJ. Efficacy of bovine bone mineral for alveolar augmentation: a human histologic study. *Clin Oral Impl Res* 2003;14:775-783.
7. Fugazzotto RA. Report of 302 consecutive ridge augmentation procedures: Technical considerations and clinical results. *Int J Oral Maxillofac Implants* 1998 ;13:358-368.
8. De Boever AL, De Boever JA. Guided bone regeneration around non-submerged implants in narrow alveolar ridges: a prospective long-term clinical study. *Clin Oral Implants Res* 2005;16: 549-56.
9. Tal H, Artzi Z, Moses O, Nimcovsky CE, Kozlovsky A. Guided periodontal regeneration using bilayered collagen membranes and bovine bone mineral in fenestration defects in the canine. *Int J*

- Periodontics Restorative Dent 2005;25:509-18.
10. Zucchelli G, Amore C, Montebugnoli L, De Sanctis M. Enamel matrix proteins and bovine porous bone mineral in the treatment of intrabony defects: a comparative controlled clinical trial. *J Periodontol* 2003 ;74:1725-35.
 11. Hising P, Bolin A, Branting C. Reconstruction of severely resorbed alveolar ridge crests with dental implants using a bovine bone mineral for augmentation. *Int J Oral Maxillofac Implants* 2001;16:90-97.
 12. Valentini P, Abensur D, Wenz B, Peetz M, Schenk R. Sinus grafting with porous bone mineral(Bio-oss): a study on 15 patients. *Int J Periodontics Restorative Dent* 2000;20:245-252.
 13. Araujo MG, Sonohara M, Hayacibara R, Cardaropoli G, Lindhe J. Lateral ridge augmentation by the use of grafts comprised of autologous bone or a biomaterial. An experiment in the dog. *J Clin Periodontol* 2003;29:1122-1131.
 14. Hockers T, Abensur D, Balentini P, Legrand R, Hammerle CHF. The combined use of bioresorbable membrane sand xenografts or autografts in the treatment of bone defects around implants. A study in beagle dogs. *Clin Oral Impl Res* 1999;10:487-498.
 15. Zitzmann NU, Schärer A, Marinello CP, Schupbach P, and Berglundh T. Alveolar ridge augmentation with Bio-Oss: A histologic study in humans. *Int J Periodontics Restorative Dent* 2001;21:289-295.
 16. Piattelli M, Favero GA, Scarano A, Osini G, Piattelli A. Bone reactions to anorganic bovine bone(Bio-Oss) used in sinus augmentation procedures: A histologic long-term report of 20 cases in humans. *Int J Oral Maxillofac Implants* 1999;14:835-840.
 17. Carmagnola D, Adriaens P, Berglundh T. Healing of human extraction sockets filled with Bio-Oss®. *Clin Oral Impl Res* 2003;14:137-143.
 18. Artzi Z, Givol N, Rohrer MD, Nemcovsky CE, Prasad HS Tal H. Qualitative and quantitative expression of bovine bone mineral in experimental bone defects. Part 2 : Morphometric Analysis. *J Periodontol* 2003;74:1153-1160.
 19. Artzi Z, Givol N, Rohrer MD, Nemcovsky CE, Prasad HS Tal H. Qualitative and quantitative expression of bovine bone mineral in experimental bone defects. Part 1: Description of a dog model and histological observations. *J Periodontol* 2003;74:1143-1152.
 20. Berglundh TM, Lindhe J. Healing around implants placed in bone defects treated with Bio-oss: an experimental study in the dog. *Clin Oral Implants Res* 1997;8:117-124.
 21. Fugazzotto PA. GBR using bovine bone matrix and resorbable and nonresorbable membranes. Part 1: Histologic results. *Int J Periodontics Restorative Dent* 2003;23:361-369.
 22. Fugazzotto PA. GBR using bovine bone matrix and resorbable and nonresorbable membranes. Part 2: Clinical results. *Int J Periodontics Restorative Dent* 2003;23:599-605.

사진 부도 설명

- Figure 1. Defect morphology of 'Non-graft' site(A) is severely collapsed compared to 'Graft'(B) or 'Graft+Membrane'(C) site.
(original magnification, x1.25)
- Figure 2. Histologic view of selected specimens(4 weeks). (A)'Graft' group : Note the early bone apposition on the bovine bone particles. (B)'Graft+Membrane' group : Graft particles intimately contact with woven bone and connective tissue. (original magnification, x100)
- Figure 3. Histologic view of selected specimens(6 weeks). (A)'Graft' group : Woven bone can be seen around bovine bone particle. (B)'Graft+Membrane' group : New bone network is established bridging the graft particles.
- Figure 4. Recovered defect area(mm²)
(A)Non-Graft group (B)Graft group
(dotted line : margin of resolved defect morphology)
(original magnification, x1.25)
(C)Comparison of recovered defect area square measurement
- Figure 5. Comparison of Bone area fraction

사진부도 (I)

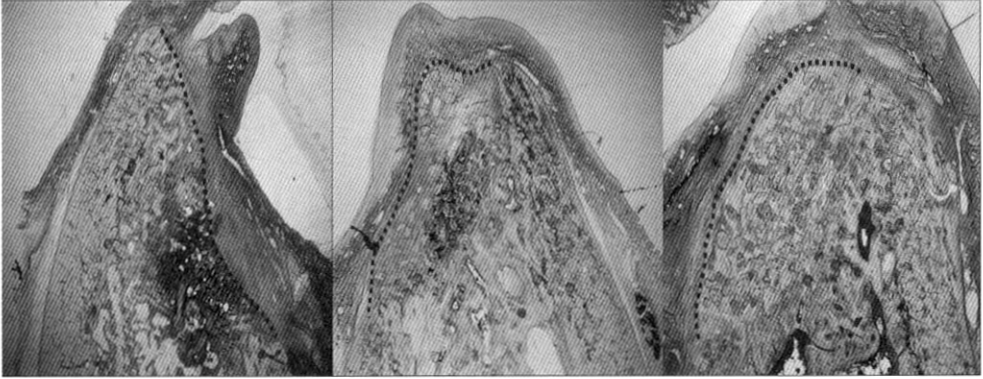


Figure 1. (A)

(B)

(C)

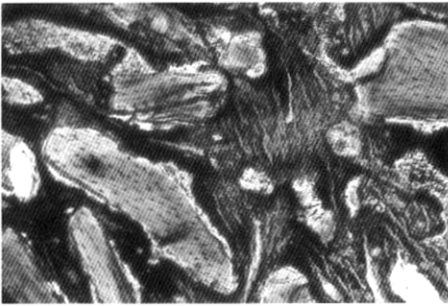
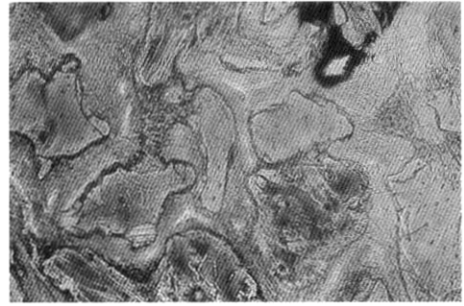


Figure 2. (A)



(B)

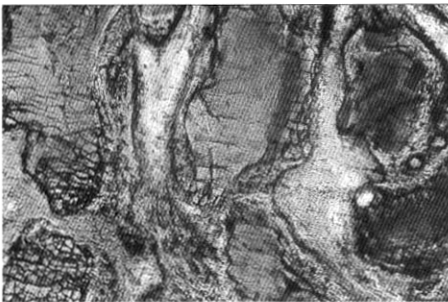
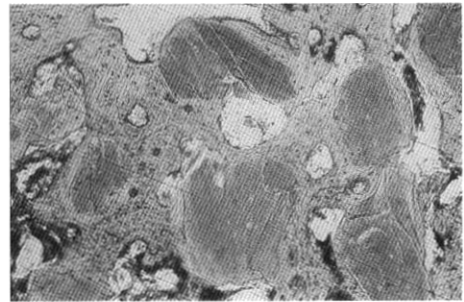


Figure 3. (A)



(B)

사진부도 (II)

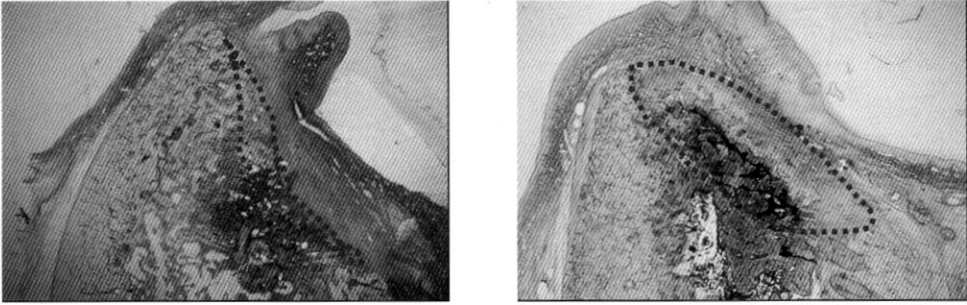
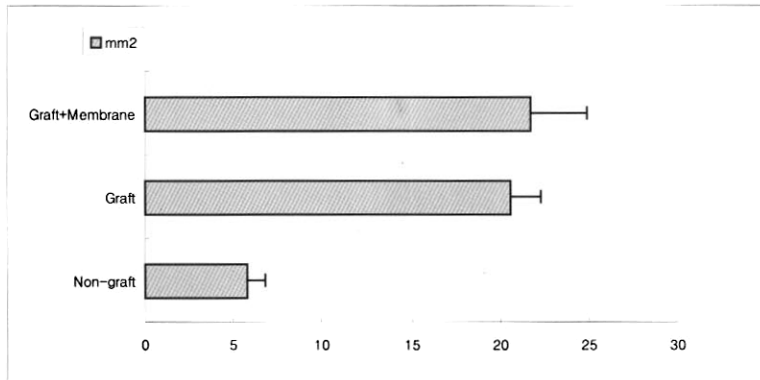


Figure 4. (A)

(B)



(c)

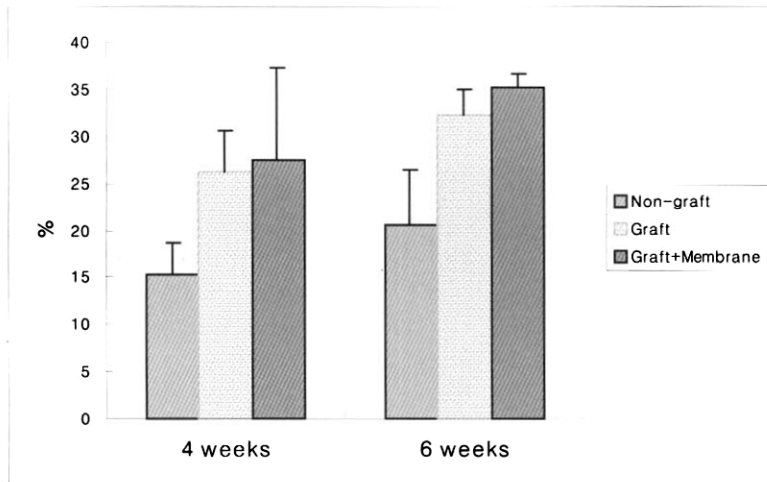


Figure 5.

성견의 하악 골 결손부에 이식한 생체 유래 골 이식재 (OCS-B)에 대한 치조골의 반응

변유경, 박준범, 김태일, 설양조, 이용무, 구 영, 이혜자, 정종평, 한수부, 류인철

서울대학교 치과대학 치주과학교실

1. 목 적

이 연구의 목적은 성견의 하악 골 결손부에 이식한 생체 유래 골 이식재에 대한 치조골의 반응을 알아보는 것이다.

2. 연구방법 및 재료

생후 1년 이상 된 성견 4마리의 하악 제2소구치 및 제 4 소구치를 발거하고 발치외에 근원심 폭경 8mm, 협설 폭경 5mm, 치조정에서의 깊이 6mm인 결손부를 형성하였다. 4주간의 자연 치유 후 판막을 형성하여 결손부의 크기를 확인하였다. 각각의 결손부 크기가 일정하도록 수정한 후 '이식재+차폐막'군에는 OCS-B을 이식하고 Bio-gide을 차단막으로 사용한 후 봉합하고 '이식재'군은 OCS-B 이식 후 차폐막 없이 봉합하였으며 '비이식'군은 아무런 처치없이 일차봉합하였다. 수술 4, 6주에 실험동물을 각각 희생시켜 실험부위를 적출하고 비탈회 연마 표본을 제작하여 골 치유 양상을 조직학적 및 조직계측학적으로 관찰하였다.

3. 연구 결과

이식재 비이식군 및 이식군 모두에서 별다른 부작용없이 잘 치유되었다. 세 실험군 모두에서 수술 후 4주에 비교하여 수술 후 6주에서의 결손부 신생골 형성량이 증가하였다. 수술 4주 소견에서 비이식군은 결손부 주변부위에서 골이 생성되어 나오는 양상을 보였으며 이식군은 이식재 주변으로 골침착이 시작되는 것을 관찰할 수 있었다. 수술 6주 소견에서 비이식군은 결손부 경계부로부터의 지속적인 골 생성을 관찰할 수 있었으며 이식군은 이식재 주변으로 침착된 골의 양이 많아지고 신생골이 가교를 형성하는 것을 관찰할 수 있었다.

4. 결 론

차폐막 유무와 상관없이 OCS-B는 염증반응을 전혀 일으키지 않았으며 우수한 골 전도성을 보였다. 또한 결손부의 형태를 잘 유지하여 골재생을 위한 공간을 확보할 수 있었다. 이는 OCS-B가 골이식재로서의 필요조건을 갖추었음을 확인한 결과이며 보다 장기적인 관찰에서 OCS-B의 흡수 가능성을 확인하는 것이 필요할 것으로 보인다.