

경피적 카테타 심방중격결손 폐쇄술 후 발생한 상행 대동맥-우심방루

임흥국* · 이창하* · 서홍주* · 김종환* · 김준석**

Fistula of Ascending Aorta and Right Atrium Following Percutaneous Transcatheter Atrial Septal Defect Closure

Hong Gook Lim, M.D.*, Chang-Ha Lee, M.D.*, Hong Joo Seo, M.D.*
Chong Whan Kim, M.D.*, Jun Seok Kim, M.D.**

Percutaneous transcatheter closure of atrial septal defects as a therapeutic alternative in appropriate patients provides superior cosmetic results, is less invasive, and allows for shorter hospital stays. Unfortunately, however, such percutaneous procedures can be associated with catastrophic procedure complications that may require immediate surgical intervention. We report a case of aorta-to-right atrial fistula two months after transcatheter occlusion of an atrial septal defect by an Amplatzer septal occluder. Revealed by dyspnea, palpitation and hemolysis, this complication needed an emergency surgical operation. The fistula between the noncoronary Valsalva sinus of the aorta and the right atrium was repaired. The atrial septal defect was closed by patch. The cause of this serious complication appears to be erosion into the aorta by the right atrial disk.

(Korean J Thorac Cardiovasc Surg 2006;39:150-153)

Key words: 1. Fistula
2. Prosthesis
3. Heart septal defect, atrial

CASE REPORT

A 54-year-old female patient was examined for dyspnea of NYHA II class and intermittent palpitation. On physical examination, a grade 2/6 systolic murmur with S₂ splitting was noted at the left upper sternal border. A baseline electrocardiogram showed sinus rhythm with a right bundle branch block pattern and left axis deviation, and a 24-hour Holter monitoring frequent atrial premature contractions. The transthoracic echocardiography (TTE) showed secundum atrial septal defect (ASD) measuring 20×22 mm in diameter, with a

significant left-to-right shunt with pulmonary to systolic flow Qp/Qs ratio of 3 : 1, right atrial and ventricular enlargement, and tricuspid regurgitation of Gr I-II due to mild prolapse of anterior leaflet with pressure gradients of 35 mmHg. In anatomic terms, the anterosuperior atrial septal defect rim had been developed above about 20 mm, and the posteroinferior rim was deficient, especially 6~7 mm from mitral valve. Since the defect appeared to be favorable for device closure due to adequate septal tissue margins except for a small inferior rim, a transcatheter approach was recommended.

After obtaining informed consent, cardiac catheterization

*부천세종병원 흉부외과, 세종심장연구소

Department of Thoracic and Cardiovascular Surgery, Sejong General Hospital, Sejong Heart Institute

**건국대학교병원 흉부외과

Department of Thoracic and Cardiovascular Surgery, School of Medicine, Konkuk University

논문접수일 : 2005년 10월 4일, 심사통과일 : 2005년 11월 16일

책임저자 : 이창하 (422-711) 경기도 부천시 소사구 소사본 2동 91-121번지, 부천세종병원 흉부외과

(Tel) 032-340-1151, (Fax) 032-340-1236, E-mail: leechha@sejongh.co.kr

본 논문의 저작권 및 전자매체의 지적소유권은 대한흉부외과학회에 있다.

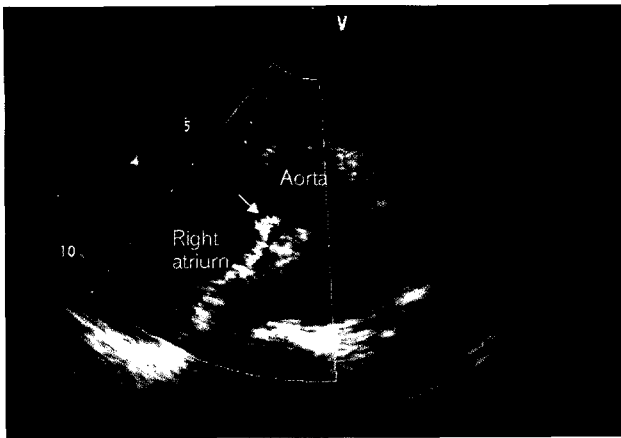


Fig. 1. Transthoracic echocardiography in the parasternal short-axis view 2 months after the Amplatzer Septal Occluder implantation. The presence of the aorta-to-right atrial fistula (arrow) is confirmed.

was performed under general anesthesia, and the delivery of Amplatzer Septal Occluder (AGA Medical, Golden Valley, MN, USA) (ASO) was guided by both fluoroscopy and transesophageal echocardiography using a multi-plane probe. The balloon-stretched ASD diameter was 27 mm, and a 28 mm ASO was positioned appropriately within the atrial septum. Technically, the implantation was successful without any residual shunt. After the procedure, the patient did well. Follow-up noninvasive evaluation revealed complete closure of the ASD and excellent device position.

She started to complain of the dyspnea of NYHA II class, palpitation and jaundice approximately 2 months after the procedure. A new grade 2/6 high-pitched continuous murmur was heard at the mid left sternal border. Mild cardiomegaly was seen on the chest roentgenogram. A TTE revealed mild right atrial enlargement and a small fistula between the posterior aortic sinus and the right atrium. Continuous color flow entered the right atrium at the right superior edge of the right atrial disk of the ASO at pressure gradients of 120 mmHg (Fig. 1). Blood studies revealed anemia and hyperbilirubinemia.

An urgent surgical exploration was performed. The patient was transferred to the operating room. A median sternotomy was performed, and cardiopulmonary bypass was established. During administration of cardioplegia, blood was seen entering the opened right atrium through the fistula directly at the edge of the right atrial disk, and aortic root pressure was not

sufficient. Right atrium was opened and the fistula was temporarily compressed.

After heart was arrested, we noted the ASO to be in good position and to be nearly completely endothelialized. After careful surgical removal of the device, the fistula was easily identified from the right atrium. We found that the smaller right-side ASO disc had cut through the dome of the right atrium between the superior vena cava and the aortic root where it created a 5-mm fistula (Fig. 2A). After opening the ascending aorta, fistula opening was at the aortic root in the central region of the non-coronary sinus, where the occluder was eroded against the aorta via the dome of the right atrium. The aortic wall fistula opening was measured approximately 5 mm diameter (Fig. 2B). The aortic fistula opening was closed with 5-0 Prolene (Ethicon, Inc, Somerville, NJ) interrupted suture supported with pericardial pledgets, and the atrial fistula opening was closed continuously with 6-0 Prolene. The large septal defect was closed using a pericardial patch, and De Vega type tricuspid annuloplasty was then performed. Extracorporeal circulation was discontinued without complications. The pericardium was loosely reapproximated. Chest tubes were placed and the sternal incision was closed in the usual fashion. At the conclusion of the operation, transesophageal echocardiography confirmed normal biventricular function. Color-flow mapping failed to identify any residual left-to-right shunt. The post-operative course was uneventful. Gross pathologic survey of the device showed no structural defects.

DISCUSSION

Surgery remains the standard of care for ASD repair with excellent long-term results since 1954, and low operative mortality and morbidity[1]. Moreover, recent improvements of surgical techniques with less invasive approaches through smaller incisions and improved perfusion techniques have reduced both length of hospital stay and costs. More recently, endoscopic ASD closure with telemanipulating robotic systems has become available, permitting rapid postoperative recovery with excellent cosmetic results[2].

Transcatheter delivery of the Amplatzer septal occluder is becoming the preferred method of closing secundum ASDs



Fig. 2. Operative findings. (A) After right atrium is opened and the device is removed, the opening of the aorta-to-right atrial fistula is shown at the anterosuperior margin of atrial septum. (B) After aorta is opened, the opening of the aorta-to-right atrial fistula is located in the central region of noncoronary sinus in aortic root.

when the anatomy is suitable, principally due to the patient's desire for a "less invasive procedure," and the reputed procedural efficacy and safety. Unfortunately, however, the early complications after implantation of an Amplatzer device are arrhythmias, transient ST-T elevation in the inferior leads, residual shunts, hemolysis, malpositions and dislocations of device, device embolization into the left atrium, right atrium, right ventricle and pulmonary arterial tree, thromboembolization into the central nervous system, peripheral embolization into the leg, injury of groin vessels at the place of a puncture, device impingement on caval veins, on the right upper pulmonary vein, and on the mitral and tricupsid valves, thrombus of the device, infectious endocarditis, and sudden death[3,4]. These complications may require conversion to an immediate surgical repair.

Cardiac erosion/perforation of the device through the atrial wall, associated with pericardial tamponade is a rare complication which has been reported in the literature[5,6], though their actual number is probably higher. This complication may occur early or even several months after the implantation. All patients presented with chest pain, dyspnea, or sudden hemodynamic collapse. This perforation is located at the dome of the right or left atrium by the right or left-side ASD disc which may perforate even the aortic root in a non-coronary sinus. In all these cases, the anterosuperior atrial septal

rim was absent.

The development of fistulas between the atria and the aorta is very rare but recognized lethal complication, which is frequently associated with traumatic accident such as an automobile accident, and follow-up is ongoing. It appears that the anterosuperior, or retroaortic portion of the atrial wall is affected. The presumed mechanism for this complication is erosion into the ascending aorta by the right atrial disk. The flattening of the device within a limited area of atrial septum may have resulted in wedging of the right atrial disk to create the concave shape of the right atrial disk seen at surgery, and outward radial pressure may occur at the rims of the device. Another possible mechanism might relate to the time-frame at which device flattening occurred. Earlier occurrence of device flattening prior to endothelialization may permit more abrasion of the aortic mound by the device during its movement with the cardiac cycle. Therefore, selection of the appropriate device size is of paramount importance for effective and safe ASD closure[7].

This patient developed an aorto-atrial fistula which was manifested by dyspnea, palpitation, and haemolysis 2 months after the ASD implantation. However, she was not involved in any traumatic accident. The anterosuperior, or retroaortic portion of the atrial wall was affected, on the right atrial side of the septum. The absence of atrial septal defect rims is a

risk factor which may have an adverse effect on the outcome of ASO implantation, but she had sufficient anterosuperior rim according to pre-implantation echocardiographic examination. In the case of our patient, echocardiography performed immediately after the ASO implantation showed a close contact of both ASO discs with the ascending aorta. The occluder was not positioned in such a manner that both the right-side and the left-side disc would touch the aorta in a saddle-like manner and touch it tangentially. The right-side disc was pressed closely against the aorta, which resulted in the cutting of the right disc through the right atrium to the aortic root.

During the last two years there have been ASO implantations in 47 patients with ASD in our hospital, one of whom developed above-mentioned complication (the risk is 2.1%). This is the first successful case report of symptomatic aorta-to-right atrial fistula after transcatheter occlusion of an atrial septal defect by an Amplatzer septal occluder. This case suggests that it is possible for aorta-to-right atrial fistula to occur even in the patient with sufficient anterolateral rim and no trauma history. Information on long-term complications is currently being collected. Certain anatomic variants of ASD may be better approached with one technique or the other. Familiarity with the devices and knowledge of their potential complications and surgical implications by the cardiothoracic surgical community are increasingly important. Therefore, a decision for selection criteria has to be prudently made. While this patient had symptoms as well as cardiomegaly, even in symptom-free patient, deficient anterolateral rim or

trauma history warrants follow-up and warning for this catastrophic event which has the possibility of sudden death. It is important to maintain close follow-up so that complications may be detected and treated, and we recommend close follow-up, especially at 1 to 2 months after closure.

REFERENCES

1. Murphy JG, Gersh BJ, McGoon MD, et al. *Long term outcome after surgical repair of isolated atrial septal defect. Follow-up at 27 to 32 years.* N Engl J Med 1990;323:1645-50.
2. Torracca L, Ismeno G, Alfieri O. *Totally endoscopic computer-enhanced atrial septal defect closure in six patients.* Ann Thorac Surg 2001;72:1354-7.
3. Chessa M, Carminati M, Butera G, et al. *Early and late complications associated with transcatheter occlusion of secundum atrial septal defect.* J Am Coll Cardiol 2002;39:1061-5.
4. Berdat PA, Chatterjee T, Pfammatter JP, Windecker S, Meier B, Carrel T. *Surgical management of complications after transcatheter closure of an atrial septal defect or patent foramen ovale.* J Thorac Cardiovasc Surg 2000;120:1034-9.
5. Preventza O, Sampath-Kumar S, Wasnick J, Gold JP. *Late cardiac perforation following transcatheter atrial septal defect closure.* Ann Thorac Surg 2004;77:1435-7.
6. Aggoun Y, Gallet B, Acar P, et al. *Perforation of the aorta after percutaneous closure of an atrial septal defect with an Amplatzer prosthesis, presenting with acute severe hemolysis.* Arch Mal Coeur Vaiss 2002;95:479-82.
7. Chun DS, Turrentine MW, Moustapha A, Hoyer MH. *Development of aorta-to-right atrial fistula following closure of secundum atrial septal defect using the Amplatzer septal occluder.* Catheter Cardiovasc Interv 2003;58:246-51.

=국문 초록=

심방 중격 결손에 대한 경피적 카테타 폐쇄술은 적절한 환자에서 치료적 대안으로 이용되며, 미용적으로 우수하고, 덜 침습적이며, 재원 기간이 짧으나, 응급 수술이 요구되는 치명적인 합병증이 발생할 수 있다. 저자들은 Amplatzer septal occluder에 의한 심방 중격 결손의 경피적 카테타 폐쇄술 시행 후 발생한 대동맥-우심방루를 경험하였다. 시술 2개월 후에 호흡곤란, 심계항진과 용혈에 의한 황달로 발견되어, 대동맥의 무관상동맥동과 우심방 사이의 누공을 일차 봉합하고, 심방 중격 결손은 팻취로 봉합하는 응급수술을 시행하였다. 이 합병증은 우심방 원반(disk)이 대동맥으로 침식(erosion)하여 발생하였다.

- 중심 단어 : 1. 누공
2. 인공삽입물
3. 심방중격결손