

## Acute hemorrhagic edema in an infant mimicking Henoch-Schönlein purpura: a case study

Hyang Mo Lee, M.D., Eun Young Kang, M.D.  
Han Uk Kim, M.D\* and Pyoung Han Hwang, M.D.

Department of Pediatrics and Dermatology\*, the Research Institute of Clinical Medicine, School of Medicine  
Chonbuk National University, Jeonju, Korea

Acute hemorrhagic edema of infancy (AHEI) is an uncommon form of cutaneous leukocytoclastic vasculitis that occurs in infants and children younger than 2 years. AHEI is characterized clinically by marked peripheral edema and fever as well as large palpable purpuric and ecchymotic skin lesions in a target-like pattern, mainly on the face, ears and extremities, similar to the skin findings of Henoch-Schönlein purpura (HSP). The skin lesions heal spontaneously within one to three weeks and internal organs are rarely affected. We report a case of AHEI occurring in a 23-month-old boy who was initially misdiagnosed as HSP, and was later diagnosed according to his clinical symptoms and histochemical characteristics. (**Korean J Pediatr** 2006;49:1354-1357)

**Key Words :** Acute hemorrhagic edema of infancy (AHEI), Leukocytoclastic vasculitis, Purpura

### Introduction

Leukocytoclastic vasculitis is a small vessel hypersensitivity response and is the most common form of vasculitis in all age groups<sup>1)</sup>. Acute hemorrhagic edema of infancy (AHEI) is a leukocytoclastic vasculitis affecting children aged between 4 and 24 months that was first described by Snow<sup>2)</sup> in 1913. It has also been called postinfectious cockade purpura (Seidlmayer's disease) and Finkelstein's disease<sup>3,4)</sup>. The causes of AHEI are unclear. However, Infection, drugs and immunization have been considered as precipitating factors.

AHEI is characterized clinically by marked edema and fever as well as painful palpable purpuric and ecchymotic skin lesions in a target-like pattern mainly on the face, ears and extremities. The cutaneous findings are dramatic in both appearance and rapidity of onset, and may be confused with those of Henoch-Schönlein purpura (HSP), but there usually is no visceral involvement. Laboratory studies of patients with AHEI typically show normal results and the disorder follows a benign course with spontaneous resolution occurring

in 1 to 3 weeks.

We report a case of AHEI, which was initially misdiagnosed as HSP and was later diagnosed according to the clinical symptoms and the histopathologic characteristics, and the review of the literatures.

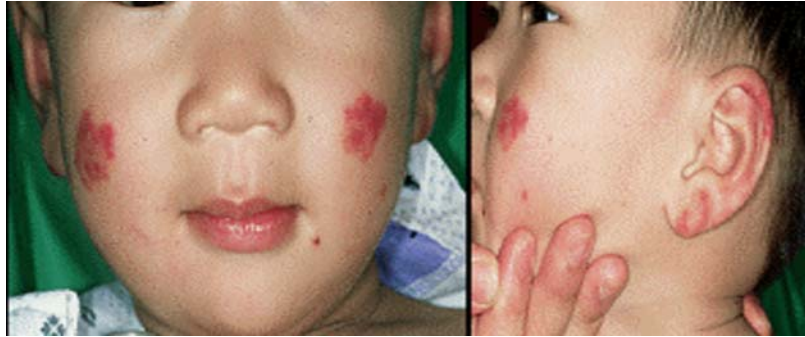### Case Report

A 23-month-old male patient visited to Chonbuk National University Hospital with purpura and painful edema on both lower extremities. He had several episodes of fever for 3 days and upper respiratory symptoms for 1 week. He had the history of medication with antibiotics for 2 days.

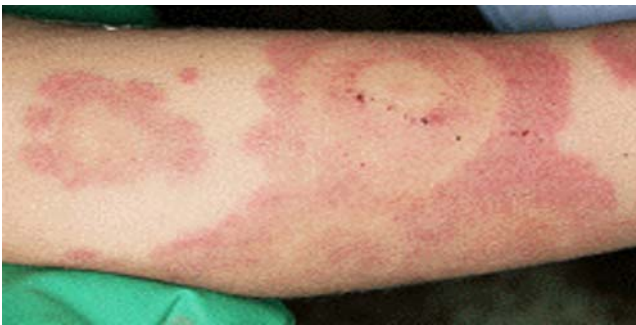He presented with bilateral, annular and purpuric lesions, measuring approximately 1-2 cm each, located on the malar region of the face and both ears (Fig. 1). Additionally, the patient had many annular lesions, varying from 0.5 to 2.5 cm in diameter, some became targetoid or coalescent, all over the upper and lower extremities (Fig. 2), and nonpitting, tender edema of both distal extremities. The remaining physical examination was normal.

Laboratory findings showed the followings: leukocytes 9,860/mm<sup>3</sup> with 52.5% neutrophils, 36.4% lymphocytes, platelet 234,000/mm<sup>3</sup>, erythrocyte sedimentation rate 31 mm/hr; clotting tests were normal. Urinalysis, ASO, antinuclear factor,

접수 : 2006년 8월 22일, 승인 : 2006년 9월 27일  
책임저자 : 황평한, 전북대학교 의과대학 소아과학교실  
Correspondence : Pyoung Han Hwang, M.D.  
Tel : 063)250-1472 Fax : 062)250-1464  
E-mail : hwaph@chonbuk.ac.kr



**Fig. 1.** Bilateral, infiltrated, annular and purpuric lesion of both malar areas of the face and erythematous purpura on the left ear.



**Fig. 2.** Multiple targetoid or cockade purpura on lower leg, characteristic of acute hemorrhagic edema of infancy.

serum complements, liver and kidney function tests were all within the normal range.

At admission day, the patient was treated with oral corticosteroid under the impression of HSP. However, some skin lesions showed central necrotic changes. So we considered the possibility of bacterial infection or another vasculitis symptoms, added prescription of antibiotics, and performed skin biopsy at right medial thigh lesion. The histological analysis demonstrated leukocytoclastic vasculitis of small vessels with nuclear dusts, eosinophils and extravasation of red blood cells (Fig. 3). The diagnosis of AHEI was made according to clinical and histopathologic features.

He was treated with oral corticosteroid continuously, which resulted in reduction of edema. The infant was discharged 7 days of admission with marked improvement. The cutaneous lesions resolved and no recurrence has occurred.

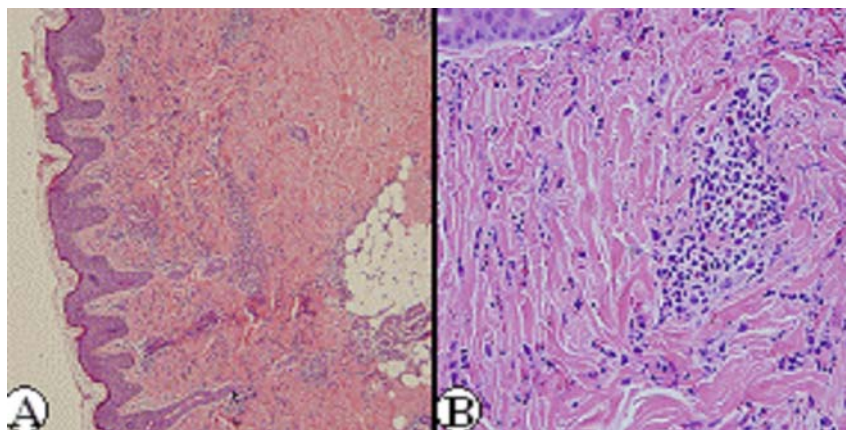
## Discussion

AHEI is a kind of leukocytoclastic vasculitis mediated by immune complexes. Circulating antigen-antibody complexes are deposited within blood vessel walls leading to activation

of complements. Chemotactic factors are released. Neutrophils migrate to the site and release proteolytic enzymes resulting in endothelial damage, typically of the postcapillary venules<sup>1</sup>.

The cause of AHEI is, unfortunately, still unknown. However, bacterial or viral infections, drugs<sup>5</sup>, and, less frequently, immunization are suggested to be the likely triggering mechanisms<sup>3, 6</sup>. Because of the association with respiratory infections, winter seems to be the season in which most cases of AHEI are likely to occur<sup>7</sup>. In our case, the patient had prodromal period with fever and upper respiratory symptoms of 2-3 days before the development of skin lesions.

The symptom is acute and dramatic with large, round, red to purpuric plaques predominantly over the cheeks, ears, and extremities, with relative sparing of the trunk. Some lesions may have a target-like, or cockade appearance. Fever and tender edema of the distal extremities, ears, and eyelids are characteristic features<sup>5-7</sup>. Although AHEI was initially thought to represent an infantile variant of HSP, it is recently suggested that AHEI should be considered as a separate entity<sup>8, 9</sup>. The differences between AHEI and HSP begin with the age of the patients: typically, the former affects children aged 4 months to 2 years, and the latter affects children aged 3 to 6 years<sup>3, 10</sup>. Classic features of AHEI do not include symptoms such as vomiting, abdominal pain, renal alterations and joint involvement, which are characteristics of HSP<sup>10, 11</sup>. The increase in serum IgA, which is typical of HSP, has not been reported either. Both disorders have histologic features of leukocytoclastic vasculitis, but AHEI does not show the perivascular IgA deposition seen in HSP<sup>7, 11, 12</sup>. Moreover, AHEI may depict IgM, fibrinogen and C3 (as with HSP), but it also presents C1q perivascular deposition, which is not found in HSP<sup>11, 12</sup>. AHEI is a benign eruption, and resolution of lesions is typically completed by 4-20 days. Relapses have not been reported for AHEI,



**Fig. 3.** The biopsy specimen of purpuric lesion on the thigh showed normal epidermis and leukocytoclastic vasculitis of the dermal vessels with fibrinoid necrosis, extravasation of red blood cells and nuclear dust (H&E stain, A:  $\times 40$ , B:  $\times 100$ ).

whereas episodes of HSP last for weeks and recur in 50% of cases<sup>13,14</sup>.

Because of the distinctive presentation, AHEI can usually be diagnosed by clinical examination and history alone. Routine laboratory tests are non-diagnostic. Serum immunoglobulin A, M, G, and E levels may be normal or increased. Skin biopsy is seldom necessary, but would confirm the presence of a leukocytoclastic vasculitis of the dermal vascular plexus. Histopathologic examination shows fibrinoid degeneration of vascular walls, nuclear dust, extravasated erythrocytes and interstitial edema. Because these findings are common to other forms of leukocytoclastic vasculitis, it has been suggested that clinicopathologic correlation is necessary for a diagnosis of AHEI. Immunofluorescence may or may not reveal fibrinogen and C3, IgA and IgM in and around the dermal vessels<sup>7,9</sup>. In the present study, skin biopsy was performed and histopathologic analysis demonstrated leukocytoclastic vasculitis of the dermal vessels with fibrinoid necrosis, extravasation of red blood cells and nuclear dust.

The clinical differential diagnosis of AHEI includes HSP, Sweet's syndrome, erythema multiforme, meningococcemia, Kawasaki disease, drug-induced vasculitis, septic vasculitis and trauma-induced purpura<sup>11</sup>. These disorders can be differentiated from AHEI by history taking, physical examination and appropriate laboratory studies, including examination of a skin biopsy specimen.

No specific treatment is available for AHEI. Treatment is usually supportive. It is recommended that antibiotics be given when there is evidence of concurrent infection. Systemic

steroid therapy and antihistamines appear to be ineffective for the treatment of AHEI<sup>14</sup>. Systemic corticosteroids were given for a short time in this patient at initiation, because HSP was suspected. In a previous Korean case report, the patient was not treated with steroids. But he also recovered clearly<sup>15</sup>. The prognosis of the disease is usually benign. Spontaneous and complete resolution of AHEI occurs within 1-3 weeks, without complications. Exceptionally, it may have a serious or fatal outcome<sup>7,16</sup>. Relapse does not occur. This patient also recovered without complications and no recurrence has been observed.

### 한 글 요약

### 헤노흐-셴라인 자반증으로 오인된 영아 급성 출혈성 부종 1례

전북대학교 의과대학 소아과학교실, 피부과학교실\*

이향모 · 강은영 · 김한욱\* · 황평한

영아 급성 출혈성 부종은 2세 이전에 발생하는 드문 혈관염의 일종이다. 영아 급성 출혈성 부종은 현저한 말단부 부종과 발열을 보이며 특징적으로 얼굴, 귀, 사지에 두드러지게 헤노흐-셴라인 자반증과 유사한 피부 병변이 발생한다. 이러한 피부 병변은 1주일에서 3주일 사이에 저절로 소실되며 헤노흐-셴라인 자반증과 달리 내부 장기의 침범은 거의 없다. 처음 헤노흐-셴라인 자반증으로 생각하였으나 특징적인 발진의 분포와 전신 증상의 부재 등의 차이로 영아 급성 출혈성 부종으로 진단하게 된 23개월 남아의 증례를 보고하는 바이다.

## References

- 1) Resnick AH, Esterly NB. Vasculitis in children. *Int J Dermatol* 1985;24: 139-46.
- 2) Snow IM. Purpura, urticaria and angioneurotic edema of the hands and feet in a nursing baby. *JAMA* 1913;61:18-9.
- 3) Cox NH. Seidlmayer's syndrome: postinfectious cockade purpura of early childhood. *J Am Acad Dermatol* 1992;26:275.
- 4) Long D, Helm KF. Acute hemorrhagic edema of infancy: Finkelstein's disease. *Cutis* 1998;61:283-4.
- 5) Smitt J, Vermeer M, Faber W. Acute Hemorrhagic edema of Infancy (AHEI). *Clin Dermatol* 2002;20:2-3.
- 6) Harper J, Oranje A, Prose N. *Textbook of Pediatric Dermatology*. London: Blackwell Science 2000;1569-73.
- 7) Legrain V, Lejean S, Taieb A, Guillard JM, Battin J, Maleville J. Infantile acute hemorrhagic edema of the skin: study of ten cases. *J Am Acad Dermatol* 1991;24:17-22.
- 8) Gonggryp LA, Todd G. Acute hemorrhagic edema of childhood. *Pediatr Dermatol* 1998;15:91-6.
- 9) Ince E, Mumcu Y, Suskan E, Yalcnkaya F, Tumer N, Cin S. Infantile acute hemorrhagic edema: A variant of leukocytoclastic vasculitis. *Pediatr Dermatol* 1995;12:224-7.
- 10) Gelmetti C, Barbagallo C, Cerri D. Acute haemorrhagic edema of the skin in infants: clinical and pathogenetic observations in seven cases. *Pediatr Dermatol News* 1985;4:23-34.
- 11) Saraclar Y, Tinaztepe K, Adalioglu G, Tuncer A. Acute infantile hemorrhagic edema of infancy (AHED)-a variant of Henoch-Schönlein purpura or a distinct clinical entity? *J Allergy Clin Immunol* 1990;86:473-83.
- 12) Krause I, Lazarov A, Rachmel A, Grunwald MM, Metzker A, Garty BZ, et al. Acute haemorrhagic oedema of infancy, a benign variant of leucocytoclastic vasculitis. *Acta Paediatr* 1996;85:114-7.
- 13) Millard T, Harris A, MacDonald D. Acute infantile hemorrhagic oedema. *J Am Acad Dermatol* 1999;41:837-9.
- 14) Caksen H, Odabas D, Kosem M, Arslan S, Oner AF, Atas B, et al. Report of eight infants with acute infantile hemorrhagic edema and review of the literature. *J Dermatol* 2002; 29:290-5.
- 15) Lee HJ, Lee DW, Kim SY, Cho BK, Oh CK. A case of infantile acute hemorrhagic edema. *J Korean Pediatr Soc* 1996; 39:1168-72.
- 16) Larregue M, Lorette G, Prigent F, Canuel C. Acute haemorrhagic edema of the skin of the newborn with lethal intestinal complication. *Ann Dermatol Venereol* 1980;107:901-5.