

Postoperative Vasospasm in Unruptured Intracranial Aneurysm

Suk In Lee, M.D., Cheol Wan Park, M.D., Ph.D., Won Jin Hong, M.D., Chan Woo Park, M.D., Ph.D.

Department of Neurosurgery, Gil Medical Center, Gachon Medical School, Incheon, Korea

The cerebral vasospasm after clipping surgery of unruptured aneurysm is uncommon. A 44-year-old man with unruptured left middle cerebral artery(MCA) aneurysm had clipping surgery. From the third postoperative day, he presented with drowsy mentality, dysphasia and right hemiparesis. Computed tomographic scans showed low density area in frontotemporal lobe and midline shift. Transfemoral cerebral angiography revealed severe vasospasm in supraclinoid internal carotid artery, anterior cerebral artery, and MCA on the operative side. We performed left frontotemporoparietal craniectomy and hypertensive-hypervolemic therapy. He recovered without neurological deficits but for dysphasia. Neurosurgeon should be alert to the possibility of vasospasm after clipping surgery even in case of unruptured cerebral aneurysm.

KEY WORDS : Cerebral vasospasm · Unruptured aneurysm.

Introduction

Cerebral vasospasm is frequently associated with high morbidity and mortality rates following subarachnoid hemorrhage(SAH) due to aneurysm rupture. But patients with unruptured aneurysms rarely develop vasospasm after clipping surgery. We experienced a case of severe vasospasm after clipping of unruptured aneurysm, and we report the case with review of the literatures.

Case Report

A 44-year-old man presented with headache and dizziness for 5 months. He was referred with suspicion of unruptured intracranial aneurysms on brain magnetic resonance images(MRI) and angiography(MRA) from private clinic. His MRI and MRA revealed suspicious lesions of cerebral aneurysms at the right posterior communicating artery(PcoA) and left middle cerebral artery(MCA) bifurcation without evidence of hemorrhage. At the time of admission, neurologic examination was normal and medical history was unremarkable except untreated hypertension. His computed tomographic angiography revealed an unruptured left MCA aneurysm and right

PcoA aneurysm(Fig. 1). The authors planned to clip the left MCA aneurysm and to coil the right PcoA aneurysm, respectively. We performed a left pterional craniotomy and clipped the left MCA bifurcation aneurysm.

At operation, there was no evidence of recent or old subarachnoid hemorrhage under surgical microscope. The aneurysmal sac had broad neck which involved the parent arteries, and

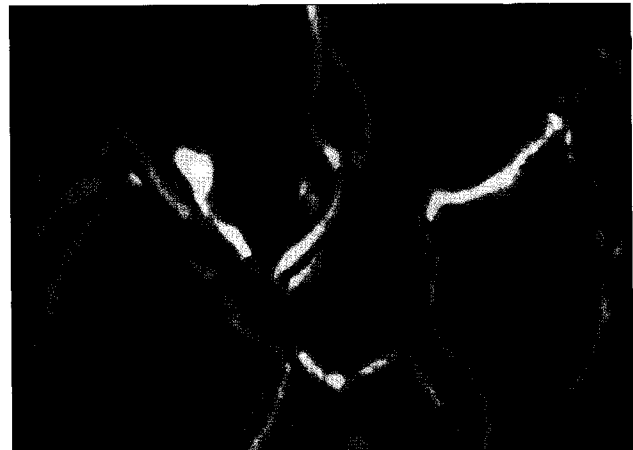

Fig. 1. Computed tomographic angiography demonstrates an unruptured left middle cerebral and right posterior communicating artery aneurysms.

• Received : December 22, 2005 • Accepted : March 17, 2006

• Address for reprints : Cheol Wan Park, M.D., Ph.D., Department of Neurosurgery, Gil Medical Center, Gachon Medical School, 1198 Guwol-dong, Namdong-gu, Incheon 405-220, Korea Tel : +82-32-460-3309, Fax : +82-32-460-3899, E-mail : cwpark@gilhospital.com

had three lobules. The sac was 11mm by 9mm in diameter and was moderately atherosclerotic. We applied a temporary clip across the parent artery (distal M1 of MCA) two times for complete dissection of the neck and dome of the aneurysm. The duration of each temporary clip application were in less than 3 minutes. Seven permanent clips were applied across the neck of aneurysm for ideal obliteration of the aneurysmal sac. The procedure was uneventful without intraoperative rupture except repeated manipulations of parent arteries. After clipping, intraoperative doppler ultrasonography showed good patency of all parent arteries.

Postoperatively, he recovered well without any neurologic

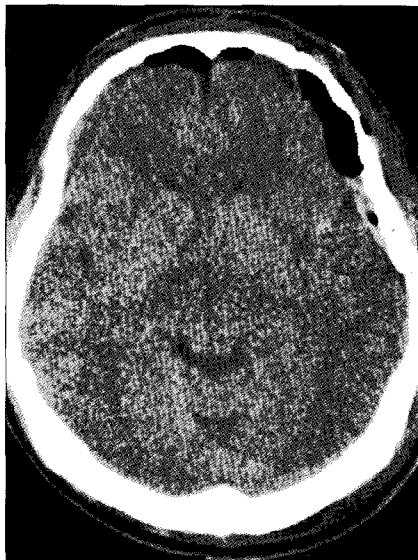

Fig. 2. Postoperative brain computed tomographic scans shows unremarkable findings except small amount of pneumocephalus.

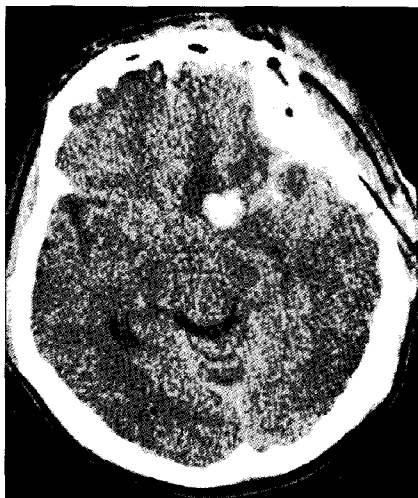

Fig. 3. Brain computed tomographic scans on the third postoperative day demonstrates delayed development of epidural hematoma, small amount of subdural hemorrhage over the distal sylvian fissure and small amount of intracerebral hematoma in frontal lobe.

deficit and his postoperative head computed tomographic scans(CT) showed normal postoperative changes without evidence of hemorrhage except a small amount of pneumocephalus(Fig. 2). He was transferred to general ward after 24 hours period of observation at neurosurgical intensive care unit and he ambulated well.

On the postoperative day three, he developed confusion and on the day four and five, he presented with drowsy mentality, dysphasia and right hemiparesis. We carried out head CT and transfemoral cerebral angiography(TFCA). His head CT revealed intracerebral hematoma on the frontal lobe with surrounding low density area, and

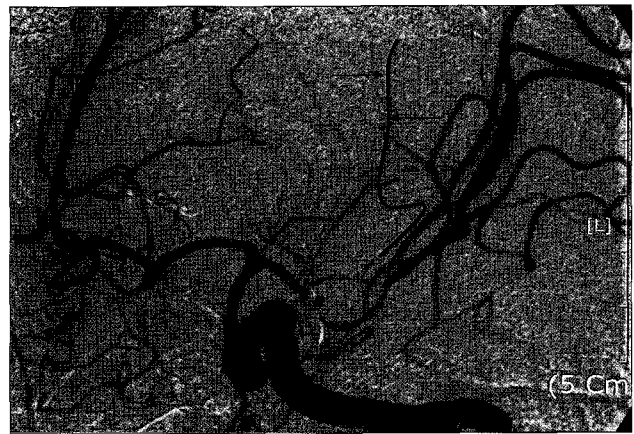


Fig. 4. Transfemoral cerebral angiography reveals vasospasm in supraclinoid internal carotid, anterior cerebral, middle cerebral arteries on operative side. Arrow indicates non-visualization of a branch of left middle cerebral artery due to severe vasospasm.

epidural hematoma(EDH) with tiny amount of subdural hematoma (SDH) on the frontotemporal region(Fig. 3). His TFCA demonstrated successful clipping, but there were severe and diffuse vasospasms in supraclinoid internal carotid artery(ICA), anterior cerebral artery (ACA) and MCA on the operative side (Fig. 4). We

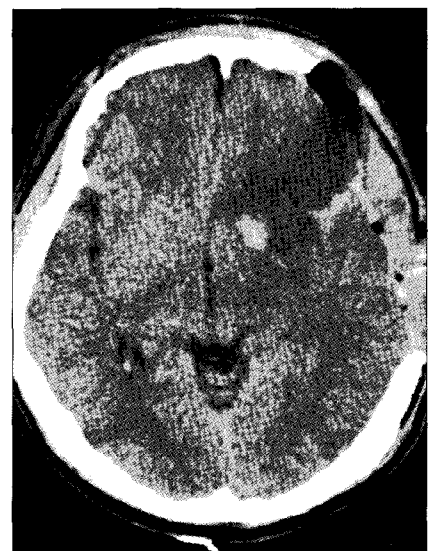


Fig. 5. Postoperative brain computed tomographic scans after second operation shows more extensive and definitive low density area in frontal lobe.

carried out left frontotemporoparietal craniectomy, emergently. After removal of epidural hematoma, the dura was opened. There was very thin subdural blood collection over the distal sylvian fissure, but no hemorrhage around or in the vicinity of clips, ICA and proximal MCA. We also initiated hypervolemic, hypertensive therapy but the second postoperative head CT revealed more wider and definitive low density area in the left frontal lobe (Fig. 5). He gradually recovered and had alert mentality with normal symmetric motor function on the second postoperative day 10, but he has suffered from dysphasia.

Discussion

In general, clinical or angiographic cerebral vasospasm is frequently observed following aneurysmal SAH. But the

precise pathogenesis of vasospasm after SAH is still not understood and is remained to be investigated. It is widely accepted, however, that blood products contribute to vasospasm. Cerebral vasospasm may result from prolonged smooth muscle contraction mediated or triggered by oxyhemoglobin and breakdown products of platelets and erythrocytes in extravasated blood^{6,8}. Thus, the extravasated blood from ruptured aneurysm is responsible for a cascade of reactions involving the release of various vasoactive substances to induce vasospasm^{1,3}. Some of the known spasmogenic substances released in the breakdown processes are serotonin, prostaglandins, catecholamines, histamines, and angiotensin¹¹.

Meanwhile, vasospasm is a rare condition after surgery of an unruptured aneurysm. The known spasmogenic factors are obscure because usual factors that cause vasospasm are not present. A number of theories have been proposed to explain the causative factors, however, no single theory has been fully accepted. In the vasospasm after clipping of unruptured aneurysm, vasospasm may be induced by the mechanical stimulations and chemical agents. The reported mechanical factors of vasospasm are the number of clips used, temporary occlusion of parent arteries, arterial stretch, vascular manipulation¹¹. Chemical factors are intraoperative bleeding, hypothalamic injury, and increased sensitivity to vasoactive substance such as norepinephrine and serotonin^{4,5,7,9,11}.

In the Kitazawa's study³, vasospasm was commonly observed in patients for whom multiple clips were placed on the neck of aneurysm and in patients whose ICA was temporarily occluded. The number of clips used and temporary occlusion of the ICA were statistically significant factors associated with incidence of delayed symptomatic vasospasm after clipping surgery of unruptured paraclinoid aneurysms.

However mechanically induced vasospasm had relatively shorter duration than chemically induced vasospasm in the laboratory study. Raynor and Messer⁷ thought that spasmogenic factor was hypothalamic excitation mediated by pain and stress. They assumed that beta-endorphin, the release of which is mediated by pain or stress, may have the ability to mediate release of neurotransmitters and alter hypothalamic function.

In Wilkins' study¹⁰, he suggested that hypothalamic injury and resulting dysfunction might play a major role in intracranial arterial spasms. Some of the proposed possible pathogenetic mechanisms were that the chemical properties of the subarachnoid blood surrounding the arteries supplying the hypothalamus could cause hypothalamic ischemia, and that operative manipulation of the arteries at the base of the brain could cause vascular spasm and hypothalamic ischemia.

Friedman, Gass and Magidson² reported a case of vasospasm with an unruptured and unoperated aneurysm. They suggested

that vasoconstriction might be mediated by prostaglandins present in cerebrospinal fluid. Prostaglandin endoperoxide and thromboxane A2 have been shown to constrict canine basilar arteries while prostacyclin has been shown to be a physiologic antagonist and to relax cerebral arteries. Damage to the endothelial surface of the artery adjacent to the aneurysm alters its ability to synthesize prostacyclin.

The aneurysm, in our case, had broad atherosclerotic neck and had three lobules. Clips were difficultly applied across the neck of aneurysm with many arterial manipulations. Initially, application of clip blades in parallel direction to the longitudinal axis of the parent artery was attempted, but it was difficult to avoid narrowing of the parent vessels. Finally, we used seven clips in tandem fashion to completely occlude the aneurysm without compromising the parent vessels. We thought that during repeated application of clips, there were some mechanical stimulations to surrounding vessels. Spasmogenic factors of our case might be mechanical manipulations of parent arteries and use of many permanent clips. And other possible causes of vasospasm, less likely, might be associated with temporary clipping on the distal M1 and the delayed development of subdural hemorrhage, although the temporary clipping times were less than 3 minutes in each and the small amount of subdural hematoma was localized over the distal sylvian fissure, far away from the ICA, ACA and MCA.

Conclusion

Early detection, prevention and management of cerebral vasospasm in the treatment of patients after clipping surgery is important, because the vasospasm is associated with high mortality and morbidity. Although cerebral vasospasm after clipping of unruptured aneurysm is a rare condition, if a patient presents with neurological deterioration after clipping, clinician should consider cerebral vasospasm as one of the many causes of deterioration. And during clipping surgery, neurosurgeon should pay attention to minimize mechanical stimulation to the intracranial arteries as well as other neural structures.

• Acknowledgement

Poster presentation at 2005 Annual Meeting of The Korean Neurosurgical Society.

References

1. Dietrich HH, Dacey RG Jr : Molecular keys to the problems of cerebral vasospasm. *Neurosurgery* 46 : 517-530, 2000
2. Friedman P, Gass HH, Magidson M : Vasospasm with an unruptured and unoperated aneurysm. *Surg Neurol* 19 : 21-25, 1983
3. Kitazawa K, Hongo K, Tanaka Y, Oikawa S, Kyoshima K, Kobayashi S : Postoperative vasospasm of unruptured paraclinoid carotid aneurysms; analysis of 30 cases. *J Clin Neurosci* 12 : 150-155, 2005
4. Macdonald RL, Weir BKA : A review of hemoglobin and the pathogenesis of cerebral vasospasm. *Stroke* 22 : 971-982, 1991

5. Mayberg MR, Okada T, Bark DH : Morphologic changes in cerebral arteries after subarachnoid hemorrhage. **Neurosurg Clin N Am** 1 : 417-429, 1990
6. Moon CT : Pathogenesis of Cerebral Vasospasm. **J Korean Neurosurg Soc (Suppl)** 28 : 1208-1214, 1999
7. Raynor RB, Messer HD : Severe vasospasm with an unruptured aneurysms ; case report. **Neurosurgery** 6 : 92-95, 1980
8. Shin YS, Huh SK, Lee KS, Lee KC : Effect of Intrathecal Administration of Nitroglycerine in the Endothelin-1 Induced Rabbit Vasospasm Model. **J Korean Neurosurg Soc** 28 : 1106-1114, 1999
9. Smith RR, Clower BR, Grotendorst GM, Yabuno N, Cruse JM : Arterial wall changes in early human vasospasm. **Neurosurgery** 16 : 171-176, 1985
10. Wilkins RH : Hypothalamic dysfunction and intracranial arterial spasms. **Surg Neurol** 4 : 472-480, 1975
11. Zubkov AY, Lewis AI, Raila FA, Zhang J, Parent AD : Risk factors for the development of post-traumatic cerebral vasospasm. **Surg Neurol** 53 : 126-130, 2000