

Hemorrhagic Complications of Intracranial Arachnoid Cyst Following Minor Head Injury : Report of 5 Cases

Jae Hoon Kim, M.D., Choong Hyun Kim, M.D., Jin Hwan Cheong, M.D.,
Koang Hum Bak, M.D., Jae Min Kim, M.D.

Department of Neurosurgery, School of Medicine, Hanyang University, Guri Hospital, Guri, Korea

Intracranial arachnoid cyst is presumed to be a developmental anomaly and its natural history is not well defined. Often it is detected incidentally in a asymptomatic patient and hemorrhagic events of arachnoid cyst following head injury are rarely reported. We report hemorrhagic complications including two intracystic hemorrhages, two subdural hematomas, and an epidural hematoma in 5 patients with intracranial arachnoid cyst after minor head injury and review pertinent literatures.

KEY WORDS : Arachnoid cyst · Head injury · Hemorrhage.

Introduction

Arachnoid cysts are benign cysts that occur in relation to the arachnoid membrane. They are rarely developed and account for about 1% of all non-traumatic intracranial mass lesions^{11,12}. However, the detection rate of arachnoid cysts has increased recently by virtue of the use of computed tomographic(CT) scans or magnetic resonance imaging(MRI) scans. Although most patients with arachnoid cyst are asymptomatic and the annual risk of hemorrhage is reported to be less than 0.1%, the presence of intracranial arachnoid cyst increase the risk of intracranial hemorrhage including intracystic hemorrhage, epidural hemorrhage, and subdural hemorrhage after minor head injury⁹.

We present five cases with intracranial arachnoid cyst complicated by hemorrhage after minor head injury.

Case Report

Case 1

A 30-year-old man presented with generalized tonic clonic seizure which lasted for three minutes. He had a history of a traffic accident two weeks ago before admission. On neurological examination, there were no abnormalities. Brain MRI scans revealed a large cystic mass lesion of low signal

intensity on T1-weighted(T1W) image and high signal intensity on T2-weighted (T2-W) image with subdural effusion in the left temporal region approximately 5×8cm in size (Galassi Type III) (Fig. 1). Subdural effusion was drained by trephination and later, a cystoperitoneal shunt was performed. The patient recovered uneventfully.

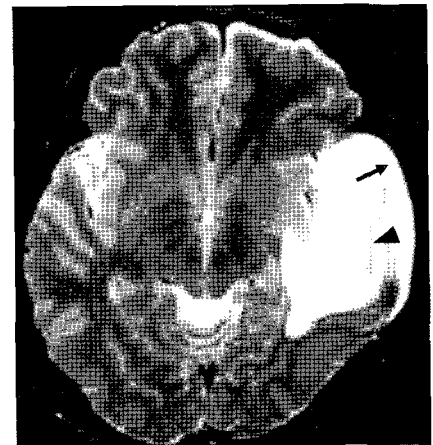


Fig. 1. Axial magnetic resonance(MR) image showing an arachnoid cyst in the left middle cranial fossa, which is hyperintense on the T2-weighted image. Note the crescent mass (arrow) bordered by linear membrane (arrowhead).

Case 2

A 9-year-old boy presented with severe headache and dizziness after a pedestrian accident. On neurological examination, he was drowsy. Brain CT scan revealed an arachnoid cyst with intracystic hemorrhage in the right temporal region, 3×4cm in size (Galassi Type I) (Fig. 2).

• Received : August 12, 2005 • Accepted : December 22, 2005

• Address for reprints : Choong Hyun Kim, M.D., Department of Neurosurgery, School of Medicine, Hanyang University, Guri Hospital, 249-1 Gyomun-dong, Guri 471-701, Korea Tel : +82-31-560-2322, Fax : +82-31-560-2322, E-mail : kch5142@hanyang.ac.kr

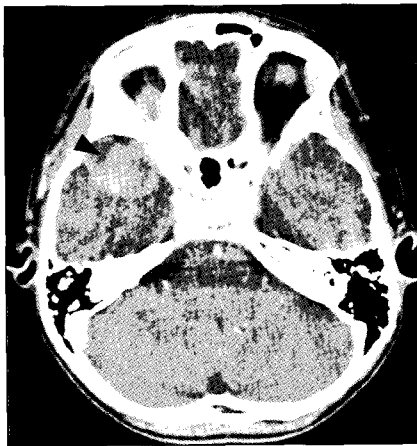


Fig. 2. Axial computed tomography(CT) scans showing an arachnoid cyst in the right temporal region and intracystic hemorrhage (arrowhead).

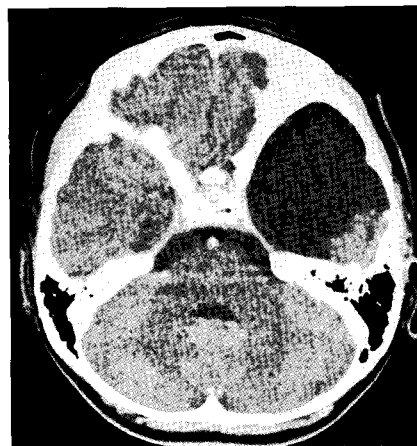


Fig. 3. Contrast enhanced axial CT scan demonstrating a hypodense arachnoid cyst in the left temporal region.

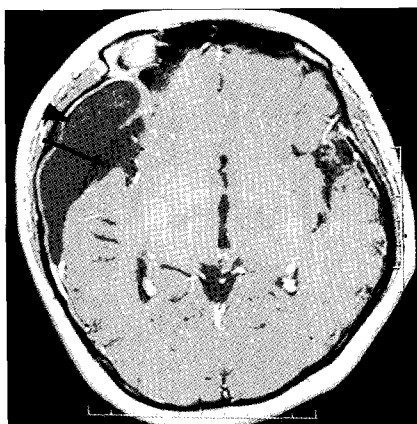


Fig. 4. Gadolinium enhanced axial MR image demonstrating hypointense arachnoid cyst (arrow) with crescent mass (arrowhead).

an arachnoid cyst with chronic subdural hematoma in the right frontotemporoparietal region, 5 × 7cm in size (Galassi Type II) (Fig. 4). The patient underwent trephination with drain-

The patient underwent trephination and discharged with good recovery.

Case 3

A 9-year-old girl presented with intermittent headache. She had a history of a traffic accident one week ago prior to admission. Neurological examination was unremarkable. Brain CT scan revealed an arachnoid cyst with an intracystic hemorrhage in the left temporoparietal region, 6 × 8cm in size (Galassi Type II) (Fig. 3). The patient underwent cystoperitoneal shunt and discharged without any complications.

Case 4

A 24-year-old woman presented with persistent headache. She had a history of head injury caused by slipping two weeks ago before admission. On neurological examination, she showed no abnormality. Brain CT and MRI scan revealed

an arachnoid cyst with an intracystic hemorrhage in the right frontotemporoparietal region, 5 × 7cm in size (Galassi Type II) (Fig. 4). The patient underwent trephination with drain-

Case 5

A 12-year-old boy presented with headache after a bicycle accident. He was lethargic and there was no other abnormalities on neurological examination. Brain CT and MRI scan revealed an arachnoid cyst with epidural hematoma in the right frontotemporal region, 3 × 4cm in size (Galassi Type II) (Fig. 5). He was managed conservatively and made an uneventful recovery.

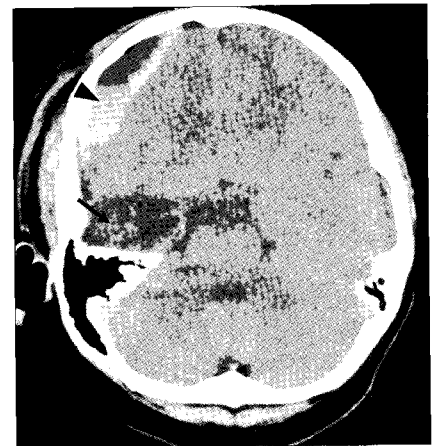


Fig. 5. Axial CT scan showing an arachnoid cyst in the right temporal region (arrow) with epidural hematoma in the right frontal region (arrowhead).

Discussion

Arachnoid cysts are congenital collections of cerebrospinal fluid occurring between arachnoid layers and develop anywhere within the intracranial cavity, mainly distributed along the arachnoid cistern¹¹. Di Rocco et al.³ reported that distribution of arachnoid cysts was 34% in the sylvian fissure, 17.5% in the cerebellopontine angle, 15% in the parasellar, 15% in the cerebral convexity, 8% in the interhemispheric fissure, 5% in the vermian, 5% in the quadrigeminal plate, and 0.5% in the retroclival region. An analysis of the distribution of arachnoid cysts in intracranial cavity leads to the conclusion that supratentorial location is predominant compared with infratentorial cysts¹¹. Also Galassi et al. classified sylvian fissure cyst into three subgroup based on the CT scan appearance⁴.

Most arachnoid cysts that become symptomatic do so in early childhood⁹. The presentation varies according to the location of the cysts. Typical presentation include symptoms of intracranial hypertension, seizures, sudden neurological deterioration, and focal neurological signs and symptoms of a space occupying lesion.

The natural history of arachnoid cysts is still not clear. Often they are detected incidentally in asymptomatic individuals evaluated for unrelated symptoms, and they may remain either quiescent and asymptomatic, or in a minority of cases, they may enlarge progressively and exert mass effect. The annual risk of hemorrhage within or around these cysts is reported to be less than 0.1%, mainly in the middle cranial fossa⁹.

Occasionally, arachnoid cysts may become symptomatic after minor head injury and are presented with cystic hemorrhage, subdural hematoma, and rarely epidural hematoma¹⁰.

The pathogenesis of hemorrhagic complication was not fully understood, but various reports suggest how arachnoid cyst develop into hemorrhagic complications. Tearing of the outer wall of the arachnoid cyst is associated with subdural and/or intracystic hemorrhage caused by rupture of bridging veins, unsupported vessels around the cyst wall, and leptomeningeal vessels in the base of the cyst⁷. Some authors⁶ reported intracystic hemorrhage after rupture of a saccular aneurysm. The extradural hematoma is rarely complicated and reported. Molloy et al.⁸ reported a presumptive theory that the development of extradural hematoma has been attributed to easier dural detachment, alteration in intracranial pressure and diminished cerebral compliance. Some authors¹¹ reported spontaneous disappearance of intradural arachnoid cysts following hemorrhage, presumably due to occlusion of the intradural communication by the organizing hematoma.

There is a controversy regarding the optimal management of arachnoid cysts. Some authors⁵ advocate management of all cysts, given their potential for unpredictable nature. Others¹² would adopt a conservative treatment because no evidence exists to suggest that operative treatment prevents bleeding. However, there is a general agreement that symptomatic arachnoid cysts, especially complicating with hemorrhage require operative treatment including craniotomy with cyst wall excision, fenestration or aspiration of cyst, and cystoperitoneal shunt^{2,13}. In our series, four cases were treated surgically, cystoperitoneal shunt in two cases, and trephination in another two cases without any complications. The authors advocate that symptomatic arachnoid cysts should be treated by surgical intervention and if asymptomatic, conservative treatment with serial imaging study warrant good outcome.

Conclusion

The hemorrhagic complication of arachnoid cyst rarely occurs after minor head injury. However if it is symptomatic, it requires a surgical procedure and the outcome is usually excellent. Therefore, we should be alert to the possibility of hemorrhagic complications of the intracranial arachnoid cysts after minor head injury.

References

1. Beltramello A, Mazza C : Spontaneous disappearance of a large middle fossa arachnoid cyst. *Surg Neurol* 24 : 181-183, 1985
2. Choi HC, Jeun SS, Lee KS, Kim MC, Kang JK : Surgical treatment of middle cranial fossa arachnoid cyst by wide excision and fenestration. *J Korean Neurosurg Soc* 33 : 56-61, 2003
3. Di Rocco C, Caldarelli M, Ceddia A : *Intracranial Cyst Lesions*. New York, Springer-Verlag, 1993, pp101-111
4. Galassi E, Gaist G, Giuliani G, Pozzati E : Arachnoid cysts of the middle cranial fossa : experience with 77 cases treated surgically. *Acta Neurochir Suppl (Wien)* 42 : 201-204, 1988
5. Go KG, Houthoff HJ, Blaauw EH, Havinga P, Harsuiker J : Arachnoid cyst of the sylvian fissure : evidence of fluid secretion. *J Neurosurg* 60 : 803-813, 1984
6. Hirose S, Shimada S, Yamaguchi N, Hosotani K, Kawano H, Kubota T : Ruptured aneurysm associated with arachnoid cyst : intracystic hematoma without subarachnoid hemorrhage. *Surg Neurol* 43 : 353-356, 1995
7. Ide C, De Coene B, Gillianrd C, Pollo C, Hoebeke M, Gofraind C, et al : Hemorrhagic arachnoid cyst with third nerve paresis : CT and MR findings. *Am J Neuroradiol* 18 : 1407-1410, 1997
8. Molloy CJ, Jones NR, North JB : Arachnoid cyst presenting as an extradural hematoma. *Br J Neurosurg* 5 : 635-637, 1991
9. Parsch CS, Krau J, Hofmann E, Meixensberger J, Roosen K : Arachnoid cysts associated with subdural hematomas and hygromas : analysis of 16 cases, long-term follow-up, and review of the literature. *Neurosurgery* 40 : 483-490, 1997
10. Prabhu VC, Bailes JE : Chronic subdural hematoma complicating arachnoid cyst secondary to soccer-related head injury : case report. *Neurosurgery* 50 : 195-197, 2002
11. Robert HW, Setti SR : *Neurosurgery*, ed 2. McGraw-Hill, 1996, pp 3709-3731
12. Robinson RG : Congenital cyst of brain : arachnoid malformations. *Prog Neurol Surg* 4 : 133-174, 1971
13. Tsuboi Y, Hamada H, Hayashi N, Kuimoto M, Hirashima Y, Endo S : Huge arachnoid cyst in the posterior fossa : controversial discussion for selection of the surgical approach. *Childs Nerv Syst* 21 : 259-261, 2005

Commentary

The authors presented five cases of middle cranial fossa arachnoid cyst(AC) complicated with hemorrhage and/or effusion after 'minor head injury', and emphasized the need of high index of suspicion of complicated AC in case of 'soft' symptoms (localized headache, dizziness, behavior problems, ataxia etc.) preceded by minor head trauma.

The cases of 'minor head injury' included traffic accident in two cases, and pedestrian accident, bicycle accident, and slip-down in one case each. There are increasing number of reports in hemorrhagic complication of previously asymptomatic AC caused by heading a soccer ball during soccer game.

In the management of the complicated AC, authors performed relatively noninvasive procedure e.g. trephination, to evacuate the hematoma. Many neurosurgeons have performed large craniotomy and outer membranectomy with medical cyst wall fenestration into the basal cistern, but I think the author's procedure has rationale of practice because of most complicated middle fossa AC patient were asymptomatic before the minor head injury. So it is unnecessary to treat the asymptomatic AC in case of complicated AC. Just evacuation of the subdural or intracystic hematoma with small craniotomy or burr hole as an initial procedure without cyst surgery suffice to control most of the complicated AC.

If preoperative symptoms persist after the simple procedure the next options such as direct cyst fenestration or cystoperitoneal shunt can be added.

But I would add one recently developed neuroendoscopic procedure for the management of symptomatic persistent AC.

Recently endoscopic fenestration of the middle cyst wall into the basal cistern or into the lateral ventricle proved to be very effective in communication of the cyst treatment of choice in symptomatic middle fossa AC.

Cystoperitoneal shunt has all the complications of shunt

system, e.g. obstruction, infection, migration, overdrainage syndrome, shunt dependency, slit-cyst syndrome, so it should be avoided if circumstances allow.

Byung-Kyu Cho, M.D.
Department of Neurosurgery,
Seoul National University