

Role of Three-dimensional Computed Tomography Angiography in the Follow-up of Patients with Aneurysm Clips

Seong-Hyun Park, M.D., Jae Chan Park, M.D., Jeong-Hyun Hwang, M.D.,
Sung-Kyoo Hwang, M.D., In-Suk Hamm, M.D.

Department of Neurosurgery, Kyungpook National University Hospital, Daegu, Korea

Objective : The purpose of this study is to assess the usefulness of three-dimensional computed tomography angiography (3D-CTA) as a postoperative follow-up examination after intracranial aneurysms have been clipped.

Methods : Between January 2002 and June 2005, 522 consecutive patients received treatment for intracranial aneurysms. A retrospective analysis of 310 patients with postoperative 3D-CTAs was performed to evaluate aneurysmal remnants and de novo aneurysms. This study was conducted in 271 patients with at least immediate and 6-month routine 3D-CTAs for postoperative clipped aneurysm and 39 patients with 3D-CTAs for clipped aneurysm before 2002 when there was no 3D-CTA in our hospital.

Results : Eight patients had abnormal CT angiographic findings. Aneurysm remnants were revealed in 4 patients and de novo aneurysms were discovered in 5 patients. Two patients were found at the postoperative 6-month 3D-CTA performed routinely. In 1 patient, the aneurysm was demonstrated on the way to the examination of syncope. In 2 patients, the author recommended 3D-CTA although there was no symptom because the patients had visited our institute long time ago (5.1, 4.5 years). Of the 8 patients, 2 remnants and 1 de novo aneurysm were treated by endovascular treatment. Three de novo aneurysms at the middle cerebral artery and 1 pericallosal artery aneurysm were treated by direct clipping because these aneurysms were not suitable for the endovascular treatment in point of anatomical configuration. One patient with both remnant and de novo aneurysm was treated conservatively.

Conclusion : 3D-CTA is an available, non-invasive diagnostic tool for the postoperative follow-up examination of aneurysmal state in patients after clipping.

KEY WORDS : 3D-CTA · Intracranial aneurysm · Aneurysm remnant · De novo aneurysm.

Introduction

Most intracranial aneurysms are treated perfectly and permanently. However, aneurysms treated with clip placement may rupture or regrow. Even when surgeons are competent and have extensive experience with aneurysm surgery, there are sometimes surprising findings of incomplete occlusion of the aneurysm, unplanned vessel occlusion, or de novo aneurysms. Postoperative angiography can solve these problems and possibly prevent their sequelae but has its own risks⁷⁾. Therefore, not all centers perform routine postoperative angiography on all patients¹⁸⁾. A noninvasive, available modality to screen patients after clipping may solve this problem. Recently, three-dimensional computed tomography angiography(3D-

CTA) has proved valuable in pre- and postoperative evaluation of intracranial aneurysm, although cerebral digital subtraction angiography(DSA) remains the standard of reference^{2,5,11)}.

In this study, the authors suggest that 3D-CTA in patients who underwent aneurysm surgery is a useful method to evaluate the clipped aneurysm and identify de novo aneurysm.

Materials and Methods

We retrospectively evaluated the hospital records of all patients admitted to our hospital who underwent treatment for intracranial aneurysms between January 2002 and June 2005. During 3.5 years, 522 consecutive patients received treatment for intracranial aneurysms. A retrospective

• Received : November 28, 2005 • Accepted : February 20, 2006

• Address for reprints : Seong-Hyun Park, M.D., Department of Neurosurgery, Kyungpook National University Hospital, 50 Samdeok 2-ga, Jung-gu, Daegu 700-721, Korea Tel : +82-53-420-5647, Fax : +82-53-423-0504, E-mail : nsdoctor@naver.com

analysis of 310 patients with postoperative 3D-CTAs was performed to evaluate aneurysmal remnants and de novo aneurysms. Postoperative 3D-CTAs were performed to identify the clipped state of the intracranial aneurysm at least immediately and 6-month routinely after aneurysm clipping and additionally, when neurosurgeon wanted to evaluate clipped aneurysm instead of DSA. This study was conducted in 271 patients with at least immediate and 6-month routine 3D-CTAs for postoperative clipped aneurysm and 39 patients with 3D-CTAs for clipped aneurysm before 2002 when there was no 3D-CTA in our hospital. During the same period 212 other patients received treatment, but did not undergo postoperative 3D-CTA. The reason for not having the examination was : a lack of information and understanding about 3D-CTA in the beginning period and needs of DSA in case of rebleeding, postembolization state, and inevitable residual neck. Of course these 212 patients have not been included in the series studied here.

All structures except for bones and arteries adjacent to the aneurysms were removed by a manual cutaway technique. In all cases, it was necessary to meticulously study the obtained images with mutiplanar viewing and different rotations before conclusion could be drawn. Comparison with preoperative DSA and postoperative 3D-CTA was performed to find aneurysm remnant and de novo aneurysm by an experienced neuroradiologist and neurosurgeons. Aneurysm remnant was defined as a residual bulge on the clipping simulation images. 16-channel multidetector computed tomography angiography(MDCTA) has been used for postoperative 3D-CTA in our hospital since 2002. One of the advantages of MDCTA over single-detector CT is its use of "thinner beam collimation", by which the metallic artifact caused by surgical clips can theoretically be reduced. Postoperative DSA had to be performed when 3D-CTA images were not normal or when the neck of the aneurysm cannot be evaluated due to the clip artifact.

Results

Occlusion of the dome and the sac of the aneurysm could be confirmed in all 3D-CTAs. Eight patients (6 female and 2 male) had postoperative CT angiographic abnormality among 310 patients who underwent aneurysm clipping and were evaluated with postoperative 3D-CTA after clipping of aneurysms. Their age ranged from 36 to 61 years, with a mean age of 50.1 years (Table 1).

In all 8 patients, abnormal findings of 3D-CTAs were checked at the out-patient clinics. Three patients were diagnosed by 3D-CTA to investigate the cause of mild headaches. Two patients were found at the postoperative 6-month 3D-CTA performed routinely. In 1 patient, the aneurysm was demonstrated on the way to the examination of syncope. In 2 patients, the author recommended 3D-CTA although there was no

Table 1. Clinical features of 8 patients with remnants and de novo aneurysms detected with follow-up three-dimensional computed tomography angiography

Case	Sex / Age (years)	Aneurysm Original Site	Interval (years)	Presentation	Remnant	De Novo	Treatment
1	M/61	ACOM	4.5	Long term F/U	ACOM	no	GDC
2	M/61	MCA	9.5	Syncope	no	ACOM	GDC
3	F/44	PCOM	5.3	Headache	no	MCA	Clipping
4	F/36	PCOM	0.5	Routine F/U	PCOM	no	GDC
5	F/52	PCOM	5.1	Long term F/U	no	MCA	Clipping
6	F/43	ACOM	10.0	Headache	no	MCA	Clipping
7	F/51	PCOM	2.0	Headache	PCOM	Oph	Observation
8	F/53	Pericallosal	0.5	Routine F/U	Pericallosal	no	Clipping

*M= male ; F=female; ACOM=anterior communicating artery; MCA=middle cerebral artery; PCOM=posterior communicating artery; Oph=ophthalmic artery; F/U=follow up; GDC=Guglielmi detachable coiling

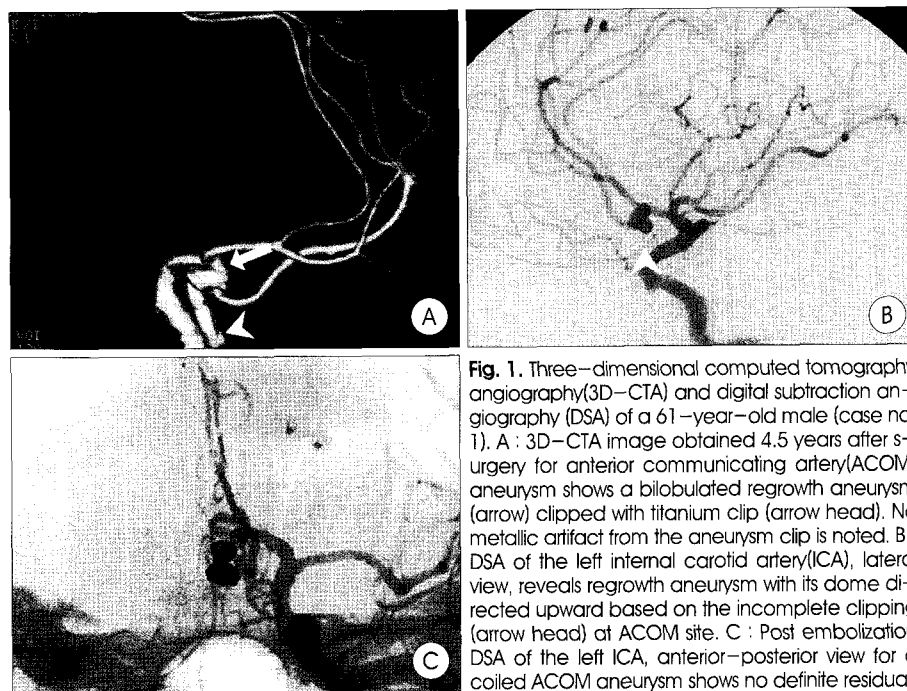


Fig. 1. Three-dimensional computed tomography angiography(3D-CTA) and digital subtraction angiography (DSA) of a 61-year-old male (case no. 1). A : 3D-CTA image obtained 4.5 years after surgery for anterior communicating artery(ACOM) aneurysm shows a bilobulated regrowth aneurysm (arrow) clipped with titanium clip (arrow head). No metallic artifact from the aneurysm clip is noted. B : DSA of the left internal carotid artery(ICA), lateral view, reveals regrowth aneurysm with its dome directed upward based on the incomplete clipping (arrow head) at ACOM site. C : Post embolization DSA of the left ICA, anterior-posterior view for a coiled ACOM aneurysm shows no definite residual.

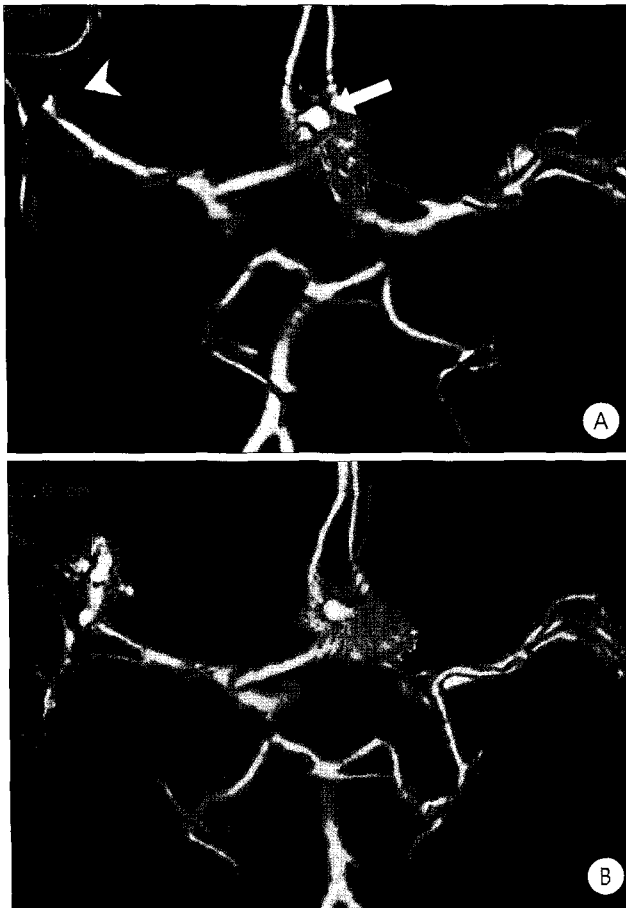


Fig. 2. Three-dimensional computed tomography angiography (3D-CTA) and digital subtraction angiography (DSA) of a 43-year-old female (case no. 6). A: 3D-CTA image obtained 10 years after surgery for anterior communicating artery (ACOM) aneurysm with stainless clip (arrow) shows perfect clipping for ACOM aneurysm and de novo aneurysm of the middle cerebral artery (MCA) (arrow head). B: DSA of the left ICA, anterior view, reveals a de novo aneurysm (arrow head) with its dome directed upward at MCA site. C: Postoperative 3D-CTA image reveals no rest of the aneurysm after clipping for MCA and ACOM aneurysms. The stainless clip applied 10 years ago for ACOM aneurysm has severe artifact around clipped aneurysm compared to that of titanium clip 1 year ago for MCA aneurysm.

symptom because the patients had visited our institute several years ago.

The distribution of the de novo aneurysms diagnosed in 5 patients was as follows: middle cerebral artery aneurysm in 3 cases, anterior communicating artery (ACOM) aneurysm in 1 case, and ophthalmic artery aneurysm in 1 case. Four regrowth or remnant aneurysms were identified by 3D-CTA. Two patients had posterior communicating artery (PCOM) aneurysms, 1 patient had pericallosal artery aneurysm, and 1 case had ACOM. One of 2 patients with regrowth aneurysms at the PCOM had a de novo aneurysm at the ophthalmic artery as well.

Among 8 patients with abnormal CTA findings, 2 remnants (case 1 and 4) and 1 de novo aneurysm (case 2) were treated by endovascular treatment (Fig. 1). Three de novo aneurysms at the middle cerebral artery (case 3, 5, and 6) and 1 pericallosal

artery aneurysm (case 8) were treated by direct clipping because these aneurysms were not suitable for the endovascular treatment in point of anatomical configuration (Fig. 2). One patient with both remnant and de novo aneurysm was treated conservatively because we thought that remnant neck of aneurysm and de novo aneurysm were small and in an unruptured benign state. The aneurysm remnant has been decided to be followed up the evolution of the remnant of the neck of the aneurysm. There was no interval change on 3D-CTA at the follow-up study performed 1.5-year postoperatively.

After diagnosing remnant or de novo aneurysms by 3D-CTA, we immediately performed DSA to get precise information about intracranial circulation. All 8 patients had good outcomes (according to the Glasgow outcome scale). There were no complications associated with the performance of 3D-CTA.

Discussion

The incidence and long-term outcome of aneurysm remnants after clipping are now of the greatest concern. The reported incidence of a remnant aneurysm in patients after surgical clipping of an intracranial aneurysm ranged from 3.8% to 8%^{6,8,16}. The risk of hemorrhage from aneurysm remnant has been estimated at approximately 0.5% to 1.9% per year⁴. Aneurysm regrowth from a residual neck is clinically significant in that a potentially fatal SAH may subsequently occur. In addition, reoperation for aneurysm remnants presents technical difficulties. The only way to be completely sure that no aneurysm remnant exists is to confirm that fact on postoperative DSA. Cerebral angiography performed after aneurysm surgery can identify potential causes of morbidity and mortality, such as an aneurysm remnant or vessel occlusion. Macdonald et al. reported an 8% incidence of unexpected residual and unclipped aneurysms on postoperative DSA in a series of 67 consecutive patients with 78 aneurysms¹².

Routine postoperative DSA, however, adds risk and financial burden to the majority of patients whose aneurysms prove to be adequately obliterated. To solve the problem of postoperative confirmation for aneurysms, 3D-CTA and magnetic resonance angiography (MRA) have been used to evaluate intracranial circulation^{2,5,11}. Whether the risk of DSA and the value of noninvasive methods including 3D-CTA or MRA in the follow-up studies are acceptable may still be controversial. Cloft et al. reported the risk of DSA was 0.07%, which seems to justify DSA as an acceptable examination in the detection of de novo aneurysms or regrowth of original aneurysms³. Because DSA has its own risks, Kassell proposed a standard of practice in which postoperative DSA should be limited to: (1) all patients with new unexplained postoperative neurological deficits, (2) all patients in whom difficulty is

encountered at the time of surgery⁸). Therefore, many neurosurgeons are provided safely with more useful information after an aneurysm was clipped through advanced noninvasive 3D-CTA and MRA.

Both 3D-CTA and MRA provided important information after an aneurysm was clipped, consistent with the information derived from DSA. The main advantage of MRA compared with CTA is that the bone does not disturb the images. As well, an interesting application for MRA is the follow-up investigation of patients who have been treated with platinum coils¹³). Recently, it was also shown that the artifacts caused by titanium clips in MRA were smaller than those caused by clips made of other alloys¹¹). However, the artifacts caused by titanium clips still made the evaluation of the occlusion of the dome and the neck of the aneurysm impossible in MRA. In our opinion, MRA is not a good modality for evaluation of the surgical clipping site in patients after surgical clipping of intracranial aneurysms because the image quality of MRA is severely degraded by the paramagnetic artifact of the clip. The CTA images from 16-channel MDCTA were not severely degraded by the presence of nearby aneurysm clips because of their thin beam collimation (0.625mm). With the increase in the number of detectors, MDCTA scanners provides thinner slice thickness and higher temporal resolution, which may lead to fewer metallic artifacts from aneurysm clips. MRA may be an another option if the aneurysm clip is MR-compatible, however, documentation of compatibility is problematic, as untoward outcomes are possible even with close scrutiny. Klucznik et al. reported the death of a patient during MR imaging to verify clip placement, despite careful attempts to document the type of clip that had been placed¹⁰). Therefore, it is recommended that patients with aneurysm clips should be avoided MR imaging if at all possible.

3D-CTA seems to be a much more valuable tool for non-invasive evaluation of the presence of a residual sac during the immediate postoperative period and for long-term follow-up of patients after clip placement. Postoperative 3D-CTA has also several advantages compared to DSA : (1) scanning time is short compared with DSA, (2) 3D images rotated through 360 degrees provide a better view of the anatomy of the aneurysm and the surrounding vessels, and (3) the risk of stroke with DSA can be avoided. A major limitation of postoperative 3D-CTA has been the significant array of artifacts produced by clips that have been used for treatment of cerebral aneurysms. With the postoperative patient, metal artifacts can severely degrade image quality even though modern technique such as MDCTA might lessen image degradation. Tsutsumi et al. suggested that 3D-CTA was less likely to be eligible in patients with an aneurysm clip, so de novo aneurysms located distant from the clip should be able to be monitored with this less-

invasive methods, as well as untreated aneurysm and wrapped aneurysm¹⁷). To overcome this problem in postoperative patients, titanium clips have been developed (Fig. 2). Several studies have demonstrated that titanium clips have significantly fewer artifacts on CTA¹⁵). Kato et al. reported that titanium clips produced only limited artifacts and yielded improved images in patients who had undergone aneurysm clipping⁹). On the other hand, depending on the location of the aneurysm, the artifact obscures important anatomy. Of all arterial segments, the A1 segment in patients with a clipped ACOM aneurysm is the most difficult to evaluate because of the close anatomical relationship between the aneurysm, the afferent and efferent vessels, and the clips. Therefore, it can be an important key to carefully inspect the source images prior to 3D visualization to check for the occurrence of artifacts around the clip. The artifact from aneurysm clip on CTA can be decreased further by certain maneuvers during scanning of the patients. Brown et al. described a head tilt technique for use with CTA that reduced beam-hardening artifacts in patients with aneurysm clips¹¹). This technique directed the artifacts away from pertinent anatomy, thus increasing the chance of diagnostic accuracy.

An additional benefit of postoperative 3D-CTA is that we have detected de novo aneurysms that were not visualized on the preoperative films. Rauzzino et al. emphasized the need for high quality preoperative angiography to prevent missing aneurysms¹⁴). In our study, de novo aneurysms were carefully examined by comparing the additional DSA following 3D-CTA with the previous DSA obtained before clipping to confirm diagnosis of doubtful de novo aneurysm.

In these days, 3D-CTA is not yet permitted as a part of the routine postoperative regimen for several reasons in other institute. The technique still does not provide information equivalent to that provided by DSA, and 3D-CTA requires relatively large amount of contrast medium. Furthermore, the contrast bolus used in the study increases the risk of performing DSA immediately in a patient with a questionable finding on 3D-CTA. Despite of these disadvantages, the use of postoperative 3D-CTA as a first screening method to avoid the unnecessary use of DSA would be still of high value and would help control the clipped aneurysms postoperatively. If 3D-CTA depicts a probable or definite residual sac, DSA should be performed. However, if the postoperative 3D-CTA images are not degraded by beam-hardening artifact and show no residual sac of an aneurysm, the DSA can be omitted. In our study, the authors suggest that after an aneurysm has been clipped postoperative 3D-CTA provides lots of valuable information concerning the clipped aneurysm and other major vessels therefore, postoperative 3D-CTA promises to become a part of the postoperative routine examination after an aneurysm has been clipped.

Conclusion

3D-CTA is a promising, safe diagnostic modality for postoperative examination of clipped aneurysm and assessment of de novo aneurysm after clipping. We suggest that 3D-CTA can be routinely performed instead of postoperative DSA for patients who have undergone aneurysm surgery.

References

1. Brown JH, Lustrin ES, Lev MH, Ogilvy CS, Taveras JM : Reduction of aneurysm clip artifacts on CT angiograms : a technical note. *AJNR Am J Neuroradiol* 20 : 694-696, 1999
2. Cho CH, Kim JK, Yoo DS, Cho KS, Kim DS, Huh PW : Usefulness of angiographic three-dimensional reconstruction of spiral computed tomography images for postoperative evaluation after aneurysm clipping with Titanium clips. *J Korean Neurosurg Soc* 34 : 299-302, 2003
3. Cloft HJ, Joseph GJ, Dion JE : Risk of cerebral angiography in patients with subarachnoid hemorrhage, cerebral aneurysm, and arteriovenous malformation. *Stroke* 30 : 317-320, 1999
4. David CA, Vishteh AG, Spetzler RF, Lemole M, Lawton MT, Partovi S : Late angiographic follow-up review of surgically treated aneurysms. *J Neurosurg* 91 : 396-401, 1999
5. Dorsch NW, Young N, Kingston RJ, Compton JS : Early experience with spiral CT in the diagnosis of intracranial aneurysms. *Neurosurgery* 36 : 230-238, 1995
6. Feuerberg I, Lindquist C, Lindqvist M, Steiner L : Natural history of postoperative aneurysm rests. *J Neurosurg* 66 : 30-34, 1987
7. Hanley GY, Warlow CP, Sellar RJ : Cerebral angiographic risks in mild cerebral vascular disease. *Stroke* 21 : 209-222, 1990
8. Kassell NF : Angiography after aneurysm surgery (Letter to ed). *J Neurosurg* 80 : 953-954, 1994
9. Kato Y, Sano H, Katada K, Ogura Y, Ninomiya T, Okuma I, et al : Effects of new titanium cerebral aneurysm clips on MRI and CT images. *Minim Invasive Neurosurg* 39 : 82-85, 1996
10. Klucznik RP, Carrier DA, Pyka R, Haid RW : Placement of a ferromagnetic intracerebral aneurysm clip in a magnetic field with a fatal outcome. *Radiology* 187 : 855-856, 1993
11. Lawton MT, Heiserman JE, Prendergast VC, Zabramski JM, Spetzler RF : Titanium aneurysm clips : part III : clinical application in 16 patients with subarachnoid hemorrhage. *Neurosurgery* 38 : 1170-1175, 1996
12. Macdonald RL, Wallace C, Kestle JRW : Role of angiography following aneurysm surgery. *J Neurosurg* 79 : 826-832, 1993
13. Nome T, Bakke SJ, Nakstad PH : MR angiography in the follow-up of coiled cerebral aneurysms after treatment with Guglielmi detachable coils. *Acta Radiol* 43 : 10-14, 2002
14. Rauzzino MJ, Quinn CM, Fisher WS III : Angiography after aneurysm surgery : indications for selective angiography. *Surg Neurol* 49 : 32-41, 1998
15. Silverman PM, Spicer LD, McKinney R Jr, Feldman DB : Computed tomographic evaluation of surgical clip artifact : tissue phantom and experimental animal assessment. *Comput Radiol* 10 : 37-40, 1986
16. Sindou M, Acevedo JC, Turjman F : Aneurysmal remnants after microsurgical clipping : classification and results from a prospective angiographic study (in a consecutive series of 305 operated intracranial aneurysms). *Acta Neurochir (Wien)* 140 : 1153-1159, 1998
17. Tsutsumi K, Keisuke U, Akio M, Masaaki U, Takaaki K : Risk of aneurysm recurrence in patients with clipped cerebral aneurysms : results of long-term follow up angiography. *Stroke* 32 : 1191-1194, 2001
18. Wolpert SM, Caplan LR : Current role of cerebral angiography in the

diagnosis of cerebrovascular disease. *AJR Am J Roentgenol* 159 : 191-197, 1992

Commentary

The authors reviewed the patients of clipped aneurysm with postoperative three-dimensional computed tomography angiography(3D-CTA) and evaluate the usefulness of 3D-CTA as postoperative method. This study was performed through 310 patients with postoperative 3D CTA during 3.5 years, and result shows 8 patients of aneurysmal remnants and de novo aneurysms.

Three-dimensional computed tomography angiography (3D-CTA) is usually a valuable method for noninvasive preoperative evaluation of aneurysms. But, the postoperative role of 3D-CTA is not clear. "Operation" means not only clipping of aneurysm and also includes endovascular embolization of aneurysm. In this way, result of this study will give a valuable meaning for follow up of operation.

As authors mentioned in a discussion, comparing of conventional digital subtraction angiography(DSA), 3D CTA has short scanning time, 360 degree rotating better view and reducing risk of stroke. But, major limitation as a follow up method is artifacts produced by clip and coil. Even if there were many methods to overcome this problem, close anatomical relationship of small vessel and small aneurysms (especially, anterior communicating artery aneurysm) cannot be clearly elucidated. If there are some doubts of abnormality in 3D-CTA, conventional digital subtraction angiography(DSA) must be followed to confirm abnormality. And, other problems in the postoperative role of 3D-CTA are relatively high false positive and negative detection rate of aneurysms and vague vessel anatomy imaging adjacent bone structure (for example, proximal internal cerebral arteries). Therefore, in spite of good results from this study, the postoperative role of 3D-CTA seems to be limited up to now.

But, this study shows the possibility of 3D-CTA as a postoperative method, if further development to overcome above problems, 3D-CTA will be promising and safe modality to assessment of remnant and de novo aneurysm after operations.

Sung-Kyun Hwang, M.D.

Department of Neurosurgery, Ewha Womans University