

The Clinical Comparison between Open Surgery and Percutaneous Endoscopic Lumbar Discectomy in Extraforaminal Lumbar Disc Herniation

Jin Seok Jeong, M.D., Sang-Ho Lee, M.D., Sang Jin Lee, M.D., Byeong Wook Hwang, M.D.

Department of Neurosurgery, Wooridul Spine Hospital, Busan, Korea

Objective : The objective of this study is to evaluate and compare the clinical results between classical open surgery and percutaneous endoscopic lumbar discectomy(PELD) in cases of extraforaminal lumbar disc herniation.

Methods : We obtained the clinical data from 47 patients with extraforaminal lumbar disc herniations who underwent the open paramedian muscle-splitting approach or percutaneous endoscopic lumbar discectomy(PELD) between January 2001 and February 2004. This study consisted of patients with soft disc extraforaminal herniations. The patients were assessed with the visual analogue scale(VAS) and MacNab's criteria before surgery, just before discharge, and postoperative 1 year.

Results : There were 25 cases in the open surgery group and 22 cases in the PELD group. The average operating time was 78 ± 36.71 min in the PELD group and 110 ± 29.68 min in the open surgery group. The mean hospital stay was 2.73 ± 2.62 days in the PELD group and 7.68 ± 2.59 days in the open surgery group. VAS decreased from 8.34 ± 0.66 to 1.29 ± 2.27 in the PELD group and from 8.40 ± 1.40 to 1.70 ± 1.72 in the open surgery group at the one-year follow-up. The success rate of PELD was 86.4%, compared with 80.0% for open surgery. However, there were no statistically significant difference between two groups for success rate and VAS.

Conclusion : Although the success rates were similar in both groups, PELD is less invasive, faster, and safe procedure than open surgery for extraforaminal disc herniation in selected patients.

KEY WORDS : Percutaneous endoscopic lumbar discectomy · Open lumbar microdiscectomy · Foraminal · Extraforaminal · Disc herniation.

Introduction

Extraforaminal lumbar disc herniations occurring outside or lateral to the typical intracanalicular portion have been discussed in much of the literature^{2,5,7-9,12,21,22,24} and the clinical symptoms were first well described by Abdullah et al.^{1,2}. The patients usually have mild lower back pain and severe leg pain, and the dorsal root ganglion near the foramen has been reported to be a key structure in the mechanism of radicular symptoms^{12,19,20,22}. The anatomy of the lateral lumbar spinal canal and intervertebral foramen has been described in several studies^{5,22,24}.

Although awareness of this distinct clinical syndrome has increased, debate continues over the optimal surgical treatment. Different surgical approaches have been utilized to reach the extraforaminal and foraminal disc herniations^{2,6,9,10,16,19,21,22,25}.

Presently, the most common surgical approach remains via a paramedian muscle-splitting approach, and good clinical results have been reported in cases of extra-foraminal lumbar disc herniations.

Meanwhile, recently accessing lateral disc herniations endoscopically via a percutaneous transforaminal posterolateral approach offers several advantages over the more traditional approaches^{3,4,13,15,16,18}.

There have been no papers yet reporting on the clinical results comparison between paramedian muscle-splitting approach and percutaneous endoscopic lumbar discectomy(PELD) for soft extraforaminal lumbar disc herniations. The authors obtained good clinical results with percutaneous endoscopic laser-assisted lumbar discectomy in case of soft extraforaminal lumbar disc herniations, and so we examined differences of the clinical results between two methods.

• Received : May 31, 2005 • Accepted : February 3, 2006

• Address for reprints : Jin Seok Jeong, M.D., Department of Neurosurgery, Wooridul Spine Hospital, 205-10 Nangmin-dong, Dongnae-gu, Busan 607-040, Korea Tel : +82-51-552-2100, FAX : +82-51-556-2101, E-mail : busan@wooridul.co.kr

Materials and Methods

Patient population

The medical records of 25 consecutive patients who underwent open paramedian muscle-splitting approach (open surgery) in our hospital between January 2001 and February 2004 were retrospectively reviewed.

To compare with the open surgery group, 22 patients who underwent PELD during same period were also randomly selected according to the sex and age. A successful outcome was defined as excellent or good based on the MacNab's criteria. All patients met the following criteria : 1) unilateral radicular leg pain, 2) foraminal or extraforaminal disc herniation without stenosis at single-level, confirmed by both computed tomographic(CT) scan and magnetic resonance imaging(MRI), 3) no history of previous lumbar surgery, 4) failure of appropriate conservative treatment, 5) no calcified disc herniation. The operative levels of the open surgery group were L2-3 in 1, L3-4 in 4, L4-5 in 8, and L5-S1 in 12 patients. Those of the PELD group were L3-4 in 4, L4-5 in 15, and L5-S1 in 3 patients. Clinical outcomes were assessed using the MacNab's criteria and the visual analogue scale(VAS) for leg pain before surgery, just before discharge, and one year after surgery. Data were collected by personal or telephone interviews by investigators who were not engaged in surgery, in order to obtain objective results.

Surgical technique

Paramedian muscle-splitting approach^{7,12,19-22,25)}

The patient was placed in the knee-chest position. A longitudinal skin incision, approximately 4 to 5cm in length, was made on 3.5 to 4cm lateral to the midline, with its midpoint at the level of the superior spinous process of the targeted segment after a spinal needle was placed opposite to the superior aspect of the spinous process at the target level, and the lumbar lateral x-ray film was checked.

After incision of the erector spinae aponeurosis, the fibrous separation between the multifidus and longissimus muscles was dissected using the fingertips. The fingertip identified the base of the transverse process and the lateral aspect of the facet joint. The plane was enlarged to insert the self-retaining Caspar retractor in a slightly oblique position using two different lengths of sharp tip blades. The isthmus, upper transverse process and the lateral aspect of facet joint were further exposed by cutting and removing the muscular attachments. Under the microscopic view, a high-speed drill was used to remove the lateral part of the isthmus and the lower portion of the upper transverse process in an arcuate fashion. The lateral extension of the ligamentum flavum was resected with Kerrison punch. Further dissection revealed the dorsal root ganglion.

Excessive manipulation of the root ganglion was avoided. After identification of disc material with dissectors or probes, removal of free of fragment of disc material was done and hemostasis of the operative field and wound closure was achieved.

PELD^{3,4,6,13,16,18,26)}

The minimal invasive method, PELD was performed after the patient had received a local anesthesia in the prone and kneeling position on a radiolucent table. The patient was kept conscious during the procedure to monitor any changes in symptoms and signs. The skin entry point was determined by the size of the patient's waist, dimensions of the facet joints, etc. Generally, the skin entry point should be located at far lateral position from the midline if the patient has large-sized facet joint or waist. A 18G needle was inserted 9 to 12cm off the midline. The needle tip was positioned at the midpedicular line and posterior margin of vertebral bodies under the C-arm fluoroscopic visualization. After insertion of the needle, discography was performed using dye mixed with indigocarmine.

A guide wire was inserted through the channel of the needle into the nucleus. A small stab incision was made at the entry site. After withdrawing the needle, an obturator was inserted into the intervertebral foramen through the guide wire. A working cannula was slid over the obturator, and then the obturator was removed. The cannula was cut by a trephine which was inserted through the cannula, and then intradiscal discectomy using 5mm large forceps was done. A beveled working cannula was changed through the obturator, which was then removed and then the endoscope was inserted. The beveled side of the working cannula was positioned at the exiting root zone and the migrated disc material was removed by endoscopic forcep under the endoscopic view. The thickened ligamentous material and remaining nucleus was removed using endoscopic forceps and a side-firing Ho : YAG laser (Fig. 1). When protruded disc material was removed, the scope was withdrawn and wound closure was done.

Results

There were no significant intergroup differences in the preoperative characteristics by Chi-square test, Mann-Whitney U test and Fisher's exact test (Table 1). There were 16 men, and 9 women in the paraspinous approach group and 14 men, and 8 women in the PELD group. In the paraspinous approach group and the PELD group, the mean age was 56 ± 9.12 years (\pm SD) (range 35~74 years) and 56.45 ± 10.89 years (range 33~75 years). The mean pain duration was 1064.6 ± 1802.2 days in the paraspinous approach group and 992.6 ± 1874.4 days in the PELD group. The mean admitting period was 7.68 ± 2.59 days and 2.73 ± 2.62 days in the paraspinous approach and PELD

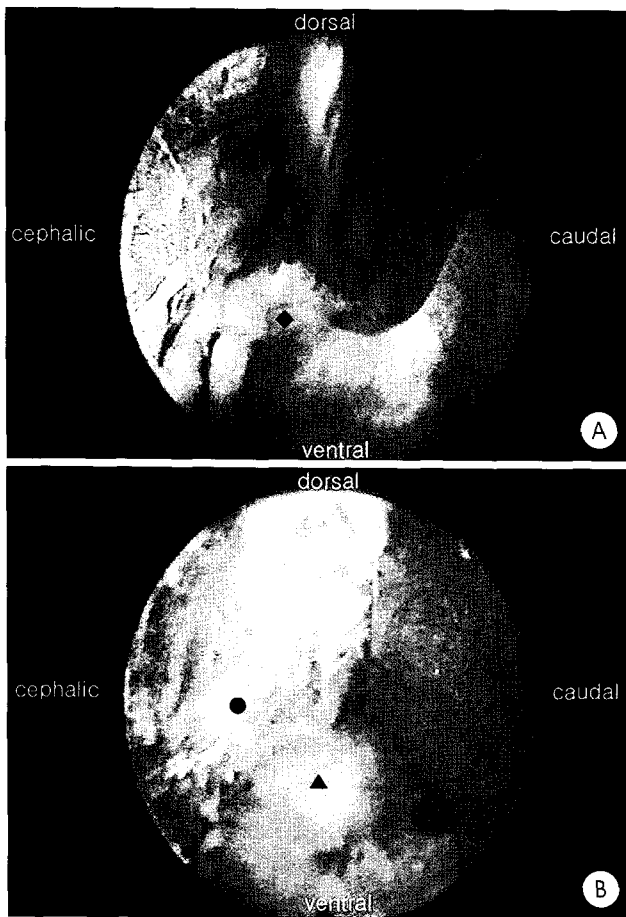


Fig. 1. A : Endoscopic view before percutaneous endoscopic lumbar discectomy(PELD) demonstrating the extraforaminal disc herniation(◆). B : Endoscopic view after PELD showing decompressed exiting nerve root(●) and the posterior body(▲).

group. The mean operation time was 110 ± 29.68 minutes and 78 ± 36.71 minutes, respectively. The frequency of occurrence was highest at L4-5 level (48.9%). Three patients had been treated L5-S1 lesion by PELD and the number was less than the number of patients who had been treated the same lesion by paraspinal approach. The surgical outcome measurements were assessed by applying the VAS and MacNab's criteria, and all patients were assessed at three time points. These were, before surgery, just before discharge and postoperative one year.

For the statistical analysis of clinical results Fisher's exact test, Chi-square test and Mann-Whitney U test were used, and in the analysis of variables p value < 0.05 was considered statically significant. VAS decreased from 8.34 ± 0.66 to 1.29 ± 2.27 in the PELD group and from 8.40 ± 1.40 to 1.70 ± 1.72 in the open surgery group at the one-year follow-up. The success rate of PELD was 86.4%, compared with 80.0% for open surgery. However, there were no statistically significant difference between two groups for success rate and VAS (Fig. 2).

There were no notable mean VAS differences and the clinical

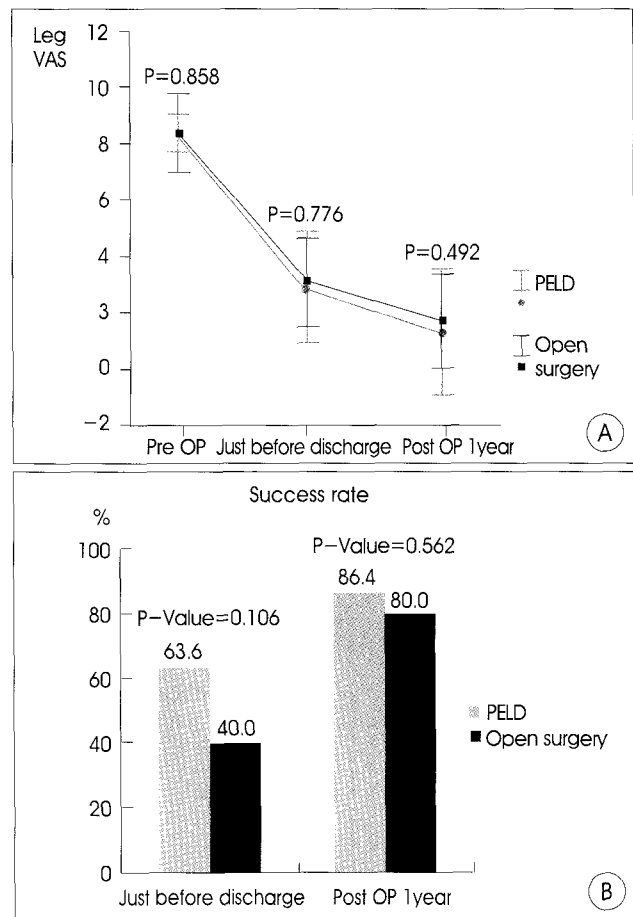


Fig. 2. A : Percutaenous endoscopic lumbar discectomy(PELD) versus open surgery by visual analogue scale(VAS). B : Success rate of PELD versus open surgery by MacNab's criteria ("good" and "excellent" subgroups are regarded to be successful).

success rate according to MacNab's criteria by the symptom duration (less than 1 week and more than 1 week) (Table 2, 3).

We defined the extruded herniation or sequestered disc through the outer annular fibers as ruptured disc type and the herniated disc material contained to annulus at herniation level as unruptured disc type. The mean leg VAS and the clinical success rate according to MacNab's criteria of patients with the unruptured disc herniation in PELD group was less than that of those with the ruptured disc type, but it was not significant statistically (Table 2, 3).

Discussion

The optimum treatment of patients with extraforaminal and foraminal disc herniations remains controversial^[8,21,24]. Extraforaminal and foraminal disc herniations have been treated by various operations for several years but the reported results have been diverse. Conventional open surgery via unilateral facetectomy is an attractive option when interbody

fusion is necessary due to combined lumbar instability and foraminal stenosis, but this approach is a too excessive operation

Table 1. Demographic data of 47 patients with extraforaminal lumbar disc herniation

Parameter	Open paraspinal approach	Percutaneous endoscopic lumbar discectomy	p value
Number of patients	25	22	
Mean age ± SD (yrs)	56 ± 9.12	56.45 ± 10.89	0.693
Male/female ratio	16:9	14:8	0.979
Symptom mean duration ± SD(days)	1064.6 ± 1802.2	992.6 ± 1874.4	0.915

Table 2. The quantity of pain in percutaneous endoscopic lumbar discectomy (PELD) versus open surgery group by mean visual analogue scale(VAS) group. The results are classified and compared with sub-grouping by symptom duration and disc herniation type

Sub group	Mean visual analogue scale		p value
	Open paraspinal approach	Percutaneous endoscopic lumbar discectomy	
Symptom duration ≤ 7			
Pre OP	7.250	8.625	0.476
Just before discharge	3.083	2.000	0.352
Post OP 1 year	2.000	1.125	0.252
Symptom duration > 7			
Pre OP	8.278	8.763	0.004
Just before discharge	3.053	3.111	0.922
Post OP 1 year	1.605	1.333	0.705
Ruptured type disc			
Pre OP	8.350	8.500	0.647
Just before discharge	3.550	2.971	0.440
Post OP 1 year	1.800	1.529	0.756
Unruptured type disc			
Pre OP	8.433	7.800	0.033
Just before discharge	2.733	2.700	0.866
Post OP 1 year	1.633	0.500	0.349

Table 3. Success rate of PELD versus open surgery by Macnab's criteria. The results are classified and compared with sub-grouping by symptom duration and disc herniation type

Sub group	Mean Success rate by Macnab's criteria (%)		p value
	Open paraspinal approach	Percutaneous endoscopic lumbar discectomy	
Symptom duration ≤ 7			
Just before discharge	33.3	75.0	0.197
Post OP 1 year	83.3	100.0	0.389
Symptom duration > 7			
Just before discharge	42.1	61.1	0.248
Post OP 1 year	78.9	83.3	0.734
Ruptured type disc			
Just before discharge	30.0	58.8	0.148
Post OP 1 year	80.0	82.4	0.879
Unruptured type disc			
Just before discharge	46.7	80.0	0.194
Post OP 1 year	80.0	100.0	0.278

in soft disc foraminal or extraforaminal herniation^{7,8}. The midline approach (laminectomy and medial facetectomy) combined with partial resection of pars interarticularis can be used to reach a herniated disc that is in a foraminal area, and this technique is familiar to all spinal surgeons^{2,7}. However, there are numerous disadvantages^{7,13,19}. In the treatment of extraforaminal disc herniation, the extent of bone resection for adequate exposure may induce spinal instability. The leg pain may be persistent due to remaining disc materials in the extracanalicular portion.

Combined approaches^{7,8,10,24} involving dissection both medially and laterally to the neural foramen have also been reported. These approaches allow better exposure and less extensive bone removal. However, there are several disadvantages, such as extensive retraction and dissection of paraspinal musculature, and the relatively longer operative time.

Paraspinal muscle-splitting approaches have been well described^{2,21,22,24} and provide excellent exposure for removing foraminal and extraforaminal lesions. Compared with midline approaches, a less extensive bone resection is required. Therefore, motion segment stability can be preserved. Disadvantages include an often deep and disorienting trajectory to the lesion, as well as diminished exposure when facet hypertrophy or more medial pathological material is present, troublesome bleeding from the lumbar artery and accompanying veins and postoperative burning dysesthesia. Nevertheless, the paramedian approaches^{7,8,10,22} remain as an excellent surgical option.

In recent years, percutaneous techniques for treating lumbar disc herniations have been developed. At first, many surgeons performed central decompression with chemoneucleolysis and automated percutaneous lumbar discectomy. Recently, a few spinal surgeons have done direct epidural targeted fragmentectomy in central or paracentral lumbar disc herniation after using the endoscope and various tools^{3,10,24}. Although satisfying clinical outcomes have been demonstrated with PELD, it requires highly experienced endoscopic skills and the clinical outcomes can be affected by the surgeon's technique. PELD has been used for various indications, for example, extraforaminal and foraminal lumbar disc herniation, recurred disc herniation, lateral exit zone stenosis and lytic or degenerative spondylolisthesis in old-aged patients with leg pain. Good surgical results in the literature have been reported^{3,4,16-18}. But, one should evaluate the results of long term follow up of that procedure. If the herniated mass is calcified or combined with severe spinal stenosis, the effect of an endoscopic removal could be limited.

In the present study there were no statistically significant difference between two groups for success rate and VAS (Fig. 2). We, therefore, thought that PELD was as effective as open surgery for the treatment of extraforaminal disc herniation in

selected patients.

The herniated nucleus pulposus material could be removed without excessive retraction by PELD in ruptured herniation cases. The mean leg VAS of the paraspinous approach and the PELD group was equivalent in ruptured herniation cases. In those cases, disconnection of free fragment and the main nucleus was important because trying to remove protruded disc material in the early stage of the operation might cause bleeding and so it is unable to see the endoscopic view and it might be difficult to remove free fragment disc material connected to the main nucleus. Cutting the stalk which links ruptured disc material with internal nucleus and loosening annular portion torn by protruded disc with lasering make it possible to remove the migrated disc material easily. Ruptured materials could be removed with one or two lumps by small forcep. After identifying the exiting root under endoscope or trying to pass through the pathway of exiting root by an electrocoagulator tip with probing under C-arm, we could know whether herniated disc material was remained in the lesion.

It is somewhat limited to the use of endoscope for approaching L5-S1^{14,23)}. In our study, there were a few patients with pure extraforaminal disc at the L5-S1 level (12 cases in the open surgery group and 3 in the PELD group). A total of 127 patients with extraforaminal lesion in L5-S1 level underwent percutaneous endoscopic laser discectomy, microscopic decompressive discectomy or interbody fusion between January 2001 and February 2004. Among these patients, 72 patients underwent open paraspinous approach with or without midline approach due to calcified and intervertebral foramen stenosis. Thirty six patients underwent interbody fusion (anterior lumbar interbody fusion or posterior lumbar interbody fusion with screws fixation) due to combined degenerated disc disease.

PELD was treated in 4 patients who couldn't undergo general anesthesia. They had extraforaminal disc herniations with combined mild instability or lytic spondylolisthesis in L5-S1 level. Especially, the possibility of access should be considered in advance in those cases that the transverse process of lumbar is too big and that the iliac crest is too high for cannular insertion. Therefore, we could treat only 3 patients with PELD and many cases were excluded in this study. The authors will restudy clinical results including more cases through the long term follow up.

Conclusion

The clinical results of patients who underwent PELD was similar to the patients who underwent discectomy through paramedian muscle-splitting approach. PELD is recommendable in cases of no other lesions affected the main symptom, no foraminal stenosis, no severe degenerated disc at the

target level due to several advantages such as shorter hospital stays, shorter operative time, and less destruction of normal tissue.

• Acknowledgement

This study was supported by a research fund from Wooridul Spine Foundation.

References

1. Abdullah AF, Ditto EW III, Byrd EB, Williams R: Extreme-lateral lumbar disc herniations. Clinical syndrome and special problems of diagnosis. *J Neurosurg* 41 : 229-234, 1974
2. Abdullah AF, Wolber PG, Warfield JR, Guandi AK: Surgical management of extreme-lateral lumbar disc herniations : review of 138 cases. *Neurosurgery* 22 : 648-653, 1988
3. Ahn Y, Lee SH, Park WM, Lee HY : Posterolateral percutaneous endoscopic lumbar foraminotomy for L5-S1 foraminal or lateral exit zone stenosis. *J Neurosurg (Spine 3)* 99 : 320-323, 2003
4. Ahn Y, Lee SH, Park WM, Lee HY, Shin SW, Kang HY : Percutaneous endoscopic lumbar discectomy for recurrent disc herniation : surgical technique, outcome, and prognostic factors of 43 consecutive cases. *Spine* 29 : 326-332, 2004
5. Caglar Y YS, Dolgun H, Ugur HC, Kahilogullari G, Tekdemir I, Elhan A : A ligament in the lumbar foramina: inverted Y ligament : an anatomic report. *Spine* 29 : 1504-1507, 2004
6. Ditsworth DA : Endoscopic transforaminal lumbar discectomy and reconfiguration : a postero-lateral approach into the spinal canal. *Surg Neurol* 49 : 588-598, 1988
7. Donaldson WF, Star MJ, Thorne RP : Surgical treatment of far lateral herniated lumbar disc. *Spine* 18 : 1263-1267, 1993
8. Epstein NE : Different surgical approaches to far lateral lumbar disc herniations. *J Spinal Disord* 8 : 383-394, 1995
9. Epstein NE : Evaluation of varied surgical approaches used in the management of 170 far-lateral lumbar disc herniations : indications and results. *J Neurosurg* 83 : 648-656, 1995
10. Epstein NE : Foraminal and far lateral lumbar disc herniations : surgical alternatives and outcome measures. *Spinal Cord* 40 : 491-500, 2002
11. Hijikata S : Percutaneous nucleotomy : A new concept technique and 12 years' experience. *Clin Orthop* 238 : 9-23, 1989
12. Jackson RP, Glah JJ : Foraminal and extraforaminal lumbar disc herniation : diagnosis and treatment. *Spine* 12 : 577-585, 1987
13. Jeong HS, Lee SH, Hwang BW, Lee SJ, Jang HS, Shin SW : Percutaneous endoscopic lumbar discectomy for the treatment of far lateral lumbar disc herniation. *J Korean Neurosurg Soc* 34 : 325-328, 2003
14. Kambin P : Percutaneous Lumbar discectomy, in Kambin P (ed) : *Arthroscopic Microdiscectomy, Minimal Intervention in Spinal Surgery*. Baltimore : Urban and Schwarzeberg, 1991, pp67-100
15. Kambin P, Gellman H : Percutaneous lateral discectomy of the lumbar spine : a preliminary report. *Clin Orthop* 174 : 127-132, 1983
16. Knight MTN, Goswami AKD : Endoscopic laser foraminoplasty in Savitz MH, Chiu JC, Yeung AT(eds) : *The Practice of Minimally Invasive Spinal Technique*, ed 1. Richmond, VA : AAMISMS Education, LLC, 2000, pp337-340
17. Lee HY, Ahn Y, Kim DY, Shin SW, Lee SH : Percutaneous ventral decompression for L4-L5 degenerative spondylolisthesis in medically compromised elderly patients : technical case report. *Neurosurgery* 55 : 455-459, 2004
18. Lew SM, Mehlic TF, Fagone KL : Transforaminal percutaneous endoscopic discectomy in the treatment of far-lateral and foraminal lumbar disc herniations. *J Neurosurg(Spine 2)* 94 : 216-220, 2001
19. Maroon JC, Kopitnik TA, Schulhof LA, Abla A, Wilberger JE : Diagnosis and microsurgical approach to far-lateral disc herniation in the lumbar spine. *J Neurosurg* 72 : 378-382, 1990
20. Maroon JC, McKenzie R : Far lateral disc herniations. *Contemp Neurosurg* 15 : 1-6, 1993
21. O'Brien MF, Peterson D, Crockard A : A posterolateral microsurgical approach to extreme lateral lumbar disc herniation. *J Neurosurg* 83 : 637-640, 1995

22. O'Hara LJ, Marshall RW : Far lateral lumbar disc herniation. The key to the intertransverse approach. *J Bone Joint Surg* 79B : 943-947, 1997
23. Romy M : The oblique approach to L5-S1 in percutaneous discectomy. *Orthop Rev* 45 : 19-23, 1996
24. Viswanathan R, Swamy NK, Tobler WD, Greiner AL, Keller JT, Dunsker SB : Extraforaminal lumbar disc herniations : microsurgical anatomy and surgical approach. *J Neurosurg(Spine 2)* 96 : 206-211, 2002
25. Wang QP, Lee NS, Zhang Y, Liu J, Zhu JY : Intertransverse approach for extraforaminal herniations. *Spine* 22 : 701-705, 1997
26. Yeung AT, Tsou PM : Posterolateral endoscopic excision for lumbar disc herniation : Surgical technique, outcome, and complications in 307 consecutive cases. *Spine* 27 : 722-731, 2002

Commentary

The authors' work on the effectiveness of percutaneous endoscopic discectomy is very excellent. I appreciate the high level of scientific evidence of the study and frank and comprehensive description in the discussion. It will surely contribute to establish the effectiveness of the percutaneous endoscopic discectomy. But, I would like to comment the important point that the authors missed. It think it is originated from the special characteristics of the percutaneous endoscopic discectomy.

The comparison of two different operative methods is sometimes very complicated task because we cannot apply different operation to the same patient. Simply measuring pre and postoperative parameters can result in misleading conclusions.

In the case of percutaneous endoscopic discectomy, we can find several publications on its effectiveness. But, the most important question is still unanswered- "In what case do you perform endoscopic discectomy?, i.e, the indication. It may depend on the shape of the herniated disc, the anatomy of the spine surrounding the disc herniation, or the age of the patient. It is also different among the surgeons. I know it is very difficult to describe the exact indication of percutaneous endoscopic discectomy. But if you ask the indication to the surgeon who have experience he can simply answer that "I do when the herniated disk can be removed by percutaneous approach."

Despite the advancement of instruments and technique in percutaneous discectomy, there is no surgeon who abandoned open discectomy completely. That is the surgeon knows that there are cases who cannot treated with percutaneous technique. If my reasoning is right, it is very difficult randomly select the operative method; 'percutaneous or open'. Personally, I think it is impossible practically because we cannot choose percutaneous approach when it may not work. If the authors 'randomly' allocated the patient in choosing the operative method, the exact method of allocation should have been described.

Sanki Chung, M.D., Ph.D.

Department of Neurosurgery, Seoul National University