

Novalis Radiosurgery of Primary Central Nervous System Lymphoma in Elderly Patients : Preliminary Results

Seong Rok Han, M.D., Gi Taek Yee, M.D., Chan Young Choi, M.D., Ph.D.,
Moon Jun Sohn, M.D., Ph.D., Dong Joon Lee, M.D., Ph.D., Choong Jin Whang, M.D., Ph.D., F.A.C.S.
Department of Neurosurgery, Ilsan Paik Hospital, College of Medicine, Inje University, Goyang, Korea

Objective : Primary central nervous system lymphoma(PCNSL) is a non-Hodgkin's lymphoma arising in the central nervous system. Combined chemotherapy and radiation therapy is the standard treatment for PCNSL. However, treatment induced neurotoxicity is a major problem especially in elderly patients.

Methods : From May 2001 to April 2004, elderly five patients with PCNSL confirmed via pathological examination were underwent Novalis radiosurgery in authors' institution, who were investigated retrospectively. Of these patients, 2 were male and 3 were female, with a mean age 68 years old (range 65-73). The number of lesions was 1 in 2 patients, 2 in 2, and 3 in 1. The mean follow up period was 12.6 months (range 8-16).

Results : Clinical symptoms and signs in all patients markedly improved within 1 weeks after Novalis radiosurgery. The Karnofsky performance status score was also improved from a pre-radiosurgery average of 68 to a post-radiosurgery one of 82. All of treated lesions showed a partial or complete regression of the original mass. There have been no complication following Novalis radiosurgery.

Conclusion : The preliminary results of our experience indicate that radiosurgery with Novalis provides a safe and effective therapeutic alternative treatment of PCNSL in elderly patients.

KEY WORDS : Lymphoma · Elderly · Radiotherapy · Radiosurgery · Novalis.

Introduction

Primary central nervous system lymphoma(PCNSL) is an extranodal form of non-Hodgkin's lymphoma arising in the craniospinal axis. The majority of PCNSL are high grade non-Hodgkin's lymphomas of B-cell type. For many years, PCNSL was reported to 1~3% of all primary central nervous system(CNS) tumors^{1,2}. Over the last decade, the incidence of PCNSL reported in most studies has risen threefold². This rise can be partially attributed to the prolonged survival of AIDS patients and the extensive use of immunosuppressive therapy in organ transplantation and autoimmune disease³.

The optimal treatment for PCNSL has not been established yet. Prognosis of PCNSL is poor and median survival is 3~5 months in untreated patients^{3,12}.

Combined radiotherapy(RT) and chemotherapy is currently the standard treatment used for PCNSL. However, the best RT and chemotherapy regimens are still under discussion¹².

Even without apparent leucoencephalopathy, the quality of life in surviving PCNSL patients is not good, and a proportion of patients suffer from mental deterioration after the treatment¹. The reason for this is not clear, but the incidence appears to be higher in patients treated with RT than in those treated without it⁶. Treatment induced general toxicity may represent an important factor that deserves to be considered for therapeutic decision⁴.

We retrospectively reviewed elderly patients of PCNSL treated with Novalis (Brain LAB AG, Germany) radiosurgery.

Materials and Methods

From May 2001 to April 2004, elderly five patients with PCNSL confirmed via pathological examination were underwent Novalis radiosurgery in authors' institution. Of these patients, two were male and three were female. The mean age 68 years old (range 65~73). The number of lesions was 1 in

• Received : November 28, 2005 • Accepted : January 2, 2006

• Address for reprints : Seong Rok Han, M.D., Department of Neurosurgery, Ilsan Paik Hospital, College of Medicine, Inje University, 2240 Daehwae-dong, Ilsan-gu, Goyang 411-410, Korea Tel : +82-31-910-7730,7740, Fax : +82-31-915-0885, E-mail : hsrkmj@ilsanpaik.ac.kr

Table 1. Summary patients characteristics and results after Novalis radiosurgery

Case No	Sex/ Age	Sign and Symptom	Number of lesion	Tumor volume (mm ³)	Radiation dose (Gy)	Initial KPS score	Post-RS KPS score	Radiological Response	Time interval secondary repeated RS (months)	Number of repeated RS	Follow-up (months)	Survival (months)
1	F/69	hemiparesis	1	11140 10360	18 15	60	80	CR CR	2	2	8	-
2	M/67	headache	3	150 60	10 14	80	90	CR CR	2	2	14	-
3	F/67	paraparesis	2	6420 390	17 17	60	80	CR CR	5	5	16	D (19)
4	M/65	memory disturbance	2	9320 250	15 15	70	80	CR CR	2	2	13	D (16)
5	F/73	memory disturbance	1	8550	1.8×20 (F)	70	80	PR	4	4	12	D (12)

RS : radiosurgery, F : fractionation, CR : complete regression, PR : partial regression, D : death

2 patients, 2 in 2, and 3 in 1. No patients who had undergone transplantations or who suffered from AIDS were included in the series. Karnofsky performance status(KPS) score was 70 or more in 3 patients, and less than 70 in 2.

The main clinical symptoms and signs of PCNSL included the motor weakness (2 cases, 40%), memory disturbance (2, 40%), and headache (1, 20%). The most frequent tumor location was periventricular white matter. 4 patients underwent stereotactic biopsy and 1 underwent craniotomy, with all patients being pathologically confirmed high grade diffuse large B-cell type lymphoma. Corticosteroids were administered to all patients as part of the initial management strategy. Since then, Novalis radiosurgery procedures were performed all patients. The patients' characteristics are described in Table 1.

Results

Outcomes of Novalis radiosurgery

Initially, a total of 9 lesions were treated. The mean total tumor volume was 5182.2mm³ (60~11140mm³). Mean 80% of isodose is 17.4 Gy (10~36 Gy) was prescribed at the tumor margin. 8 lesions were treated single radiosurgery, 1 lesion was treated fractionated radiosurgery. Clinical symptoms and signs in all patients markedly improved within 1 weeks after Novalis radiosurgery. The KPS score was also improved from a pre-radiosurgery average of 68 to a post-radiosurgery one of 82. All of treated lesions showed that a partial or complete regression of the original mass in the follow-up images (Fig. 1, 2).

Repeated Novalis radiosurgery

All patients were treated more than once by Novalis radiosurgery for local or distant recurrent lesions. Mean time interval that second Novalis radiosurgery performed was 4.2 months (1~9 months). Among these patients, 1 patient underwent 4

times repeated Novalis radiosurgery, and 1 patient underwent 5 times Novalis radiosurgery. Ultimately, A total of 45 lesions were treated and the mean number of lesions was 3 in each procedure. The mean total tumor volume was 4707.3mm³

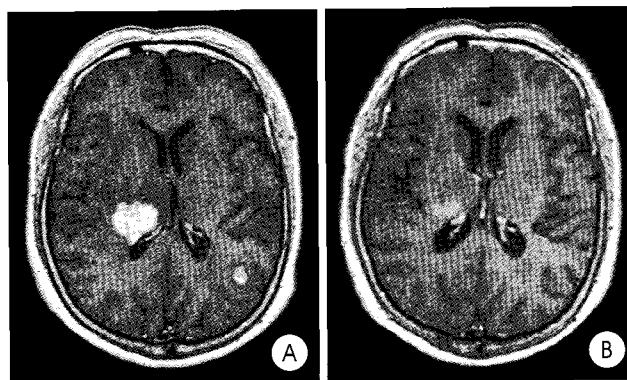


Fig. 1. Case No 3. Initial gadolinium(Gd) enhanced T1 weighted axial magnetic resonance(MR) image (A) shows that well-enhanced two mass located in right thalamus and left occipital gyrus. One month After radiosurgery, T1 weighted Gd enhanced axial MR image (B) reveals that the mass size is significantly reduced.

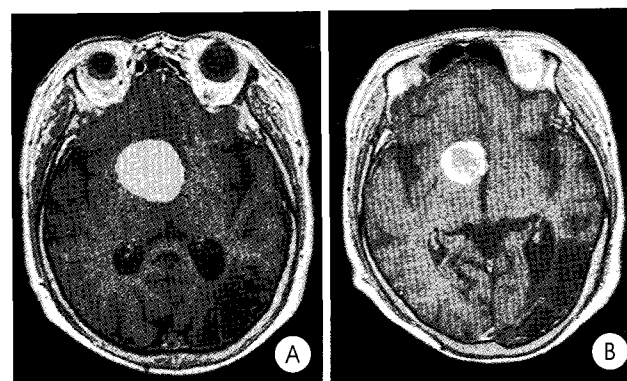


Fig. 2. Case No 5. Initial gadolinium(Gd) enhanced axial T1 weighted magnetic resonance(MR) image (A) shows well-enhanced mass located in right frontal lobe. One month later radiosurgery, T1 weighted Gd enhanced axial MR image (B) reveals that reduction of original mass.

(30~99710mm³). Mean 80% of isodose is 18.6 Gy (7~51Gy) was prescribed at the tumor margin. 42 lesions were treated single radiosurgery, and 3 lesions were treated fractionated radiosurgery. The mean follow up period was 12.6 months (8~16 months). 3 patients died. Among them, 1 patient died of respiratory failure due to lung metastasis. Mean survival of 3 patients was 15.7 months (12~19 months). Summary of results after Novalis radiosurgery were described in Table 1.

Complication following Novalis radiosurgery

There had been no complication following Novalis radiosurgery. There was no evidence of symptomatic brain edema. Especially, no patient had shown cognitive impairment.

Discussion

PCNSL has been described at all ages, but usually arise at 50~60 years of age, with a male to female ratio of 1:5¹². PCNSL usually presents either as a single or multi-centric tumor, often located deeply in the cerebral hemispheres with a predilection for periventricular brain tissue. The frontal lobe is often affected¹⁰. Clinical symptoms are focal neurological deficits, altered mentation, seizures, fever and increased intracranial pressure, which are often presented in the early stages of this disease^{5,12}. The characteristics of magnetic resonance image findings of PCNSL are homeogenous contrast enhancement with gadolinium¹².

PCNSL is sensitive to RT. Between 70% and 90% of the patients treated with RT alone for PCNSL showed neurologic or radiologic improvement^{8,11}. But long-term survival or quality of life after RT alone was not satisfactory. patients treated with RT alone had 5-year overall survival of 3~4%, and >80% relapsed within 10~14 months⁹.

As survival of patients with PCNSL increases, the quality of life and mental function become very important. The neurotoxicity related to the combination of methotrexate and RT is common, especially among elderly people, in whom rates reach up to 90%. The neurotoxicity can be severely disabling, and is the cause of death in up to 50% of affected people⁷. The elderly patients in poor physical condition cannot tolerate prolonged RT and some patients suffering from recurrences were not capable of undergoing RT once again. Efforts are now being directed towards not only improving the level of disease control but also minimizing late neurotoxicity so that maintain a good quality of life⁵.

Dong et al.⁵ reported that 44 patients with PCNSL treated gamma knife radiosurgery(GKS). In their study, treated with combination methotrexate and GKS had a significantly longer survival than those treated with GKS alone. But as mentioned above, the neurotoxicity related combination of methotrexate

and RT is problem, especially elderly people⁷. So we didn't actively recommend elderly patients with PCNSL to chemotherapy. PCNSL treated with radiosurgery allows the safe delivery of a high dose of radiation to a defined target of solid tumor, with rapid escalation of the radio-biological effects within the boundary of that target, and sharp fall in dose delivered to neighboring normal brain tissue⁵ and the period of hospitalization is short, which is cost-effectiveness also.

No neurotoxicity related to Novalis radiosurgery treatment has been noticed in our cases. Follow-up images do not show any evidence of radionecrosis within the normal brain tissue.

Conclusion

The preliminary results of our experience indicate that radiosurgery with Novalis provides a safe and effective therapeutic alternative treatment of PCNSL in elderly patients. Short-term clinical follow-up showed an improvement in both KPS score and neurological symptom. From radiological point of view, a partial or complete regression of the original mass is documented. But further prospective randomized studies are needed to address the effect of Novalis radiosurgery in the treatment of PCNSL in elderly patients.

References

1. Abrey LE, DeAngelis LM, Yahalom J : Long-term survival in primary CNS lymphoma. *J Clin Oncol* 16 : 859-863, 1998
2. Bataille B, Delwail V, Menet E, Vandermarcq P, Ingrand P, Wager M, et al : Primary intracerebral malignant lymphoma : report of 248 cases. *J Neurosurg* 92 : 261-266, 2000
3. Bellinzona M, Roser F, Ostertag H, Gaab RM, Saini M : Surgical removal of primary central nervous system lymphomas(PCNSL) presenting as space occupying lesion : a series of 33 cases. *Eur J Surg Oncol* 31 : 100-105, 2005
4. Depil S, Coiteux V, Guillermin G, Gyan E, Bauters F, Fenaux P, et al : Primary central nervous system lymphoma in immunocompetent adults : poor results mainly associated with high treatment related toxicities. *Leuk Lymphoma* 43 : 1819-1822, 2002
5. Dong Y, Pan L, Wang B, Wang E, Zhang N, Cai P, et al : Stereotactic radiosurgery in the treatment of primary central nervous system lymphoma. *Chin Med J* 116 : 1166-1170, 2003
6. Freilich RJ, Delattre JY, Monjour A, DeAngelis LM : Chemotherapy without radiation therapy as initial treatment for primary CNS lymphoma in older patients. *Neurology* 46 : 436-439, 1996
7. Hodson DJ, Bowles KM, Cooke LJ, Klager SL, Powell GA, Laing RJ, et al : Primary central nervous system lymphoma : a single-centre experience of 55 unselected cases. *Clin Oncol (R Coll Radiol)* 17 : 185-191, 2005
8. Kim IM, Lee CY, Son EI, Kim DW, Yim MB, Kim SP : Treatment strategies for primary central nervous system lymphoma. *J Korean Neurosurg Soc* 30 : 334-341, 2001
9. Nelson DF : Radiotherapy in the treatment of primary central nervous system lymphoma(PCNSL). *J Neurooncol* 43 : 241-247, 1999
10. Tomlinson FH, Kurtin PJ, Suman VJ, Scheithauer BW, O'Fallon JR, Kelly PJ, et al : Primary intracerebral malignant lymphoma : a clinicopathological study of 89 patients. *J Neurosurg* 82 : 558-566, 1995
11. Wu HG, Kim IH, Ha SW, Park CI, Bang YJ, Huh DS : Survival improvement with combined radio-chemotherapy in the primary central nervous system lymphomas. *J Korean Med Sci* 14 : 565-570, 1999
12. Yamanaka R, Tanaka R : Advances for the treatment of primary central nervous system lymphoma (review). *Oncol Rep* 12 : 563-568, 2004

Commentary

The author reported their preliminary results of repeated Novalis radiosurgery for primary central nervous system lymphoma (PCNSL) as an initial and only treatment method.

PCNSL is an aggressive non-Hodgkin lymphoma arising within the brain, spinal cord, or leptomeninges. It usually has poorly defined margin, reflecting their tendency to infiltrate white matter tracts including corpus callosum and internal capsule, and shows multiple lesions in about 30%. The clinical utility of radiosurgery lies in its ability to deliver high doses of radiation to sharply defined target volumes. The more conformal the radiation field, the higher the dose that can be delivered to the target without exposing the surrounding non-targeted tissue to potentially toxic radiation¹⁾.

The main concern related to the treatment option selected in this paper is the use of a very focal treatment in a disorder which is often multifocal even in the presence of initially otherwise normal imaging. Even if PCNSL occurred as a solitary lesion, diffuse microscopic spread would be nearly always present and responsible for the development of distant and local recurrences. MRI grossly underestimates the microscopic infiltration throughout the CNS by tumor cells²⁻⁴⁾. In these points, the potentially multifocal and infiltrative tumors such as PCNSL, germinoma, granulocytic sarcoma, and etc are different from other metastatic brain tumors. That is the re-

ason PCNSL is not suitable for radiosurgery (especially repeated radiosurgery) and there have been only a few previous reports about radiosurgery for PCNSL. We might try initial or boost radiosurgery for prompt reduction of patient's symptoms, but it should be combined by chemotherapy and/or central nervous system radiation (at least radiation therapy alone) even in elderly patients.

In conclusion, we should keep it in mind that local management techniques alone in PCNSL are not enough for these potentially multifocal & microscopically infiltrative disorders. Radiosurgery might be used only for boost treatment with a palliative aim before or after whole brain radiation in selective cases like recurrent PCNSL.

Yong Gou Park, M.D.

Department of Neurosurgery, Yonsei University

References

1. Campbell PG, Jawahar A, Fowler MR, DeLaune A, Nanda A : Primary central nervous system lymphoma of the brain stem responding favorably to radiosurgery : a case report and literature review. *Surg Neurol* 64 : 400-405, 2005
2. Lai R, Rosenblum MK, DeAngelis LM : Primary CNS lymphoma : a whole-brain disease? *Neurology* 59 : 1557-1562, 2002
3. Nelson DF : Radiotherapy in the treatment of primary central nervous system lymphoma. *J Neurooncol* 43 : 241-247, 1999
4. Sakamoto M, Oya N, Mizowaki T, Araki N, Nagata Y, Takayama K, et al : Initial experiences of palliative stereotactic radiosurgery for recurrent brain lymphomas. *J Neurooncol* 2005 Sep 16 [Epub ahead of print]