

Endoscopic Aqueductoplasty and Stenting for Isolated Fourth Ventricle

Won Ho Cho, M.D., Sang Weon Lee, M.D., Seung Heon Cha, M.D.

Department of Neurosurgery, Pusan National University School of Medicine, Busan, Korea

Isolated fourth ventricle (IFV) is a rare entity producing symptoms of a progressive posterior fossa mass lesion. It is mainly reported in a patient who undergo shunt placement as its late complication. However, its surgical management has been difficult and its optional treatment remains controversial. We had an occasion to admit 19-year-old female to our hospital due to hydrocephalus: she had a history of meningitis when she was 2 years old. Ten years later, she was diagnosed as hydrocephalus and managed by lateral ventriculo-peritoneal shunting procedure. Seven years after the procedure, the patient presented with headache, nausea, truncal ataxia and nystagmus. Computed tomography and magnetic resonance image scan demonstrated markedly enlarged fourth ventricle: and thus, neuroendoscopic aqueductoplasty and aqueductal stent insertion was performed. The authors present a case of an IFV after lateral ventriculo-peritoneal shunting for hydrocephalus, which was treated successfully with a neuroendoscopic surgery. The technique of this procedure is described below.

KEY WORDS : Isolated fourth ventricle · Hydrocephalus · Neuroendoscopic surgery · Aqueductal stenosis.

Introduction

Isolated fourth ventricle (IFV) is a rare entity that is most often reported in children as a complication of shunting for hydrocephalus that developed after inflammatory diseases such as infection and hemorrhage^{4,6,7,10,11,13}. In the literature, this unusual entity has been variously described such as isolated^{11,21}, trapped^{2,10}, encysted¹⁴, occluded³, sequestered¹⁵ fourth ventricle, or double compartment hydrocephalus⁶. Signs and symptoms of IFV include neck pain or stiffness, ataxia, tetraparesis, and altered level of consciousness. IFV may result in rapid deterioration of consciousness in a patient with shunted lateral ventricle^{6,18,19}. Therefore, urgent surgical management is needed in symptomatic IFV patients. Treatment options of the IFV include open surgery, cerebrospinal fluid (CSF) diversion, and endoscopic surgery. However, surgical management of the IFV has been problematic and optimal treatment

in the IFV patients remains controversial.

We report a case of the IFV developed following lateral ventricle shunt placement for hydrocephalus and treated successfully with neuroendoscopic aqueductoplasty and aqueductal stent insertion.

Case Report

A 19-year-old female patient was admitted to our hospital with complaint of severe headache, which was associated

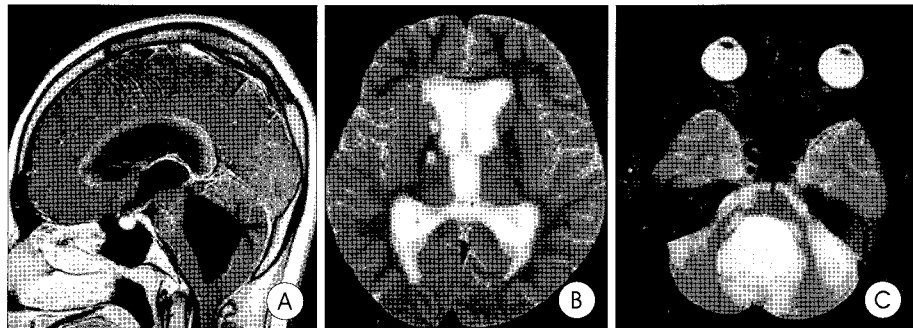


Fig. 1. A : Preoperative T1-weighted sagittal magnetic resonance MR imaging demonstrates mild enlargement of third and lateral ventricles and markedly dilated fourth ventricle with aqueductal stenosis. B and C : Preoperative T2-weighted axial MR image reveals mild enlargement of lateral and third ventricles and marked dilatation of the fourth ventricle with periventricular edema.

• Received : July 4, 2005 • Accepted : September 23, 2005

• Address for reprints : Sang Weon Lee, M.D., Department of Neurosurgery, Pusan National University School of Medicine, 1-10 Ami-dong, Seo-gu, Busan 602-739, Korea Tel : +82-51-240-7257, 247-0244, Fax : +82-51-244-0282, E-mail : md@medimail.co.kr

with occasional nausea and vomiting. Her headache was not relieved by analgesics. In the medical history of the patient, she was treated for bacterial meningitis when she was 2 years old. Ten years after meningitis, the patient was underwent ventriculo-peritoneal shunt for hydrocephalus. Neurological examination revealed truncal ataxia and nystagmus.

Brain Magnetic Resonance(MR) images showed mild enlargement of lateral and third ventricles and marked dilatation of the fourth ventricle (Fig. 1). Under the presumptive diagnosis of isolated fourth ventricle and malfunction of shunt, we performed endoscopic aqueductoplasty and stent placement with change of the shunt devices.

Surgery

Under general anesthesia, this patient underwent neuroendoscopic intraventricular approach. At first, a frontal burr hole was made just behind the hairline and 2.5cm lateral to the

midline in the right frontal bone. This far frontal burr hole makes it easier to reach the posterior third ventricle without stretching the fornices at the foramen of Monro. The neuroendoscope (Aesculap AG, Tuttlingen, Germany) with outer diameter of 2mm and trocar with outer diameter of 6mm was inserted into the lateral

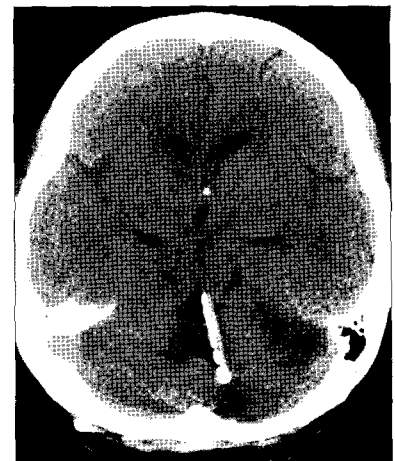


Fig. 4. Computed tomography scan obtained 6 month after surgery shows marked reduction in size of the fourth ventricle.

lateral ventricle and standard anatomical landmark were identified. The neuroendoscope was advanced through the foramen of Monro into the third ventricle. We identified the membranous occlusion of the aqueduct. Aqueductoplasty was performed with 3-French Fogarty balloon catheter and neuroendoscope was withdrawn. We prepared the ventricular catheter and made multiple slits on the side wall of the catheter. And then, we reinserted the 2-mm diameter neuroendoscope which was attached with the ventricular catheter without trocar. Under neuroendoscopic direct visualization of the aqueduct, the catheter was introduced through the aqueduct into the fourth ventricle (Fig. 2). After withdrawal of the neuroendoscope, the distal end of the catheter was occluded and anchored to the burr hole to prevent migration of the catheter. And then, we removed the previously placed shunt devices and reinserted new shunt materials.

Postoperative course

The patient made an uneventful recovery. Her preoperative symptoms including headache, ataxia, nystagmus improved gradually. The patient was discharged without any complication. At 6 months follow-up, the patient was fully independent and lateral skull x-ray study and computed tomography scan revealed the correct position of the catheter (Fig. 3) and the marked reduction of the size of the fourth ventricle (Fig. 4).

Discussion

Since the first report on the symptomatic expansion of the fourth ventricle secondary to prolonged shunting of the lateral ventricle by Hawkins et al.^{11),} diagnosis of the isolated fourth ventricle(IFV) has increased with the advent of modern neuro-imaging modality although it is still rarely encountered by the general neurosurgeon.

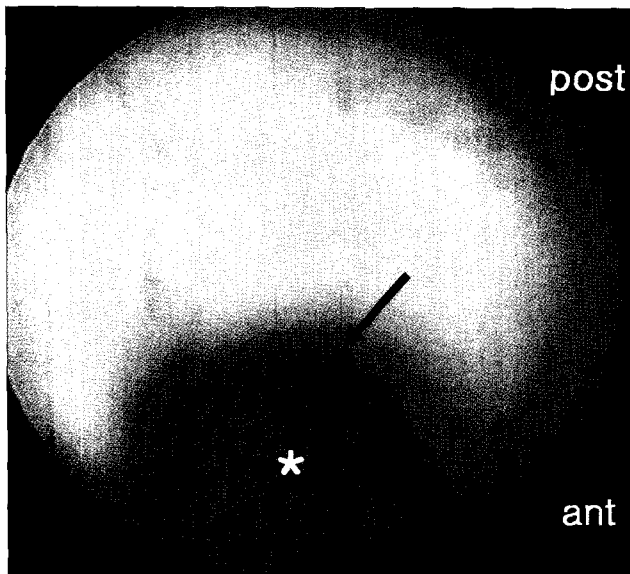


Fig. 2. Neuroendoscopic view. Stent placement in the orifice of the aqueduct (arrow) with ventricular catheter (asterisk). ant : anterior, post : posterior.

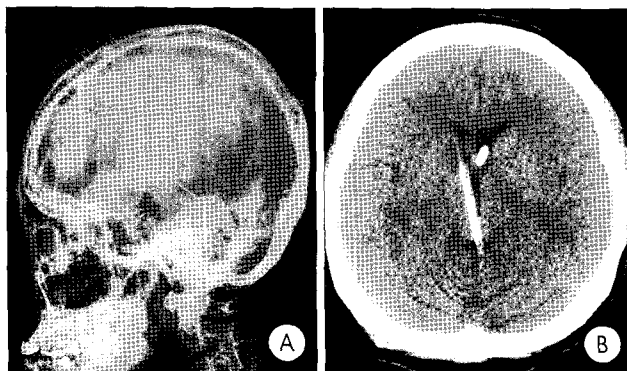


Fig. 3. Lateral skull x-ray(A) and computed tomography scans(B) show the catheter passing through the lateral ventricle, third ventricle, and cerebral aqueduct and devices of lateral ventriculo-peritoneal shunt.

Most cases of IFV occur following a prolonged lateral ventricular shunting after post-meningitic or post-hemorrhagic hydrocephalus. The pathogenesis of IFV involves the obstruction of the fourth ventricle outflow and morphological or functional occlusion of the aqueduct^{5,16}. Fourth ventricle outflow obstruction results directly from hemorrhage or meningitis by occlusion of the outlets. Occlusion of the aqueduct related to transtentorial pressure gradient following lateral ventricular shunt placement. Because decreased supratentorial pressure by shunt placement in the lateral ventricle reduces the pressure keeping the aqueduct open.

Although the treatment options in the symptomatic IFV patients include open surgery, cerebrospinal fluid(CSF) diversion, and endoscopic surgery, treatment of IFV has been a difficult problem. Open surgery in the IFV includes fenestration of the fourth ventricle and aqueductal membrane to establish communication between supra- and infratentorial ventricular systems⁶. However, open surgery has been associated with high morbidity and risks of brain stem injury²². So, this technique was not adopted widely.

In the literature, the majority of the IFV have been treated with shunt procedure because this is simple and familiar method to general neurosurgeons. However, the morbidity rate of the placement of fourth ventricular catheters is significant^{1,12,15,22}. Most complications relates to the brain stem nuclei, oculomotor pathways, and cranial nerves. These complications occur at the time of catheter placement or by touching the floor of the fourth ventricle as fourth ventricle decreases in size.

Recent advances in neuroendoscopic surgery enable to perform endoscopic aqueductal plasty with a transluminal balloon in the IFV patients, but the results of aqueductal plasty alone have not always been favorable^{16,22}. Teo et al.²² reported that 16 patients with IFV and 4 patients of them were treated by endoscopic aqueductal plasty either with a stent (1 patient) or without (3 patient). In their report, one patient had intraoperative closure of the aqueduct, and in another patient, it closed 8 weeks after surgery. Because of their experience, they adopted the practice of always following aqueductal plasty with the placement of a stent. They mentioned that none of the stents in their series of the patients has migrated and placement of a stent after aqueductal plasty is the rule. Recently, Fritsch et al.⁸ analyzed 27 patients who underwent endoscopic aqueductoplasty or endoscopic interventriculostomy with or without a stent for the treatment of aqueductal stenosis(AS) or isolated fourth ventricle. They divide the patients into three groups and proposed the strategies of treatment. Group 1 consisted of 5 patients with membranous distal AS. Group 2 consisted of 4 patients with AS due to a periaqueductal tumor. Group 3 consisted of 18 patients with IFV. They reported

that patients with membranous distal AS were treated sufficiently with aqueductoplasty alone. But, in patients with IFV and a history positive for intraventricular hemorrhage or meningitis it is very unlikely that aqueductoplasty alone will stay open. Eight of 18 patients with IFV were initially treated with aqueductoplasty alone. Of them, six patients experienced restenosis. Five patients underwent aqueductoplasty with a stent. There was no revision in these five patients. Three patients underwent interventriculostomy without a stent and one of them experienced restenosis. Two patients underwent interventriculostomy with a stent and there was no revision. The high revision rate in this group has led to a change in treatment strategy toward initial stent placement. And they mentioned that patients with tumor-associated AS also should be performed stent placement. In our patient, since the patient had IFV with a history of meningitis, we chose the endoscopic aqueductoplasty and stent placement.

The key issue in the endoscopic approach to the aqueduct is that the aqueduct is not straight tube has a curved shape. If the burr hole is placed 5cm anterior to the coronal suture, surgeon comes in a straight line through the foramen of Monro to the entry of the aqueduct without stretching the fornices at the foramen of Monro. However, if the surgeon continues in a straight line, injury to the roof of the aqueduct, i.e. the tectal plate, will occur. Therefore, Schroeder et al.²⁰ recommended that surgeon should bend the tip of the catheter to enable passage through the aqueductal lumen into the fourth ventricle. And they also mentioned that the flexible scope is very helpful for perforating membranous occlusions, especially when they are located far distally within the aqueduct and cannot be observed with rigid rod-lens scope. Although aqueductoplasty is generally considered more risky than third ventriculostomy because of the surrounding delicate midbrain structures, there have been some reports on the endoscopic aqueductal stent placement as a safe procedure to recanalize occlusion of the aqueduct with no significant morbidity^{9,16,17,22}. In the literature, the most common complication was ophthalmoparesis, however, most were transient^{8,22}. In the present case with IFV, endoscopic aqueductoplasty and stent placement resulted in excellent outcome without any complication and morbidity.

Conclusion

We successfully treated the patient with IFV by endoscopic aqueductoplasty and stent placement. Neuroendoscopy as a procedure in hydrocephalus treatment has resolved many problems that exist with the shunt operation. We think that the combination of endoscopic aqueductoplasty and stent placement under direct visualization is an ideal method in the treatment of IFV.

References

1. Chai WX : Long-term results of fourth ventriculo-cisternostomy in complex versus simple atresias of the fourth ventricle outlets. *Acta Neurochir* 134 : 27-34, 1995
2. Coker SB : Bobble head doll syndrome due to trapped fourth ventricle and aqueduct. *Pediatr Neurol* 2 : 115-116, 1986
3. Coker SB, Anderson CL : Occluded fourth ventricle after multiple shunt revisions for hydrocephalus. *Pediatrics* 83 : 981-985, 1989
4. Collada M Jr, Kott J, Kline DG : Documentation of fourth ventricle entrapment by metrizamide ventriculography with CT scanning. Report of two cases. *J Neurosurg* 55 : 838-840, 1981
5. Colli BO, Pereira CU, Assirati Junior JA, Machado HR : Isolated fourth ventricle in neurocysticercosis : pathophysiology, diagnosis, and treatment. *Surg Neurol* 39 : 305-310, 1993
6. Foltz EL, DeFeo DR : Double compartment hydrocephalus-a new clinical entity. *Neurosurgery* 7 : 551-559, 1980
7. Foltz EL, Shurtleff DB : Conversion of communicating hydrocephalus to stenosis or occlusion of the aqueduct during ventricular shunt. *J Neurosurg* 24 : 520-529, 1965
8. Fritsch MJ, Kienke S, Mehdorn HM : Endoscopic aqueductoplasty : stent or not to stent? *Childs Nerv Syst* 20 : 137-142, 2004
9. Gaab MR, Schroeder HWS : Neuroendoscopic approach to intraventricular lesions. *J Neurosurg* 88 : 496-505, 1998
10. Harrison HR, Reynolds AF : Trapped fourth ventricle in coccidioidal meningitis. *Surg Neurol* 17 : 197-199, 1982
11. Hawkins JC III, Hoffman HJ, Humphreys RP : Isolated fourth ventricle as a complication of ventricular shunting. Report of three cases. *J Neurosurg* 49 : 910-913, 1978
12. Lee M, Leahu D, Weiner HL, Abbott R, Wisoff JH, Epstein FJ : Complications of fourth-ventricular shunts. *Pediatr Neurosurg* 22 : 309-313, 1995
13. Lourie H, Shende MC, Krawchenko J, Stewart DH Jr : Trapped fourth ventricle : a report of two unusual cases. *Neurosurgery* 7 : 279-282, 1980
14. Mickle JP, Friedman WA : Encysted fourth ventricle. *Surg Neurol* 16 : 150-153, 1981
15. Montes JL, Clarke DB, Farmer JP : Stereotactic transtentorial hiatus ventriculoperitoneal shunting for the sequestered fourth ventricle. Technical note. *J Neurosurg* 80 : 759-761, 1994
16. Oi S, Hidaka M, Honda Y, Togo K, Shinoda M, Shimoda M, et al : Neuroendoscopic surgery for specific forms of hydrocephalus. *Childs Nerv Syst* 15 : 56-68, 1999
17. Oka K, Yamamoto M, Ikeda K, Tomonaga M : Flexible endoneurosurgical therapy for aqueductal stenosis. *Neurosurgery* 33 : 236-243, 1993
18. Page LK, Tucci KA, Montalvo BM, Post MJD : Isolated fourth ventricular hydrocephalus. Clinical experience with seventeen cases. *Concepts Pediatr Neurosurg* 8 : 38-40, 1988
19. Ross D, Boland M : Three point skull clamp for infants. *Neurosurgery* 26 : 360, 1990
20. Schroeder HW, Oertel J, Gaab MR : Endoscopic aqueductoplasty in the treatment of aqueductal stenosis. *Childs Nerv Syst* 20 : 821-827, 2004
21. Scotti G, Musgrave MA, Fitz CR, Harwood-Nash DC : The isolated fourth ventricle in children : CT and clinical review of 16 cases. *AJR Am J Roentgenol* 135 : 1233-1238, 1980
22. Teo C, Burson T, Misra S : Endoscopic treatment of the trapped fourth ventricle. *Neurosurgery* 44 : 1257-1262, 1999