

## Anterior Cervical Instrumentation Using Intradiscal Cage with Integrated Plate

Kyoung-Rok Ahn, M.D., Kyeong-Sik Ryu, M.D., In-Bok Chang, M.D.,  
Byung-Moon Cho, M.D., Se-Hyuck Park, M.D., Sae-Moon Oh, M.D.

Department of Neurosurgery, Hallym University College of Medicine, Seoul, Korea

**Objective :** The retrospective study is undertaken to report clinical results of anterior cervical interbody fusion with an intradiscal cage with an integrated plate (PCB cervical plating system).

**Methods :** 38 patients underwent anterior cervical interbody fusion with PCB cervical plating system and followed 6~24 months. The authors investigated overall surgical results; clinical outcome, fusion rate, change of interspace height & lordotic angle, and complications.

**Results :** No complication was observed during the operation. Clinical improvement was identified in 34 cases (89.5%). Bone fusion observed in 44 out of 49 sites (90.7%). After operation, the interspace height increased from  $5.4 \pm 1.3$ mm to  $7.8 \pm 1.5$ mm and maintained  $7.4 \pm 1.1$ mm and, interspace angle went up from  $4.2 \pm 0.7^\circ$  to  $4.8 \pm 1.1^\circ$  and maintained  $4.6 \pm 0.9^\circ$ . The loosening of screw was observed in 6 cases, one of which had reoperation because of the expulsion of the device accompanied.

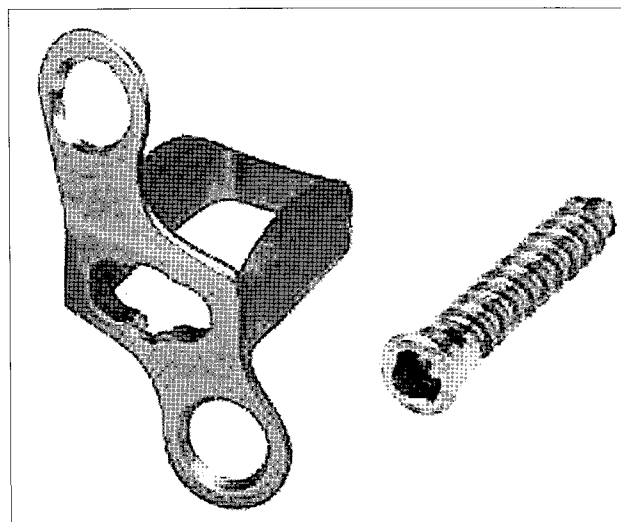
**Conclusion :** PCB cervical plating system could restore interbody height and lordosis in anterior cervical interbody fusion. But, if the insertion of the spacer is not precise, the frequencies of hardware failure are relatively high. It is considered necessary for the operator to be careful in the procedure.

**KEY WORDS :** Anterior cervical interbody fusion · Intradiscal cage · Degenerative cervical disease.

### Introduction

Mostly, the anterior approaches to cervical diseases is to apply interbody fusion and internal fixation using metal plate and screws compositely after decompressing the lesion<sup>1,2,7,12,25)</sup>. The disadvantage of conventional internal fixation with plate & screws system include the fracture or loosening of screws, the possibility of cord injury when using bi-cortical screws, long operation time, dysphagia and foreign body sensation in the anterior neck<sup>16,17,19,26)</sup>. To solve this problems, various internal fixation devices have been being introduced. Among them, PCB cervical plating system (SCIENT'X, Paris, France) (Fig. 1) was developed by grafting interbody cage system into existing cervical plating system. Because of simplicity to apply and mechanical stability, it is widely used by clinicians<sup>14,15,20,27)</sup>.

The authors analyzed the clinical results of PCB cervical plating system experienced in our institute and report the usefulness



**Fig. 1.** The PCB cervical system consists of a hollow intradiscal spacer with integrated plate. The upper convex part of spacer provides optimal contact with lower surface of vertebral body. Convergent mono-cortical screw allows rostrocaudal screw positioning.

• Received : May 31, 2005 • Accepted : August 12, 2005

• Address for reprints : Kyeong-Sik, Ryu, M.D., Department of Neurosurgery, Hallym University College of Medicine, 445 Gil-dong, Gangdong-gu, Seoul 134-701, Korea Tel : +82-2-2224-2238, Fax : +82-2-473-7387, E-mail : nsdoc35@hallym.or.kr

and limitations of the system along with the result of literature review.

### Materials and Methods

The subjects of this study were 38 patients selected from patients who visited our institute during the period from May 1998 to December 2001. They underwent anterior cervical interbody fusion using PCB cervical system for degenerative cervical disease, had full medical records, and could be followed up for over 6 months.

The subjects aged between 26~64 and 45.6 on the average. Among them, 29 were men and 9 were women. According to preoperative diagnosis, there were 29 cases of HNP, 6 cases of cervical myelopathy caused by the compression of bony spur and 3 cases of OPLL. In addition, 28 patients had a single level, 7 had two levels and 2 had three levels, so a total of 49 levels were operated. The period of follow-up was 6~24 months and 13.4 months on the average.

Operation was conducted according to standard Smith & Robinson method. Under general anesthesia, the patient was fastened at the supine position, his/her neck was extended to a certain degree. After skin incision and muscle dissection, the carotid artery was retracted to the lateral side and the esophagus and trachea to the medial side using Cloward retractor. After exposing of the anterior part of vertebra, the level of operation was confirmed with C-arm. The disc, bony spur, OPLL, etc. were removed under the microscope. The correct size of the PCB device was mounted on the spacer holder and inserted, and the system was fixed onto the upper and lower vertebral bodies using a screw for each. In order to raise the fusion rate, the authors collected 2~3cc of bone marrow from the patient's iliac bone, mixed it well with prepared Lubbock bone, and filled the mixture in the spacer.

The postoperative improvement of symptom was classified into four grades-excellent, good, satisfactory and poor-according to Odom's classification<sup>18)</sup>(Table 1). If improvement was excellent, good or satisfactory, we judged that the operation was successful. Fusion status was observed based on the result of lateral flexion/extension cervical radiography conducted at intervals of three months since operation. We determined successful bone fusion based on the absence of motion on flexion/extension, presence of sclerotic change between the inserted spacer and the

vertebral margin, increasement of bone density inside the spacer and absence of spinous process separation on dynamic overlay. We also measured interspace height and interspace angle according to the method proposed by Bishop et al.<sup>4)</sup> to examine changes in intervertebral height and in cervical lordotic angle (Fig. 2). We observed the manifestation of new symptoms and the occurrence of complications related to hardware and other complications during follow-up.

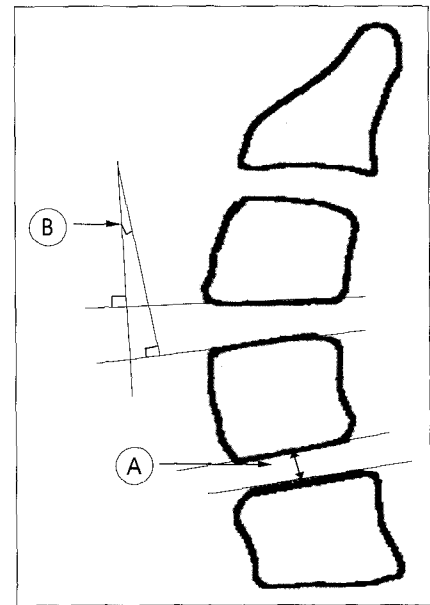


Fig. 2. Drawing showing how disc space height lordotic angle with serial radiography. A : Interspace height, B : Interspace angle.

### Results

The mean operation time by level was 1.6 hours and no complication was observed during the operation. Postoperative change in symptom was excellent in 15 cases, good in 13 and satisfactory in 6, so a total of 34 out of 38 cases (89.5%) were successful in operation and 4 (10.5%) were poor.

The average interspace height in the site of operation was  $5.4 \pm 1.3$ mm before operation, went up to  $7.8 \pm 1.5$ mm right after operation, and maintained  $7.4 \pm 1.1$ mm during follow-up. The average interspace angle was  $4.2 \pm 0.7^\circ$  before operation, went up to  $4.8 \pm 1.1^\circ$  right after operation, and maintained  $4.6 \pm 0.9^\circ$  during follow-up (Table 2). Bone fusion began to be observed from 6 months after operation and it was observed in 44 out of 49 sites, so the fusion rate was 90.7%. No particular symptom was found in 5 cases that had fusion failure as

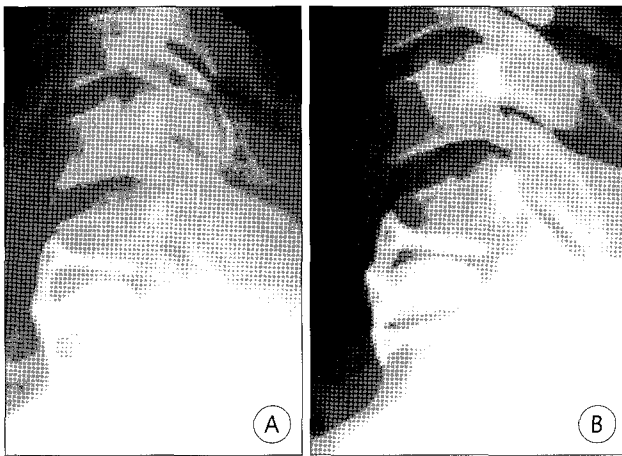
Table 1. Clinical outcome of the patients(Odom, et al<sup>18)</sup>)

Grade	Criteria	No. of patient
Excellent	Complete relief of symptom with full activity	15
Good	Partial relief of symptom with full activity	13
Satisfactory	Improvement but limitation of activity	6
Poor	No improvement or deterioration after surgery	4

Table 2. Interspace height & angle of preoperation, 1 day and 12 months after operation

Level(n=49)	Interspace height(mm)*			Interspace angle(°)*		
	Preop	1 day	12 mo	Preop	1 day	12 mo
C34(n=4)	4.9	6.9	6.4	3.5	4.3	4.1
C45(n=9)	5.6	7.7	7.3	4.1	4.7	4.4
C56(n=22)	5.5	8.1	7.5	4.3	5.1	4.8
C67(n=13)	5.3	7.5	7.2	4.2	4.5	4.2
C7T1(n=1)	4.8	7.4	6.9	4.0	4.5	4.4

\* Value expressed as average



**Fig. 3.** A : Plain lateral film taken on first day after operation shows inappropriate insertion of the spacer. B : Six months after operation, expulsion of the device is noted. The device is removed and the plating system is replaced through reoperation.

no evidence of bone fusion was observed even after 12 months. The loosening of screw was observed in 6 cases, one of which had reoperation because of the expulsion of the spacer accompanied (Fig. 3).

## Discussion

The operation methods of cervical disease are largely divided into the anterior and posterior approach according to access route. The posterior approach is disadvantageous in that the lesion on the anterior part of the spinal cord is not exposed sufficiently and there is the possibility of postoperative kyphosis and instability, so it is currently adopted limitedly<sup>24,28</sup>. On the other hand, the anterior approach minimizes the damage of structures supporting the stability of spine, provides safe access to the lesion on the anterior part of neural elements, and secure postoperative stability of spine through interbody fusion and internal fixation, so it is widely adopted today<sup>8,10,11,17</sup>.

Since it was first reported by Smith & Robinson, the operative technique of the anterior approach has been established as a method of decompression and interbody fusion by Cloward, Bailey & Badgley, etc<sup>3,9,29</sup>. Its early method that finished operation just with bone fusion using autologous iliac bone caused patients to experience frequent complications such as the subsidence of the fused part, the expulsion of the anterior or posterior part of the graft material, late instability and pseudoarthrosis<sup>8,24,25,28</sup>. Since Bohler et al.<sup>5</sup>, in order to prevent such complications, first reported internal fixation system using metal plates and screws in 1964, various types of fixation devices applied to anterior interbody fusion have been developed.

Cervical plating system is composed of metal plates fixed to the anterior part of the upper and lower vertebral body and mono- or bi-cortical screws that fix the plates onto the vertebral

body. The devices using bi-cortical screws have the risk of cord injury when inserting the screws. In addition, fracture or loosening of screws occurs frequently because load applied to the screws cannot be compensated for when the fused part is deformed by subsidence or other reasons<sup>19,23</sup>. Most devices using mono-cortical screws have a locking system to prevent expected loosening. Screws with such a locking system can be inserted relatively safely and easily and take less time in operation compared to bi-cortical screws but they are hard to be applied to patients with osteoporosis, trauma, etc<sup>12,21</sup>.

Cylindrical hollow-threaded cage, open-framed carbon fiber cage, titanium mesh cylinder, etc. that were developed by adapting interbody fusion cage, which had been used in the interbody fusion of the lumbar spine, for cervical spine can perform interbody fusion and fixation simultaneously and minimize postoperative foreign body sensation because they are “no profile” devices<sup>13,22</sup>. However, there are reports that the rate of fusion failure is relatively high because of micromotion between graft-endplate interfaces and the frequency of subsidence is higher than that in plated fusion<sup>6,13</sup>.

PCB cervical plating system used by the authors integrated plate and cage into a device in order to exploit the advantages of both cervical plating system and interbody cage system<sup>27</sup>. It consists of a hollow intradiscal spacer with an integrated plate. The upper part of the spacer has convex configuration for optimal contact. The cervical lordotic angle is maintained naturally after retaining the device within the disc space, and the diminution of the axial loading of the vertebral body applied to the screws is neutralized, minimizing the loosening or fractures. In addition, the metal plate integrated with the spacer protects the cord from injuries by preventing excessive insertion and postoperative retropulsion of the spacer.

Despite advantages mentioned above, hardware failures in actual PCB cervical plating system have been reported frequently. Samandouras et al.<sup>3</sup> conducted operation for 29 cases of degenerative cervical disease using PCB device and, after following up them for 8 months on the average, reported that there had been no hardware failure during the follow-up. In their 2-8 months' follow-up of 16 patients who had operation, Hwang et al.<sup>14</sup> also reported that there had been no complication related fixation device. However, these reports were all preliminary reports of short follow-up. On the contrary, Park et al.<sup>20</sup> reported that they observed 3 cases of screw loosening in 54 patients through follow-up of 15.5 months on the average, and Kim et al.<sup>15</sup> reported 2 cases of screw loosening in 28 patients through follow-up of 14 months on the average. In the authors' research on 38 patients, 6 cases of screw loosening were observed during follow-up of 13.4 months on the average. One of them had the expulsion of the device and severe foreign body sensation, so the device was removed and

the plating system was replaced through reoperation.

As stated above, the rate of hardware failures in PCB cervical plating system observed through long-term follow-up was 5~15%, which was higher than 7.7% in plating system<sup>17)</sup>, and 1.2~3.4% in interbody cage system<sup>13)</sup>. In PCB system that fixes only with a mono-cortical screw without locking system in the upper and lower vertebral body, the shape of the spacer with convex upper part must exactly agree with the shape of the empty space resulting from discectomy in order to minimize axial loading on the spacer. According to the authors' experience, however, if the vertebral body has been deformed severely by degenerative spondylosis, it was difficult to treat the fusion surface to be fit to the shape of the spacer and sometimes full insertion was hindered by the plate integrated to the anterior part. In this case, the effect of compensation for axial loading was not achievable and, as a result, failures such as screw loosening occurred frequently. Furthermore, as in the case where reoperation was conducted because of the expulsion of the spacer, it was highly possible that failure in fixing the plate was accompanied by the loosening of the spacer because the plate and the space were integrated into a device. In order to reduce hardware failures, accordingly, it is necessary to treat the upper & lower end plate of the fused part carefully in consideration of the size and shape of the vertebral body, to select PCB device of an appropriate size and to insert the device carefully so that it fits the intervertebral space, checking C-arm as much as possible.

It is reported that the fusion success rate of PCB cervical plating system is 71~72% using allograft<sup>15,20)</sup>. To raise the fusion rate, the authors collected 2~3cc of bone marrow from the patient's iliac bone during operation, mixed it fully with prepared Lubbock bone and filled it in the spacer and, as a result, the fusion rate was increased satisfactorily up to 90.7%. In PCB cervical plating system, it may be difficult to determine bone fusion only with plain cervical radiography because of the radio-opaque metal spacer. Thus computed tomography is sometimes used to check bone density inside the spacer but it is expensive and its result may be inaccurate<sup>13,15,20,27)</sup>. In order to get reliable results in determining bone fusion, the authors used plain cervical radiography to observe sclerotic change of fused surface, bone density inside the spacer and, at the same time, monitored the change of interspace between spinous processes in flexion / extension radiography.

In anterior cervical interbody fusion, the continuous maintenance of corrected intervertebral height and lordotic angle after operation is important in order to prevent late complications caused by the recompression of the nerve root<sup>8,17,28)</sup>. There are reports that interspace height and interspace angle were maintained successfully after operation in PCB cervical plating system<sup>14,15,20,27)</sup>. In the cases studied by the authors as

well, interspace height increased by 2.4mm on the average after operation and maintained the increase of around 2.0mm throughout the period of follow-up, and interspace angle increased by 0.4° on the average after operation and maintained the level without remarkable variation throughout the period of follow-up.

## Conclusion

The result of this study shows that anterior cervical instrumentation using PCB cervical plating system can maintain interspace height and lordotic angle with little subsidence. On the other hand, if the insertion is not precise, the frequencies of postoperative screw loosening and device expulsion are relatively high. Thus it is considered necessary for the operator to be careful in the procedure.

## References

1. Aebi M, Zuber K, Marchesi D : Treatment of cervical spine injuries with anterior plating. *Spine (Suppl 3)* 16 : 38-45, 1991
2. An HS, Coppes M : *The Cervical Spine*. 3rd ed. Philadelphia : Lippincott-Raven, 1998, pp653-658
3. Bailey RW, Badgley CE : Stabilization of the cervical spine by anterior fusion. *J Bone Joint Surg* 42A : 565-594, 1960
4. Bishop RC, Moore KA, Hadley MN : Anterior cervical interbody fusion using autogeneic and allogeneic bone graft substrate : a prospective comparative analysis. *J Neurosurg* 85 : 206-210, 1996
5. Bohler VJ : Sofort und Frubbehandlung traumatischer Querschnittlahmungen. *Z Orthop* 103 : 512-529, 1967
6. Cahil CW, Sonstein WS : Anterior cervical instrumentation. *Tech Neurosurg* 5 : 133-145, 1999
7. Caspar W, Baebier DD, Klara PM : Anterior cervical fusion and Caspar plate stabilization for cervical trauma. *Neurosurgery* 25 : 491-502, 1989
8. Clements DH, O'Leary PF : Anterior cervical discectomy and fusion. *Spine* 15 : 1023-1025, 1990
9. Cloward RB : The anterior approach for removal of ruptured disks. *J Neurosurg* 15 : 602-614, 1958
10. Dohn DF : Anterior interbody fusion for treatment of cervical disc disease. *JAMA* 197 : 897-900, 1966
11. Gore DR, Sepic SB : Anterior cervical fusion for degenerative or protruded discs. A review of one hundred forty six patients. *Spine* 9 : 667-671, 1984
12. Grubb MR, Currier BL, Shih JS : Biomechanical evaluation of anterior cervical spine stabilization. *Spine* 23 : 886-892, 1998
13. Hacker RJ, Cauthen JC, Gilbert TJ, Griffith SL : A prospective randomized multicenter clinical evaluation of an anterior cervical fusion cage. *Spine* 25 : 2646-2654, 2001
14. Hwang YH, Kim HJ, Lee DH, Lee SH, Kim HK, Kang CG, et al : Anterior cervical fusion with the PCB Instrumentation(cervical plate cage system) in degenerative cervical disease. *J Korean Neurosurg Soc* 28 : 1732-1737, 1999
15. Kim SH, Kim HJ, Kang JK, Doh JO, Lee CD : Clinical experience of anterior cervical interbody fusion with the PCB system. *J Korean Neurosurg Soc* 30 : 1170-1176, 2001
16. Lowery GL, McDonough RF : The significance of hardware failure in anterior cervical plate fixation. Patients with 2- to 7-year follow-up. *Spine* 23 : 181-186, 1998
17. Lowery GL, Reuter MW, Sutterlin C : Anterior cervical interbody arthrodesis with plate stabilization for degenerative disc disease. *Orthop Trans* 18 : 1273-1278, 1994
18. Odom GL, Finney W, Woodhall B : Cervical disc lesions. *JAMA* 166 : 23-28, 1958
19. Paramore CG, Dickman CA, Sonntag VKH : Radiographic and clinical follow-up review of Caspar plates in 49 patients. *J Neurosurg* 84 : 957-961, 1996

20. Park JH, Oh SH, Yi HJ, Kim JH, Kim YS, Ko Y : PCB instrumentation with lubroc bone in anterior cervical interbody fusion. *J Korean Neurosurg Soc* 30 : 1284-1290, 2001
21. Pitzen T, Wilke HJ, Caspar W, Claes L, Steudel WI : Evaluation of a new monocortical screw for anterior cervical fusion and plating by a combined biomechanical and clinical study. *Eur Spine J* 8 : 382-387, 1999
22. Ray CD : Threaded titanium cages for lumbar interbody fusions. *Spine* 22 : 667-679, 1997
23. Richter M, Wilke HJ, Kluger P, Claes L, Puhl W : Biomechanical evaluation of a newly developed monocortical expansion screw for use in anterior internal fixation of the cervical spine. In vitro comparison with two established internal fixation systems. *Spine* 24 : 207-212, 1999
24. Robinson RA : Anterior and posterior cervical spine fusions. *Clin Orthop* 35 : 34-62, 1964
25. Robinson R, Walker AE, Ferlic D : The results of anterior interbody fusion of the cervical spine. *J Bone Joint Surg* 44A : 1569-1587, 1962
26. Ryken TC, Clausen JD, Traynelis VC, Goel VK : Biomechanical analysis of bone mineral density, insertion technique, screw torque, and holding strength of anterior cervical plate screws. *J Neurosurg* 83 : 325-329, 1995
27. Samandouras G, Shafafy M, Hamlyn PJ : A new anterior cervical instrumentation system combining an intradiscal cage with an integrated plate : an early technical report. *Spine* 26 : 1188-1192, 2001
28. Saunders RL, Wilson DH : The surgery of cervical disc disease : new perspectives. *Clin Orthop* 146 : 119-127, 1980
29. Smith GW, Robinson RA : The treatment of certain cervical-spine disorders by anterior removal of the intervertebral disc and interbody fusion. *J Bone Joint Surg* 40A : 607-624, 1958

## Commentary

The authors provided a valuable information for cervical instrumentation using intradiscal cage with integrated

plate like PCB cervical plating system. This article is emphasized for prevent hardware failures to treat the upper & lower end plate of the fused parts of the vertebral body, to select the device of an appropriate size and to insert the device into intervertebral space with proper depth.

Among authors' 38 cases, the loosening of screw was observed in 6 cases and one patient had wound revision for removal of the device. The rate of hardware failure is relatively not little. But this article is also of great value for discussion to problems of the device and bone fusion after long-term follow-up compare to other reports about PCB cervical plating system.

In recent years the kinds and use of frequency of spinal instruments are rapidly increased. However we have to think about the plate and screw fixation for single level discectomy in the degenerative cervical disc diseases without instability is reasonable procedure or not, because all spinal instruments has possibility of hardware failure.

Won-Han Shin, M.D., Ph.D.  
Department of Neurosurgery,  
Soonchunhyang University Bucheon Hospital