

Efficacy of Intraoperative Facial Electromyographic Monitoring in Patients with Hemifacial Spasm

Hae-Kwan Park, M.D., Kyung-Sool Jang, M.D., Kyung-Jin Lee, M.D.,
Hyung-Kyun Rha, M.D., Won-Il Joo, M.D., Moon-Chan Kim, M.D.

Department of Neurosurgery, The Catholic University of Korea, St. Mary's Hospital, Seoul, Korea

Objective : Hemifacial spasm has characteristic and specific electrophysiological finding, lateral spread response(LSR). We study the correlation between change of lateral spread response during microvascular decompression(MVD) and clinical outcome after MVD.

Methods : Sixty two patients with hemifacial spasm who were treated with microvascular decompression from March 2000 to February 2003 were included in this study. The monitoring of intraoperative facial electromyography(EMG) and brain stem auditory evoked potential were performed.

Results : In 28 (44.7%) patients, there was persistence of lateral spread response after vascular decompression in root exit zone of facial nerve. Among these 28 patients, 9 had mild hemifacial spasm at discharge. Three out of 34 patients who had intraoperative disappearance of lateral spread response after MVD had mild hemifacial spasm. But Both groups, disappearance of LSR (Group I), and persistence (Group II) had only 2 patients with mild hemifacial spasm, and 5 patients at 3 months, respectively.

Conclusion : Although intraoperative EMG monitoring is very useful in assessing the efficacy of MVD, the clinical outcome of MVD in patient with hemifacial spasm does not always correlate with EMG finding. The prognostic value of intraoperative LSR monitoring in the long-term results is questionable.

KEY WORDS : Hemifacial spasm · Microvascular decompression · Electromyography · Lateral spread response.

Introduction

Hemifacial spasm is characterized by unilateral paroxysmal involuntary tonic clonic contraction occurring in the muscle innervated by facial nerve^{2,3}. Over the last three decades, microvascular decompression(MVD) has proved to be a valuable procedure to definitely cure the disease^{2,7}. Although, in most cases there will be no doubt regarding the diagnosis, neurophysiological studies may confirm diagnosis by demonstrating both spontaneous electrical activity and presence of the lateral spread response(LSR), which can be elicited by stimulating the one branch of facial nerve and recorded from the muscles innervated by other facial nerve branches. This phenomenon were presumed to be related to ephaptic transmission at the lesion site alone, or in combination with motor nucleus hyperactivity¹¹.

The LSR can be recorded preoperatively and intraoperatively in most patients. In many of them, although, the lateral spread

response disappears after offending vessel is removed from the compression site of facial nerve, complete disappearance of response is not always achieved in spite of effective decompression⁹.

The aim of this study is to evaluate efficacy of intraoperative electromyography(EMG) monitoring during MVD, and correlation of intraoperative finding of EMG and clinical outcome.

Materials and Methods

Patient population

Patients consisted of 62 consecutive cases who underwent MVD for hemifacial spasm in our hospital from march 2000 to february 2003. There were 17 males and 45 females with a mean age of 55.3 years (range 27~73 years). The preoperative symptom duration ranged from 6 months to 20 years with a mean duration of 4.2 years. All patients underwent preoperative magnetic resonance images(MRI) to rule out other disease, and electromyographic study to confirm hemifacial spasm.

• Received : July 13, 2005 • Accepted : September 23, 2005

• Address for reprints : Won-Il Joo, M.D., Department of Neurosurgery, The Catholic University of Korea, St. Mary's Hospital, 62 Yeouido-dong, Yeongdeungpo-gu, Seoul 150-713, Korea Tel : +82-2-3779-2248, Fax : +82-2-786-5809, E-mail : jwi@catholic.ac.kr

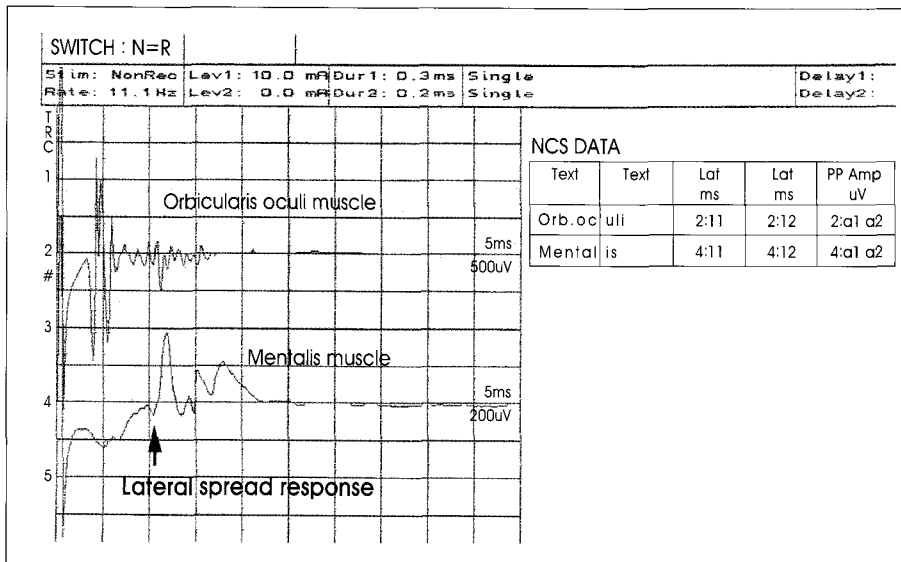


Fig. 1. Preoperative electromyographic monitoring showing lateral spread response. Lateral spread response with a latency of about 10 msec can be recorded from mentalis muscle innervated by the inferior branch of the facial nerve when the superior branch innervating orbicularis oculi muscle is stimulated.

LSRs were present in all patients in preoperative EMG study (Fig. 1). They were operated in our neurosurgical department and followed for more than 3 months. Microvascular decompression was performed through retrosigmoid approach in the lateral decubitus position.

The stimulating needle electrode was inserted intradermally over the zygomatic branch of facial nerve and recording needle electrodes into the mentalis muscle. Intraoperative electromyographic recording from mentalis muscle during stimulation of zygomatic branches of facial nerve using evoked potential system (0.1 msec pulse wave of intensity 5~15 mA) (Evoked potential system EP/EMG, Viking IV D, Nicolet, 1996) was established. The electrophysiological study was done preoperatively, intraoperatively in all cases and at least 3 months in some cases after the MVD.

Operative technique

A small suboccipital retromastoid craniotomy was performed on the patient in the lateral decubitus position. The exit zone of the facial nerve and involved vessel were visualized from the inferolateral direction through a space between the flocculus and the IXth nerve. At least, a compressing artery was found in all patients. It was dissected and transposed, then kept apart by interposing teflon patches. Intraoperative monitoring of lateral spread response and brainstem auditory evoked potentials (BAEP) using Evoked potential system (Nicolet) were performed by EMG physician. Monitoring was intermittent at the beginning of procedure, then continuous during the main steps of the procedure. No muscle relaxant was given except a single dose on induction of anaesthesia.

Results

Offending vessels by operative findings

The anterior inferior cerebellar artery was the most common offender, followed by the posterior inferior cerebellar artery. Only one vessel was responsible for 72%, while other cases were offended by more than two vessels (Table 1).

Intraoperative EMG monitoring and clinical outcome

The present study divided the 62 cases of hemifacial spasm into two groups, according to LSR. Group I included 34 (55.2%) patients with intraoperative disappearance of LSRs after decompression

(Fig. 2). Group II included 28 (44.7%) patients with persistence of LSRs despite decompression (Fig. 3). Patients with no complication were discharged on the 12th postoperative days and followed up for at least 3 months. At discharge, there were persistence of hemifacial spasm in 3 patients (Group I), and 9 (Group II). The intraoperative disappearance of LSRs correlated with disappearance of the spasm at discharge (p=0.027, Fisher's Exact Test).

The subjective and objective spasm assessment were performed three months after the operation to compare preoperative and postoperative states. Even though 3 months were insufficient period to assess of the prognosis of hemifacial spasm, authors focused on efficacy of intraoperative EMG in microvascular decompression. Of the 34 patients in whom LSR disappeared during surgery (Group I), 32 were free from hemifacial spasm within 3 months. Of the 28 patients in whom LSR did not disappear during surgery (Group II), only five had mild hemifacial spasm and LSR at 3 months. Therefore,

Table 1. Causative vessel of facial nerve compression

Offender	Patients	
	Number	%
AICA	27	43.5
PICA	18	29
AICA + PICA	8	13
AICA + VA	4	6.4
PICA + VA	2	3.3
other (unnamed small artery or vein)	3	4.8
Total	62	100

AICA : Anterior inferior cerebellar artery, PICA : Posterior inferior cerebellar artery, VA : Vertebral artery

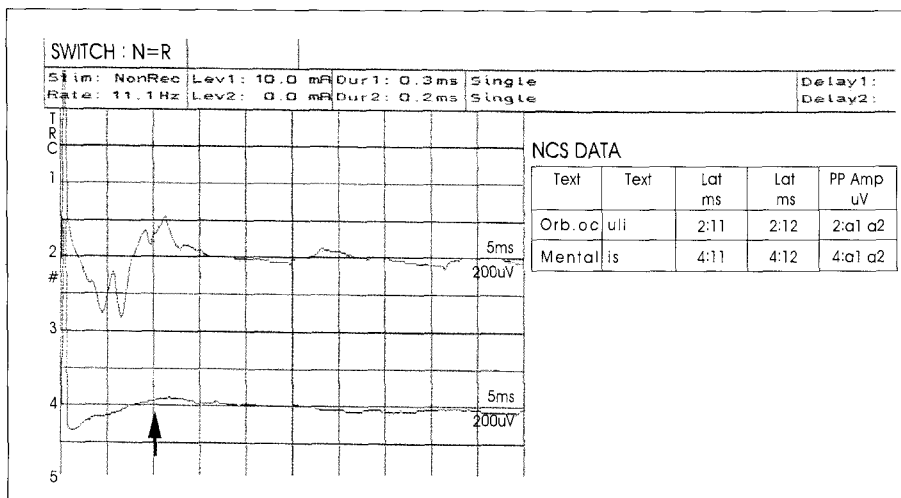


Fig. 2. Intraoperative electromyographic monitoring showing complete disappearance of lateral spread response after decompression of offending vessels (Group I).

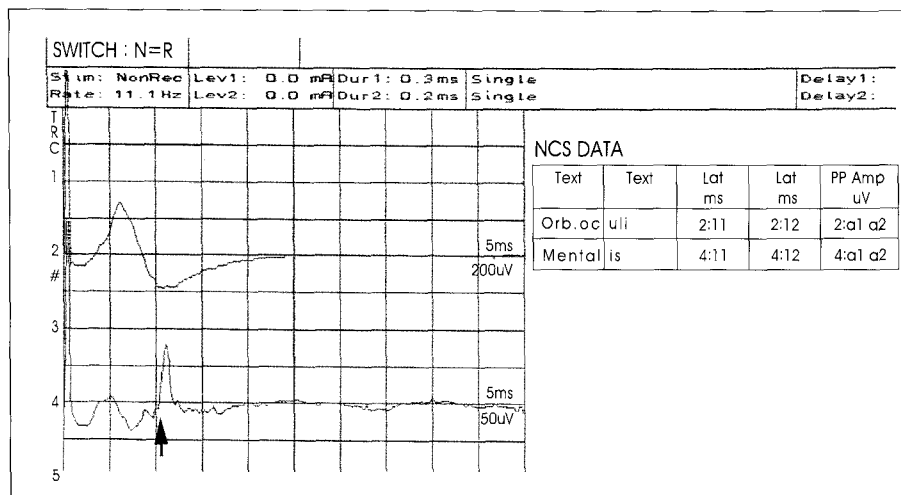


Fig. 3. Intraoperative electromyographic monitoring showing persistence of lateral spread response despite decompression of offending vessels (Group II).

the intraoperative EMG findings (the change of LSRs) did not always correlate with prognosis of hemifacial spasm ($p=0.228$, Fisher's Exact Test).

Discussion

Microvascular decompression of facial nerve has been established as surgical treatment in patients with hemifacial spasm. In most large series of MVD operations for HFS, reported rates of complete relief of HFS following MVD have ranges from 60% to 93.2%^{1,15}. These results suggested that vascular compression in root exit zone of facial nerve might play a major role in its pathology. But treatment failure such as recurrence and persistence of spasm has been reported, even if decompression of root exit zone was performed by experienced neurosurgeon. Therefore, the exact mechanism has not

yet been sufficiently explained¹⁴.

In 1984, Moller and Janetta presented electrophysiological characteristic and specific findings of hemifacial spasm, abnormal muscle response (lateral spread response) recorded in evoked facial EMG. Lateral spread response (LSR) with a latency of about 10 msec could be recorded from one muscle innervated by the superior branch of the facial nerve when the inferior branch was stimulated or inversely¹³. Several authors suggested that intraoperative monitoring of LSR is useful to identify offending vessels and to confirm whether facial nerve has been decompressed or not^{4,6,19}. And intraoperative EMG monitoring has been reported to be helpful in accurately identifying the causative vessel and lowering the complication rate during MVD¹⁸. Therefore, this monitoring may provide a useful method of confirming complete facial nerve decompression.

But in our study, although decompression of facial nerve was followed by relief of the spasm, lateral spread response was noted in 19 out of 28 patients at the end of MVD. This suggests that intraoperative EMG monitoring is not

always reliable to determine whether decompression is complete or not. It is interesting that not only arterial compression of the facial nerve but also demyelination of the facial nerve experimentally affected electrophysiological abnormal muscle responses in the report by Kuroki and Moller¹⁰. And clinical outcome did not always correlate with electrophysiological finding such as change of lateral spread response.

As shown in the literatures, in our study, immediate postoperative improvement of hemifacial spasm did not correlate with intraoperative change of LSR. In 34 (Group I) out of 62, the immediate disappearance of LSR after decompression of offender results from disappearance of spontaneous or ectopic excitation by the pulsatile compressive force of offending vessel^{8,12,17}. In Group II, 28 presented lateral spread response after MVD. This phenomenon could be probably due to demyelination or micro-injury of facial nerve on compression

site by offending vessel⁵⁾. Four out of 9 who remained postoperative immediate hemifacial spasm disappeared LSR and spasm at postoperative 12th days. The delayed resolution of LSR probably could be attributed to the complete regeneration of micro-injury of facial nerve in contact site or the gradual stabilization of facial motor nucleus, which are time-consuming process^{8,16)}. Once the vascular decompression was performed, motor nucleus hyperactivity starts to decline slowly to normalize over a few months to a few years in some patients. At postoperative 3 months, 32 in Group I and 23, Group II showed complete resolution of spasm. Consequently, continuous improvement of hemifacial spasm with MVD was observed. Kiya et al⁹⁾. suggested that hemifacial spasm has been caused by total phenomenon between facial nerve and its motor nucleus. Therefore it is unreliable that improvement of spasm after surgery is to be predicted only by the electrophysiological recording of the abnormal muscle response.

Conclusion

In our study, intraoperative EMG monitoring is very useful in assessing the efficacy of MVD and in predicting the prognosis of hemifacial spasm, if lateral spread response immediately disappears after vascular decompression. Because surgeons have confidence that root exit zone completely has been decompressed in that situation. And also if surgeon convinced that decompression has been performed effectively and thoroughly, clinical outcome achieved good results, even if persistence of LSR. Therefore, the clinical outcome of patients does not always correlate with lateral spread response. The prognostic value of intraoperative LSR monitoring in the long-term results is questionable.

References

1. Barker FG, Jannetta PJ, Bissonette DJ, Shields PT, Larkins MV, Jho HD : Microvascular decompression for hemifacial spasm. *J Neurosurg* 82 : 201-210, 1995
2. Choi CR, Rha HK, Lee KJ, Cho KK, Park SC, Park HK, et al : Microvascular decompression for hemifacial spasm. *J Korean Neurosurg Soc* 28 : 493-497, 1999
3. Goto Y, Matsushima T, Natori Y, Imanura T, Tobimatsu S : Delayed effects of the microvascular decompression on hemifacial spasm : a retrospective study of 131 consecutive operated cases. *Neurol Res* 24 : 296-300, 2002
4. Haines SJ, Torres F : Intraoperative monitoring of the facial nerve during decompressive surgery for hemifacial spasm. *J Neurosurg* 74 : 254-257, 1991
5. Hatem J, Sindou M, Vial C : Intraoperative monitoring of facial EMG responses during microvascular decompression for hemifacial spasm. Prognostic value for long-term outcome : a study in a 33-patient series. *Br J Neurosurg* 15 : 496-499, 2001
6. Isu T, Kamada K, Mabuchi S, Kitaoka A, Ito T, Koiwa M, et al : Intraoperative monitoring by facial electromyographic responses during microvascular decompressive surgery for hemifacial spasm. *Acta Neurochir (Wien)* 138 : 19-23, 1996
7. Jannetta PJ, Abbassy M, Maroon JC, Ramos FM, Albin MS : Etiology

- and definitive microsurgical treatment of hemifacial spasm, operative technique and results in patients. *J Neurosurg* 47 : 321-328, 1977
8. Kim P, Fukushima T : Observations on synkinesis in patients with hemifacial spasm. Effect of microvascular decompression and etiological consideration. *J Neurosurg* 60 : 821-827, 1984
9. Kiya N, Bannur U, Yamauchi A, Yoshida K, Kato Y, Kanno T : Monitoring of facial evoked EMG of hemifacial spasm : a critical analysis of its prognostic value. *Acta Neurochir (Wien)* 143 : 365-368, 2001
10. Kuroki A, Moller AR : Facial nerve demyelination and vascular compression are both needed to induce facial hyperactivity : a study in rats. *Acta Neurochir (Wien)* 126 : 149-157, 1994
11. Moller AR : Pathophysiology of hemifacial spasm. In : Sindou M, Keravel Y, Moller AR (eds) *Hemifacial spasm. A multidisciplinary approach*. Wien, springer-Verlag, 1997, pp51-62
12. Moller AR, Jannetta PJ : Physiological abnormalities in hemifacial spasm studied during microvascular decompression operations. *Exp Neurol* 93 : 584-600, 1986
13. Moller AR, Jannetta PJ : On the origin of synkinesis in hemifacial spasm : results of intracranial recordings. *J Neurosurg* 61 : 569-576, 1984
14. Mooij JJ, Mustafa MK, van Weerden TW : Hemifacial spasm : intraoperative electromyographic monitoring as a guide for microvascular decompression. *Neurosurg* 49 : 1365-1370, 2001
15. Nagahiro S, Takada A, Matsukado Y, Ushio Y : Microvascular decompression for hemifacial spasm. Patterns of vascular compression in unsuccessfully operated patients. *J Neurosurg* 75 : 388-392, 1991
16. Saito S, Moller AR : Chronic electrical stimulation of the facial nerve causes signs of facial nucleus hyperactivity. *Neurol Res* 15 : 225-231, 1993
17. Sander DB : Ephaptic transmission in hemifacial spasm : A single-fiber EMG. *Muscle Nerve* 12 : 690-694, 1989
18. Shin JC, Kim YC, Park CI, Chung UH : Intraoperative monitoring of microvascular decompression in hemifacial spasm. *Yonsei Med J* 37 : 209-213, 1996
19. Tan PC, Hsu JC, Chung Hs, Chen YC, Chang CN : Abnormal muscle response in microvascular decompression of hemifacial spasm. *Chinese Med J* 48 : 333-338, 1991

Commentary

The authors report a retrospective analysis of relation between intraoperative EMG monitoring of the lateral spread response(LSR) and results of microvascular decompression(MVD) of the facial nerve in hemifacial spasm(HFS) in 62 consecutive patients.

There has been some debate over the reliability of LSR as an indicator of postoperative outcome. This study shows that intraoperative monitoring of the LSR has limited value for predicting the outcome of HFS in these cases.

Although intraoperative monitoring of LSR is useful in MVD for HFS, I agree with the authors that the findings of LSR monitoring during MVD for HFS do not always perfectly reflect postoperative outcome. Like the authors of this article, most studies suggested that immediate disappearance of LSR at the end of surgery indicate a high likelihood of postoperative relief from HFS. However, persistence of LSR does not mean that the MVD will not be efficacious^{1,3)}. Because the causative factors of HFS are not only the mechanical pulsations in root exit zone but also focal demyelination and hyperactivity of the facial motor nucleus that need a sufficiently long time to heal and slow down²⁾.

I think that this article may offer helpful contribution to the interpretation of the intraoperative facial EMG monitoring in the MVD for HFS.

Chang Hwa Choi, M.D.
Department of Neurosurgery, Pusan National University

References

1. Hatem J, Sindou M, Vial C : Intraoperative monitoring of facial EMG responses during microvascular decompression for hemifacial spasm. Prognostic value for long-term outcome : a study in a 33-patient series. **Br J Neurosurg** 15 : 496-499, 2001
2. Møller AR : Pathophysiology of hemifacial spasm, in Sindou M, Keravel Y, Møller AR(eds) : **Hemifacial spasm : A Multidisciplinary Approach**. Wien, Springer-Verlag, 1997, pp51-62
3. Yamashita S, Kawaguchi T, Fukuda M, Watanabe M, Tanaka R, Kameyama S : Abnormal muscle response monitoring during microvascular decompression for hemifacial spasm. **Acta Neurochir (Wien)** 147 : 933-938, 2005