

## A Case of Rhabdoid Meningioma

Jung Ho Han, M.D.,<sup>1</sup> Ho Jun Seol, M.D.,<sup>2</sup> Dong Gyu Kim, M.D.,<sup>1</sup> Hee-Won Jung, M.D.<sup>1</sup>

*Department of Neurosurgery,<sup>1</sup> Seoul National University College of Medicine, Clinical Research Institute, Seoul, Korea  
Department of Neurosurgery,<sup>2</sup> Kangwon National University College of Medicine, Chuncheon, Korea*

Rhabdoid meningioma is an uncommon meningioma variant, which was initially described in 1998 by Perry et al.<sup>13</sup>. It is classified as a variant corresponding to grade III in the recent World Health Organization(WHO) classification of tumors of the nervous system<sup>6</sup>, because of its unique histopathological features and its highly aggressive clinical course<sup>13</sup>. To date there were still a lot of arguments about their developmental patterns and the treatment strategy especially for rhabdoid meningiomas lacking other histological features of malignancy. Although the exact causes of rhabdoid transformation of a benign meningioma are unknown, malignant transformation long duration after surgical resection under an underlying predilection for malignancy is suggested in our case. And we suggest that any histological rhabdoid features in recurrent meningiomas or even in primary cases seem to indicate the malignant clinical course and the need for aggressive treatments, because transformation from a benign or atypical one to a malignant one seems to occur at last.

**KEY WORDS :** Meningioma · Rhabdoid · Recurrent.

### Introduction

Since Beckwith and Palmer<sup>1</sup> introduced the term 'rhabdoid tumor' in 1978 in connection with reference a subgroup of childhood malignant renal tumors, many tumors with a rhabdoid morphology have been reported in various sites, including the central nervous system(CNS)<sup>6</sup>. In the various reports, a series of meningiomas with rhabdoid differentiation were described with regard to histological and clinical features<sup>3,6,13</sup>.

The WHO classification of CNS tumors published in 2000, includes a number of meningioma subtypes, many of which are descriptive and of no prognostic significance<sup>7</sup>. This classification treats rhabdoid meningiomas as a distinct subtype due to their adverse biologic behavior and high rates of recurrence<sup>2,7</sup>.

However, to date there were still a lot of arguments about their developmental patterns and the treatment strategy especially for rhabdoid meningiomas lacking other histological features of malignancy.

We report a case of a rhabdoid meningioma occurring 11 years after the first surgery, which recurred or regrew despite several surgical gross total removals, radiation therapy, chemotherapy and gamma-knife radiosurgery. The changes of

the clinico-pathologic features and the immunohistochemical profiles of the tumor are described.

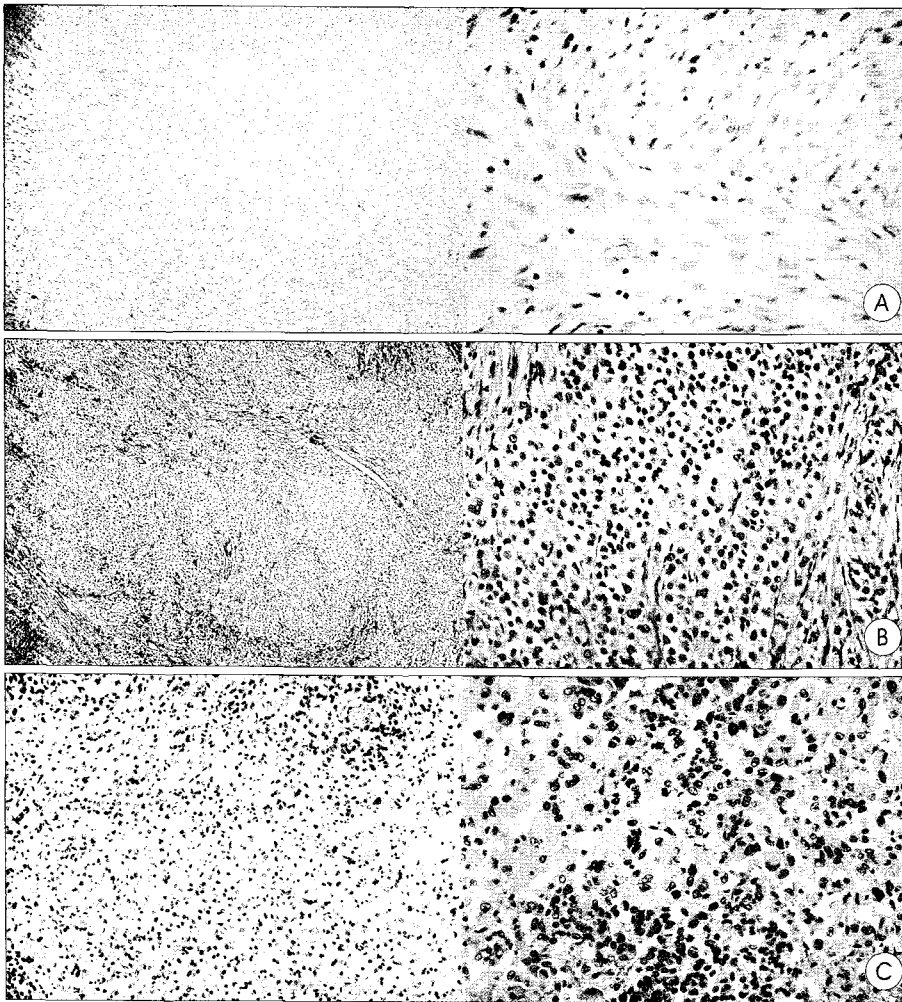
### Case Report

In September 1999, a 32-year-old woman was admitted to our clinic for the evaluation of a progressive headache and visual seizures (sparkling colored circles). Eleven years previously, she had undergone gross total resection of a brain tumor in left parieto-occipital area at other clinic; the pathologic diagnosis had been a fibrous meningioma, which had had no evidences of malignancy (Fig. 1A). Upon admission, a neurological examination revealed right homonymous hemianopsia, and an MRI examination identified an extra-axial, well-enhancing falcine tumor with a dural tail sign in the left parieto-occipital area (Fig. 2A). She underwent index surgery, and a large mass with dural attachment was found and totally removed (Simpson grade I).

The tumor cells had the typical cytologic features of rhabdoid cells, i.e., sheets of cells with variably abundant eosinophilic cytoplasm, eccentric nuclei, and hyaline; mitotic activity was 7 per 10 high power fields(HPF). By immunohistochemical staining, glial fibrillary acidic protein was entirely negative,

• Received : July 12, 2005 • Accepted : August 1, 2005

• Address for reprints : Hee-Won Jung, M.D., Department of Neurosurgery, Seoul National University College of Medicine, Clinical Research Institute, 28 Yeongeong-dong, Jongno-gu, Seoul 110-744, Korea Tel : +82-2-2072-2355, Fax : +82-2-744-2339, E-mail : hwnjung@snu.ac.kr



**Fig. 1.** A : The tumor cells show typical features of a fibrous meningioma (H&E, x100 and x400). B : The tumor cells have the typical cytologic features of rhabdoid cells, i.e., sheets of cells with variably abundant eosinophilic cytoplasm, eccentric nuclei, and hyaline; mitotic activity was 7 per 10 high-powered field (HPF) (H&E, x40 and x200). C : The tumor containing diffuse necrotic portions and focal hemorrhagic regions. The tumor cells have typical rhabdoid features, increased mitotic activity, 10 per 10 HPF (H&E, x100 and x200).

but vimentin was positive, and the MIB-1 labeling index(LI) was 1%. The pathological diagnosis made at the second operation was rhabdoid tumor (Fig. 1B).

Fractionated radiation therapy to the whole brain was performed with a total radiation dose of 5,400cGy, and this was followed by chemotherapy using the BCNU regimen.

In September 2000 after the fifth cycle of a scheduled six cycles of chemotherapy, her visual seizure redeveloped, which had diminished after the second surgery. An MRI examination revealed a well enhancing small mass, implying local recurrence of the tumor at the previous site (Fig. 2B). Gamma-knife radiosurgery was performed 12 months after the second surgery. A marginal dose of 13Gy to the 50% isodose line was delivered to the tumor.

In July 2001, despite these treatments, a follow-up MRI nine months after radiosurgery identified a mass outgrowing the

boundary occupied by the tumor before the second surgery (Fig. 2C). A third surgical procedure was performed. On this occasion no clear margin was observed between the tumor and the brain parenchyma. The tumor contained diffuse necrotic portions and focal hemorrhagic regions. The tumor had the same rhabdoid features as the previous surgical specimens but had increased mitotic activity, 10 per 10 HPF (Fig. 1C), and an increased rate of MIB-1 LI, 20% of tumor cells.

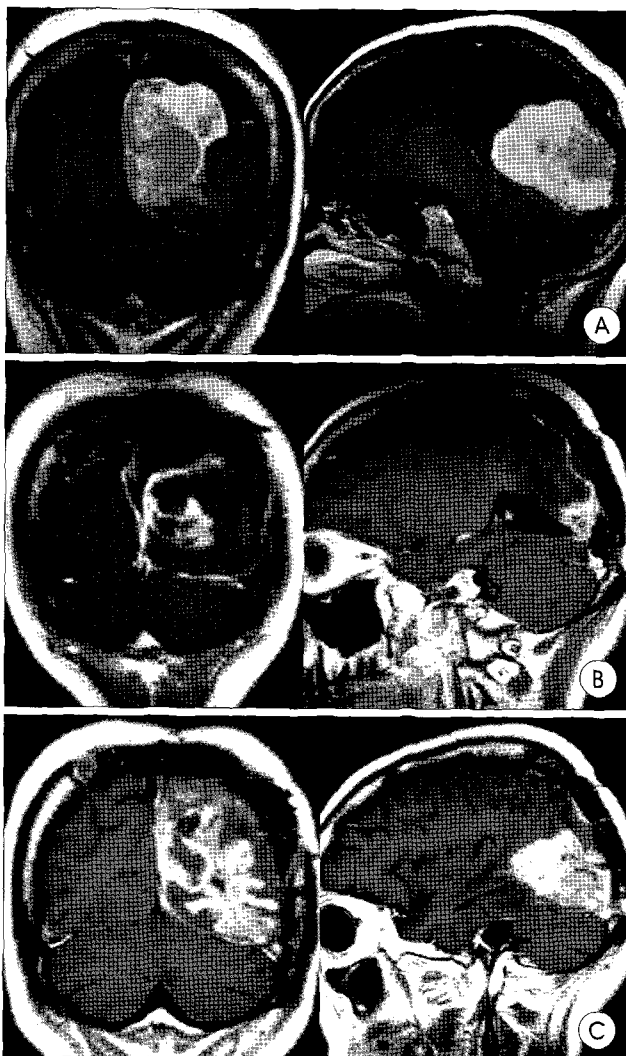Eight months after the third operation the patient died.

## Discussion

Although meningiomas are well-known entities with frequent histological variants, rhabdoid meningioma is an uncommon meningioma variant. It has been suggested that rhabdoid meningiomas are highly aggressive tumors and that the rhabdoid phenotype represents a marker of malignant transformation in meningiomas<sup>13</sup>. Therefore, it has been classified as a grade III malignancy in the 2000 WHO classification<sup>8</sup>. Histologically, rhabdoid meningiomas usually exhibit signs of anaplasia, high mitotic activity, and markedly increased MIB-1 LI, a marker of cell proliferation<sup>9</sup>.

In addition, the cells are abundantly vimentin-positive, whorled with a fibrillary cytoplasm<sup>7</sup>. EMA is variably positive in conventional and in rhabdoid meningiomas, but GFAP, S-100, desmin, and myogenin are universally negative<sup>6-8,13</sup>. And one interesting feature of rhabdoid meningiomas is that in a significant number of cases, the rhabdoid cells appear after initial recurrence<sup>9</sup>.

However, in the recent literatures, reports of rhabdoid meningiomas have included cases having the rhabdoid cells in the primary meningioma and cases with a range of histological atypia from apparently benign to frankly malignant<sup>6,13</sup>. So there are debates about their developmental patterns and the treatment strategy especially for histologically benign rhabdoid meningiomas.



**Fig. 2.** A : An extra-axial well-enhancing falcine tumor with a dural tail sign in the left parieto-occipital area is identified in September 1999, 11 years after the first surgery. B : An enhancing small mass, implying local recurrence of the tumor at the previous site, is seen 12 months after the second surgery. C : The mass outgrowing the boundary occupied by the tumor before gamma knife radiosurgery with lobulating irregular margins, 10 months after the second surgery.

In our case, initial pathologic diagnosis was a benign fibrous meningioma, but rhabdoid features were evident at the second surgery (the first at our hospital), 11 years after the first operation, when the mitotic activity was moderate and the MIB-1 LI was low, only 1% of tumor cells. The pathologic diagnosis was a rhabdoid tumor at that time before rhabdoid meningioma was classified as a malignant variant in the recent WHO classification. However, highly proliferative typical rhabdoid features of malignancy were present at the third surgery. The more the tumor was treated, the more malignant it seemed to be.

These histo-pathological changes show that transformation from a benign meningioma to a rhabdoid phenotype after long duration, and which was finally transformed to a mali-

gnant rhabdoid form. Also that changes seem to be associated with the aggressive clinical behavior of a tumor<sup>7)</sup>. The exact causes of rhabdoid transformation of a benign meningioma are currently unknown. However, the reported strongest association (odds ratio 4.33; 95% confidence interval 2.06-9.10) with head trauma occurring between 10 and 19 years before the diagnosis of the meningioma<sup>14)</sup> and tumor growth at operative sites in an experimental rat model with an underlying predilection for malignancy after surgical trauma<sup>10)</sup> may explain the rhabdoid transformation.

Generally malignant meningiomas have a relatively poor prognosis (i.e., high recurrence rates, low 5-year survival rates<sup>12)</sup>, low 5-year local control rates after radiation therapy with or without radiosurgery boost<sup>5)</sup>, and minimal benefits from the traditional antineoplastic agents<sup>11)</sup>). Although several cases of rhabdoid meningiomas with long-term survival<sup>13)</sup>, lacking histological malignant features<sup>4)</sup>, have been reported, the rhabdoid meningiomas are also highly recurrent and have an aggressive clinical course. In a series of 15 rhabdoid meningiomas, 53% were dead of disease after a median of 3.1 years from the first appearance of a rhabdoid morphology and 87% had developed at least one recurrence<sup>13)</sup>.

In our case, the rhabdoid meningioma recurred or regrew in relatively short intervals and proved refractory to the possible therapeutic modalities as other malignant meningiomas. Although the tumor transformed from benign or atypical form to malignant one during the treatments, the rhabdoid differentiation, defined as sheets of loosely arranged cells with eccentric nuclei and eosinophilic cytoplasm containing hyaline perinuclear inclusions, itself seems to constitute a hallmark of malignancy<sup>6,12)</sup>, and suggest an indicator of final malignant transformation. So any histological findings, suggesting rhabdoid features in recurrent meningiomas or even in primary cases, seem to indicate the need for aggressive treatments.

## Conclusion

Although the exact causes of rhabdoid transformation of a benign meningioma are unknown, malignant transformation long duration after surgical resection under an underlying predilection for malignancy is suggested. And we suggest that any histological rhabdoid features in recurrent meningiomas or even in primary cases seem to indicate the malignant clinical course and the need for aggressive treatments, because transformation from a benign or atypical one to a malignant one seems to occur at last.

## References

1. Beckwith JB, Palmer NF : Histopathology and prognosis of Wilms tumors : results from the First National Wilms' Tumor Study. *Cancer*

- 41 : 1937-1948, 1978
2. Biernat W : 2000 World Health Organization classification of tumors of the nervous system. *Pol J Pathol* 51 : 107-114, 2000
  3. Bleggi-Torres LF, Reis-Filho JS, Faoro LN, Noronha L, Montemor-Netto MR, Ramina R : April 2001 : a 70 year old woman with recurrent meningioma. *Brain Pathol* 11 : 481-482, 2001
  4. Cooper WA, Shingde M, Lee VK, Allan RS, Wills EJ, Harper C : "Rhabdoid meningioma" lacking malignant features. Report of two cases. *Clin Neuropathol* 23 : 16-20, 2004
  5. Katz TS, Amdur RJ, Yachnis AT, Mendenhall WM, Morris CG : Pushing the limits of radiotherapy for atypical and malignant meningioma. *Am J Clin Oncol* 28 : 70-74, 2005
  6. Kepes JJ, Moral LA, Wilkinson SB, Abdullah A, Llena JF : Rhabdoid transformation of tumor cells in meningiomas: a histologic indication of increased proliferative activity : report of four cases. *Am J Surg Pathol* 22 : 231-238, 1998
  7. Kirby PA : Rhabdoid meningioma: intraoperative diagnosis using smear preparation. *Diagn Cytopathol* 29 : 292-296, 2003
  8. Kleihues P, Louis DN, Scheithauer BW, Rorke LB, Reifenberger G, Burger PC, et al : The WHO classification of tumors of the nervous system. *J Neuropathol Exp Neurol* 61 : 215-225, 2002
  9. Mawrin C, Hahne R, Scherlach C, Kirches E, Dietzmann K : June 2004 : a male in his late 60s with recurrent extracerebral tumor. *Brain Pathol* 14 : 457-459, 2004
  10. Morantz RA, Shain W : Trinama and brain tumors : an experimental study. *Neurosurgery* 3 : 181-186, 1978
  11. Newton HB, Slivka MA, Stevens C : Hydroxyurea chemotherapy for unresectable or residual meningioma. *J Neurooncol* 49 : 165-170, 2000
  12. Park HJ, Gwak HS, Hwang SK, Kim JE, Kim DG, Cho BK, et al : Clinical analysis of atypical and malignant meningiomas : a study of 52 cases. *J Korean Neurosurg Soc* 30 : 1103-1107, 2001
  13. Perry A, Scheithauer BW, Stafford SL, Abell-Aleff PC, Meyer FB : "Rhabdoid" meningioma : an aggressive variant. *Am J Surg Pathol* 22 : 1482-1490, 1998
  14. Phillips LE, Koepsell TD, van Belle G, Kukull WA, Gehrels JA, Longstreth WT Jr : History of head trauma and risk of intracranial meningioma : population-based case-control study. *Neurology* 58 : 1849-1852, 2002

## Commentary

I congratulate you on your report of this rare CNS tumor which has been scarcely reported in the literature. According

to the clinical course and pathologic findings of your report, I wholeheartedly concur on your diagnosis of rhabdoid meningioma. This tumor first reported in 1998 and classified as a grade III tumor in the 2000 WHO classification of CNS tumors has a tendency for recurrence and aggressive growth with resultant poor prognosis thus necessitating a high degree of suspicion when diagnosing meningiomas. To date the exact cause of this malignant transformation is unknown but the rhabdoid phenotypic expression in meningiomas can be considered as a marker. MIB-1 labeling index and CSF cytopathology are important in the diagnosis of rhabdoid meningiomas. MIB-1 stain is directly related to the proliferative activity and cell morphology of tumors. There is no stain in areas of meningothelial meningiomas whereas diffuse staining is observed in rhabdoid region thus a tumor with MIB-1 labeling index over 10% is regarded as a malignant meningeal tumor. Rhabdoid morphology can be seen in certain primary CNS tumors such as AT/RT, metastatic renal and extrarenal rhabdoid tumors so in differentiating from these tumors, the CSF cytopathology has added value (important). Rhabdoid meningiomas tends to recur frequently and takes on a malignant clinical course so an aggressive approach in treatment is required, but due to reports of MIB-1 positive cells after irradiation, the overall treatment strategy should be carefully chosen. Further accumulation of data and studies are necessary to obtain optimal treatment plan for this malignant tumor.

Chul-Ku Jung, M.D., Ph.D.

Department of Neurosurgery, Konyang University Hospital