

# Total Body Replacement with an Expandable Cage after en Bloc Lumbar Spondylectomy

Dong-Ah Shin, M.D., Keung-Nyun Kim, M.D., Hyun-Chul Shin, M.D., Do-Heum Yoon, M.D.

*Department of Neurosurgery, Yonsei University College of Medicine, Seoul, Korea*

Complete vertebral tumor resection is important in order to prevent local recurrence. Among the available techniques for total spondylectomy, the total en bloc spondylectomy has been accepted as the most sophisticated one. After a total en bloc spondylectomy, anterior and posterior column reconstruction is mandatory in order to achieve stability. We experienced the usefulness of an expandable cage for anterior column reconstruction especially in this surgery. The chance of cutting the nerve root and damaging the spinal cord is minimized because the size of the expandable cage is initially small enough to be inserted into the anterior column. The technical details of total vertebral body replacement with an expandable cage after an en bloc lumbar spondylectomy are described herein.

**KEY WORDS :** Total spondylectomy · Expandable cage · Vertebral tumor.

## Introduction

Primary or secondary vertebral tumors often require surgical removal, usually in a piecemeal fashion. However, this type of removal frequently results in disastrous bleeding, or it may leave a residual tumor mass behind<sup>2,15,18</sup>. Bone bleeding, especially of highly vascular tumors, cannot be easily controlled with any hemostatic methods and it not rarely makes clear distinction of the tumor margin difficult. Another disadvantage of this technique is the possible risk of tumor cell spillage. Therefore, en bloc removal of the affected vertebra with vessel ligation is preferred<sup>18</sup>. Total en bloc spondylectomy (TES) has been accepted as the most sophisticated surgical method, despite the availability of other techniques<sup>1,5,8-11</sup>. However, spine surgeons have regarded this procedure as an extremely difficult one. In addition, post-operative anterior column reconstruction is another challenging one. For this study, we used an expandable cage for anterior column reconstruction after an en bloc lumbar spondylectomy. The technical details are described below.

## Case Report

### Case 1

A 48-year-old female presented with a recently aggravated

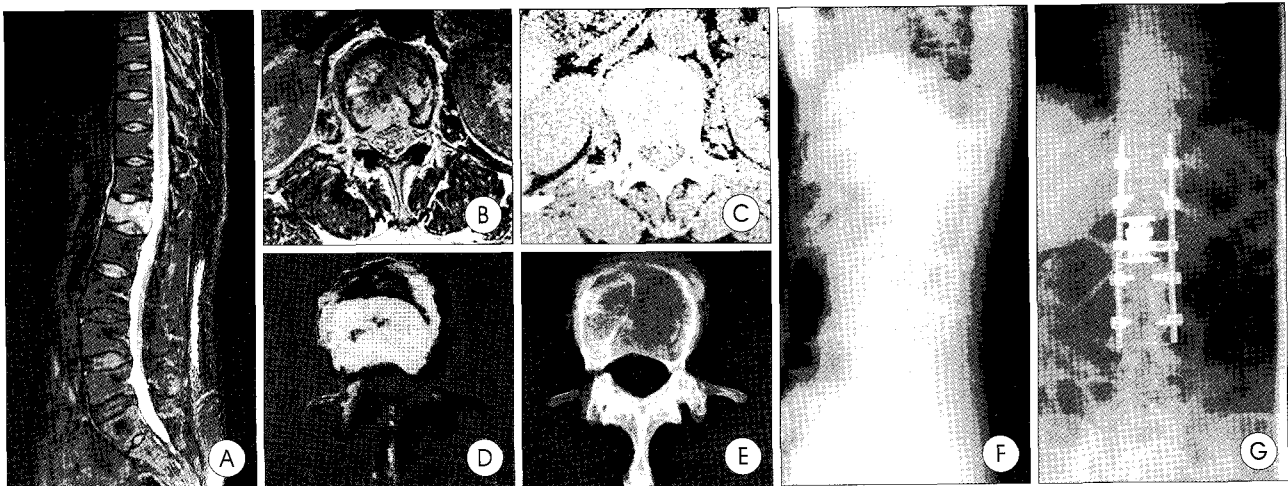
severe lower back and radicular pain. She had no neurological abnormalities. A pathologic fracture of the L1 vertebra was detected upon X-ray. Magnetic resonance imaging (MRI) revealed a solitary L1 metastatic lesion with epidural extension (Fig. 1A, B). No other metastatic lesions were found on the bone scan. Computerized tomography (CT) scans of the chest and abdomen excluded visceral metastasis (Fig. 1C). She had a history of a breast mass, discovered six years ago. Before the operation, a breast biopsy was performed, and it revealed an intraductal papillary carcinoma. Her vertebral tumor was classified as Tomita Stage 4, and the treatment goal was long-term local control. A total en bloc spondylectomy was successfully performed (Fig. 1D, E). The anterior column was reconstructed with an expandable cage, with posterior instrumentation from T11 to L3 (Fig. 1F, G). The total amount of bleeding during surgery was 1500cc. The patient showed no evidence of postoperative neurological compromise, and the recovery period was uneventful.

### Case 2

A 30-year-old woman presented with a severe lower back pain of two-month duration, after slip down injury. She had no neurological abnormalities. She received physical therapy at a private clinic for one month, but her symptoms persisted.

• Received : June 21, 2006 • Accepted : July 19, 2006

• Address for reprints : Keung-Nyun Kim, M.D., Department of Neurosurgery, Yonsei University College of Medicine, 134 Sinchon-dong, Seodaemun-gu, Seoul 120-752, Korea Tel : +82-2-2228-2161, Fax : +82-2-393-9979, E-mail : knkim@yumc.yonsei.ac.kr




**Fig. 1.** Imaging findings of Case 1. A : Sagittal T2-weighted magnetic resonance image(MRI), showing a solitary lesion of L1. B : Axial T2-weighted MRI, showing epidural extension of the tumor. C : Computed tomography scan, showing the tumor mass in the vertebral body, extending to the epidural space. D : Resected specimen of the L1 vertebra. E : X-ray of the resected specimen. F : Anteroposterior view. G : Lateral view.

She subsequently underwent an MRI scan, which revealed a tumor in the L3 vertebra with paravertebral extension. No other metastatic lesion was found upon bone scan. CT scans of the chest and abdomen excluded visceral metastasis. However, a positron emission tomography(PET) scan revealed a suspicious lesion in the colon. The patient underwent a colon biopsy, and the lesion was diagnosed as a moderately differentiated adenocarcinoma. The vertebral tumor was classified as Tomita Stage 5, and the treatment goal was middle-term local control. Total en bloc spondylectomy was successfully performed. The anterior column was reconstructed with an expandable cage with posterior instrumentation from L1 to L5. Perioperative blood loss totaled 2000cc. The patient's postoperative course was uneventful, and she experienced no neurological compromise.

### Operative Techniques

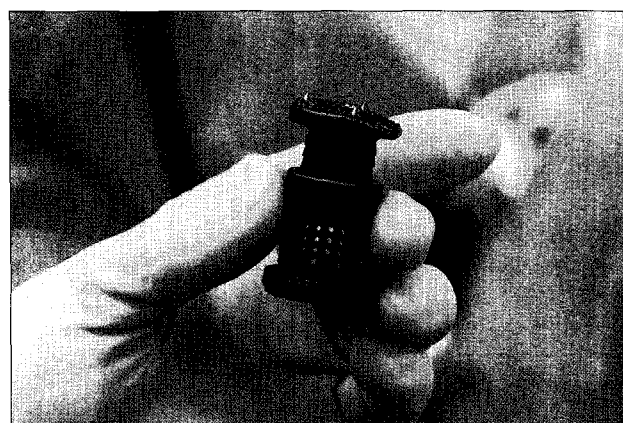
After general endotracheal anesthesia, the patient was placed face down on the radiolucent Wilson frame (OSI, CA, USA) with full relaxation of the abdomen to prevent compression of the vena cava. All pressure points were padded sufficiently. Electrophysiological monitoring of a somatosensory-evoked potential was optional. The operation site, including a graft donor sites (usually the posterior iliac crest), was prepared and draped in the routine sterile manner. The exposure should be long enough to visualize the area above and below three vertebrae and wide enough to visualize the lateral tip of the bilateral transverse processes of the affected vertebra (arbitrarily designated as vertebra "N" from here on). A slide retractor-the BlueBoy extended retractor system (Koros, CA, USA)-was used in order to enable a wider

exposure than the cerebellar curved retractor. In the beginning of the exposure, meticulous hemostasis was achieved. After full exposure, the capsules of N-1/N vertebral zygapophysial joints were denuded. The lower half of the lamina, including the ligamentum flavum and the inferior articular processes of N-1 vertebra, were removed, using a high-speed drill and osteotomes. The capsules of the N/N-1 vertebral zygapophysial joints were then denuded. This is a necessary step in order to facilitate the en bloc laminectomy. The medial side of the vertebra beneath the pars interarticularis was dissected, using a blunt hook, taking care not to injure the exiting nerve root. The polyethylene tube for the threadwire saw (T-saw) guidance<sup>14)</sup> was inserted into the N-1/N interlamina space, passed beneath the N pars interarticularis, and was pulled out from the N/N + 1 neural foramen (Fig. 2A, B). A c-curved, malleable, T-saw guide may be used instead of the tube. The T-saw was introduced into the tube. The tube was then removed, keeping the wire saw in place. It was confirmed that the wire saw did not intercept the nerve root. The same procedure was performed on the opposite side. The T-saw is composed of multifilament, twisted, stainless steel wires. It has a smooth surface that is used to cut bone and prevent damage to the surrounding soft tissue. Each end of the wire saw was strongly clipped with a clamp, then reciprocally moved. A roller was used to adjust to the appropriate cutting angle. The ligamentum flavum, attached to the lower portion of the lamina, was removed with either pituitary rongeurs or a hook after the bilateral pediclotomy. Bone wax was sufficiently applied to the cutting surface of the pedicles in order to prevent bleeding and tumor cell spillage. Meticulous hemostasis of the epidural venous bleeding was achieved. An en bloc removal of the lamina was performed, followed by subperiosteal dissection



**Fig. 2.** Surgical techniques of total en bloc spondylectomy. A : En bloc laminectomy (top view). B : En bloc laminectomy (lateral view). C : Blunt dissection with fingers. D : Insertion of spatulas. E : En bloc corpectomy (cranial end). F : En bloc corpectomy (caudal end).

of the vertebra. Initially, a double-ended dissector was used to make an entry site for the surgeon's fingers. Blunt subperiosteal dissection was done with fingers, which passed between the vertebra and the great vessels (Fig. 2C). This type of dissection is less likely to damage the thoracic aorta or azygos vein between T1 and T4. However, the segmental artery must be carefully detached and clipped anteriorly in areas caudal to T5 before manipulation of the affected vertebra. With a lesion at L1 and L2, the diaphragm insertions should be dissected from the vertebral body before the lumbar arteries are dissected, because the segmental arteries run between the vertebral body and diaphragm insertion. In this step, meticulous ligation of segmental vessels is necessary in order to reduce operative bleeding. Gauze can be used for dissection and hemostasis, but it should be radioopaque and removed prior to closing. When blunt dissection of the entire portion of the affected vertebra was accomplished, posterior instrumentation with pedicle screws was performed from the N-2 vertebra to the N+2 vertebra in order to maintain stability after corpectomy. A rod was applied and locked unilaterally for the corpectomy. Two spatulas were introduced into the prepared space bilaterally (Fig. 2D). The polyethylene tubes for guiding the wire saws were inserted into the upper portion of the N-1/N intervertebral disc, as well as the lower portion of the N/N+1 intervertebral disc, and passed over the spatulas (Fig. 2E, F). Two wire saws were introduced into each tube. The tubes were removed, leaving the wire saws in place. It was confirmed that the wire saws were placed between the disc and the spatulas. A dura protector was introduced beneath the dura. Both ends of the wire saw were strongly clipped



**Fig. 3.** An expandable cage. The cage is able to be inserted, initially, in the small-sized form but can then be expanded to the desired height.

with two clamps and then reciprocally moved. In cases where the vertebral body is freed, it is rotated laterally so as not to compress the dural sac. Here, the freed vertebral body passes through the square made by the N-1 nerve root, the psoas muscle, the N nerve roots, and the lateral margin of the dural sac. At this step, atraumatic handling of the spinal cord and protection of the nerve root is extremely important. The surgeon must avoid excessive nerve root retraction and stretching of the spinal cord in order to prevent irreversible damage. Anterior support can be accomplished by using various materials, including autologous bone, mesh cage, and acrylic cement. However, in our experience, an expandable cage (Synex, Synthes, PA, USA) proves most useful (Fig. 3). The size of the cage is small initially, but it can be expanded to the desired height. For successful fusion and fixation, com-

pression between the N-1 and N + 1 vertebral space is necessary. Transverse fixation, using a cross-bar is recommended for solid fixation. Postoperatively, suction drainage was kept in place for two or three days. The patient was allowed to ambulate with bracing four or five days after surgery. Appropriate orthosis should be worn for two or three months postoperatively.

## Discussion

Even though surgical removal of vertebral tumors is controversial, it is often indicated in order to resolve neurological compromise or pain. The indications for surgery include: intractable pain, existence of a growing tumor resistant to radiation therapy, chemotherapy, or hormonal therapy, spinal cord compromise after prior radiation therapy, spinal instability, and, significant neural compression<sup>3,6,7,12,13</sup>. Tomita devised a surgical classification of spinal tumors based on the pattern of local vertebral tumor progression: Type 1, vertebral body; Type 2, pedicle extension; Type 3, body-lamina extension; Type 4, spinal canal extension; Type 5, paravertebral extension; Type 6, adjacent vertebral extension; and Type 7, multiple<sup>15-18</sup>. Tomita recommends TES in Types 2, 3, 4, and 5. TES can be relatively indicated in Type 1 and 6 but contraindicated in Type 7<sup>15-18</sup>. In the first case, the origin of spinal metastasis was breast carcinoma. Breast carcinoma is generally a slowly growing tumor, except for the inflammatory type. A solitary spinal metastatic tumor was confirmed in this patient by a systemic evaluation. En bloc excision was decided based on Tomita's proposed surgical strategy for long-term local control. In the second case, the patient's primary tumor was colon cancer. Colon cancer is generally a moderately growing tumor. A systemic evaluation for metastasis to vital organs was negative. Her lumbar MRI revealed tumor extension involving a single vertebra. En bloc excision was chosen, according to Tomita's proposed surgical strategy for middle-term local control.

Conventional piecemeal removal has several disadvantages. This technique may result in several complications, such as: 1) disastrous bleeding because bone bleeding cannot be easily controlled with any hemostatic methods, 2) residual tumor mass because intraoperative distinction of the margin of tumor is difficult, and 3) tumor cell contamination<sup>2,15,18</sup>. Total en bloc spondylectomy was introduced by Tomita in 1997, which circumvented these disadvantages<sup>15</sup>. Using this technique, the tumor mass can be totally excised, usually without tumor cell spillage and with total ligation of the tumor's feeding vessels. Total en bloc spondylectomy has been generally accepted as a challenging procedure since it is difficult to perform anterior column reconstruction without cutting the nerve root or excessively manipulating the spinal cord. In our experience,

an expandable cage (Synex, Synthes, PA, USA) was very useful in reconstructing the anterior column. The expandable cage enabled anterior column support without nerve root compromise. The cage is made from a titanium alloy and has a self-locking ratchet expansion mechanism. It is small, initially, but can be expanded to the desired height after insertion. Therefore, it can minimize the manipulation of the spinal cord and nerve roots when it is inserted into the anterior column. The cage is available in several heights (23-73mm) and end plate configurations (21 × 22mm or 25 × 28mm). Bone grafts can be sufficiently inserted in and around the cage. In cervical corpectomy surgery, Zhang et al reported the advantages of using expandable cages were its ability to easily accommodate itself into the corpectomy defect, to tightly purchase into the endplates after expansion and thus minimizing the potential for migration, and finally, its ability to correct kyphosis deformity via its *in vivo* expansion properties<sup>21</sup>.

Removal of the vertebral tumor may give rise to excessive bleeding, especially in cases of hypervascular tumors, such as thyroid cancer. Disastrous bleeding is, in most cases, caused by segmental arteries, radicular arteries, or the epidural venous plexus. When performing a total en bloc spondylectomy, the surgeon can identify and control these vessels before and after corpectomy. Tomita et al. found that ligation of the Adamkiewicz artery reduced spinal cord blood flow by approximately 81% of the control value. This decrease did not affect spinal cord evoked potentials<sup>19,20</sup>, mainly because the blood supply of the spinal cord is protected by three arterial plexus layers: the intercanal, dural, and pial arterial plexus<sup>19,20</sup>.

In TES, the chance of tumor cell contamination during the removal of vertebral tumors is much less than during conventional piecemeal removal. En bloc resection minimizes the chances of tumor cell exposure to surrounding tissues. However, there is still a chance of contamination<sup>18</sup>, especially during pediclectomy or in cases where the tumor has already invaded the outer surface of the vertebra. Contaminated tumor cells can be killed by double-rinsing with distilled water and highly concentrated cisplatin<sup>4</sup>. In an *in vitro* experiment, no tumor cells remained alive after they were exposed to distilled water for 2.5 minutes, followed by highly concentrated cisplatin (0.5mg/ml) for 2.5 minutes<sup>4</sup>.

Total en bloc spondylectomy is a relatively safe procedure and can be widely applied to primary malignant tumors. However, in aggressive, benign tumors or solitary metastasis, indication for TES requires certain prerequisites, such as little or no adhesion to the vena cava or aorta, no multiple metastasis, and/or contiguous involvement of three or fewer vertebra<sup>15-18</sup>. In addition, in order to prevent several major risks; including damage to neural structure, tumor cell contamination, major vessel injury, disturbance of spinal cord circu-

lation, and excessive bleeding, the surgeon should be familiar with the anatomy of the vertebra and its associated visceral organs and vessels.

## Conclusion

Total en bloc spondylectomy is the oncologically ideal resection technique in selected cases of vertebral tumors. Using this technique, the tumor mass can be totally excised without tumor cell spillage, and total ligation of the tumor's feeding vessels can be accomplished. An expandable cage is very useful for anterior column reconstruction in conjunction with this technique.

## References

- Boriani S, Bandiera S, Biagini R, De Iure F, Giunti A : The use of the carbon-fiber reinforced modular implant for the reconstruction of the anterior column of the spine. A clinical and experimental study conducted on 42 cases. *Chir Organi Mov* 85 : 309-335, 2000
- Fujita T, Ueda Y, Kawahara N, Baba H, Tomita K : Local spread of metastatic vertebral tumors. A histologic study. *Spine* 22 : 1905-1912, 1997
- Harrington KD : Metastatic disease of the spine. *J Bone Joint Surg* 68A : 1110-1115, 1986
- Kose H, Kawahara N, Tomita K : Local irrigation with cisplatin following resection of malignant vertebral tumors. *J Jpn Spine Res Soc* 10 : 358-364, 1999
- Magerl F, Coscia MF : Total posterior vertebrectomy of the thoracic or lumbar spine. *Clin Orthop Relat Res* : 62-69, 1988
- McAfee PC, Zdeblick TA : Tumors of the thoracic and lumbar spine : surgical treatment via the anterior approach. *J Spinal Disord* 2 : 145-154, 1989
- Siegel T, Siegal T : Current considerations in the management of neoplastic spinal cord compression. *Spine* 14 : 223-228, 1989
- Stener B : Complete removal of vertebrae for extirpation of tumors. A 20-year experience. *Clin Orthop Relat Res* : 72-82, 1989
- Stener B : Total spondylectomy in chondrosarcoma arising from the seventh thoracic vertebra. *J Bone Joint Surg* 53B : 288-295, 1971
- Stener B, Johnsen OE : Complete removal of three vertebrae for giant-cell tumour. *J Bone Joint Surg* 53B : 278-287, 1971
- Sundaresan N, Rosen G, Huvos AG, Krol G : Combined treatment of osteosarcoma of the spine. *Neurosurgery* 23 : 714-719, 1988
- Tokuhashi Y, Matsuzaki H, Oda H, Oshima M, Ryu J : A revised scoring system for preoperative evaluation of metastatic spine tumor prognosis. *Spine* 30 : 2186-2191, 2005
- Tokuhashi Y, Matsuzaki H, Toriyama S, Kawano H, Ohsaka S : Scoring system for the preoperative evaluation of metastatic spine tumor prognosis. *Spine* 15 : 1110-1113, 1990
- Tomita K, Kawahara N : The threadwire saw: a new device for cutting bone. *J Bone Joint Surg* 78A : 1915-1917, 1996
- Tomita K, Kawahara N, Baba H, Tsuchiya H, Fujita T, Toribatake Y : Total en bloc spondylectomy. A new surgical technique for primary malignant vertebral tumors. *Spine* 22 : 324-333, 1997
- Tomita K, Kawahara N, Baba H, Tsuchiya H, Nagata S, Toribatake Y : Total en bloc spondylectomy for solitary spinal metastases. *Int Orthop* 18 : 291-298, 1994
- Tomita K, Kawahara N, Kobayashi T, Yoshida A, Murakami H, Akamaru T : Surgical strategy for spinal metastases. *Spine* 26 : 298-306, 2001
- Tomita K, Kawahara N, Murakami H, Demura S : Total en bloc spondylectomy for spinal tumors : improvement of the technique and its associated basic background. *J Orthop Sci* 11 : 3-12, 2006
- Tomita K, Toribatake Y, Kawahara N, Ohnari H, Kose H : Total en bloc spondylectomy and circumspinal decompression for solitary spinal metastasis. *Paraplegia* 32 : 36-46, 1994
- Toribatake Y : [The effect of total en bloc spondylectomy on spinal cord circulation]. *Nippon Seikeigeka Gakkai Zasshi* 67 : 1070-1080, 1993
- Zhang HY, Thongtrangan I, Le H, Park J, Kim DH : Expandable Cage for Cervical Spine Reconstruction. *J Korean Neurosurg Soc* 38 : 35-41, 2005

## Commentary

Management of metastatic spine tumors is often very disappointing because of difficult surgical approach due to not only its proximity to the great vessels and neural tissues but also profuse intraoperative bleeding.

Conventional piecemeal removal of tumors has several additional disadvantages including inevitable residual tumor mass due to difficult intraoperative distinction of the tumor margin, and possibility of tumor cell contamination into the general circulation.

Complete tumor resection is mandatory for the prevention of local recurrence in metastatic spine tumor patients whose life expectancy is expected to be long enough for the invasive complex procedure.

Total en-block spondylectomy (TES) was introduced first in 1994 by Tomita Katsuro and it was designed for primary malignant or aggressive benign vertebral tumors that met the following criteria : no spread into adjacent visceral organs, little or no adhesion to the vena cava or aorta, and no multiple metastasis. A contiguous involvement of more than three vertebrae is a relative contraindication for TES.

Authors have reported their experience of TES through a single posterior approach in two patients of metastatic lumbar spine tumor empathizing the usefulness of expandable cages in anterior column reconstruction and the posterior stabilization by screws and rods.

There still seems to be a considerable risk for critical injury during blunt finger dissection around the involved vertebral body and cutting the anterior vertebral body together with the posterior longitudinal ligament by a threaded saw.

I'd like to pay my respects to authors for the successful performance of this complicated procedure and look forward to its role in providing a new road for the radical treatment of both various primary and metastatic spinal tumors.

Soohan Kim, M.D.

Department of Neurosurgery  
Chonnam National University Hospital