

Postoperative Brain Swelling after Resection of Olfactory Groove Meningiomas

Sang Woo Song, M.D., Chul-Keek Park, M.D., Sun Ha Paek, M.D.,
Dong Gyu Kim, M.D., Hee-Won Jung, M.D., Young Seob Chung, M.D.

Department of Neurosurgery, Seoul National University College of Medicine, Seoul, Korea

Objective : Postoperative brain swelling after resection of olfactory groove meningiomas by bifrontal interhemispheric transbasal approach is a knotty subject. Pathogenesis and predictive factors were investigated to prevent the problem.

Methods : Eighteen patients of olfactory groove meningiomas who had undergone surgery were enrolled and retrospectively analyzed using their clinical and radiological data. Bifrontal interhemispheric transbasal approach was used in all patients. Magnetic resonance imaging and transfemoral cerebral angiography were available for investigation in 18 and 14 patients respectively. Postoperative clinical course, tumor volume, peritumoral edema, tumor supplying vessels, and venous drainage patterns were carefully investigated in relation to postoperative brain swelling.

Results : Seven patients (39%) developed clinically overt brain swelling after surgery. Among them, 4 patients had to undergo decompression surgery. In three patients, attempted bone flap removal was done by way of prevention of increased intracranial pressure resulted from intractable brain swelling and two of them eventually developed brain swelling which could be recovered without sequelae. Abnormal frontal base venous channel observed in preoperative angiography was significant predictive factor for postoperative brain swelling ($p=0.031$). However, tumor volume, peritumoral edema, and existence of pial tumor supplying vessels from anterior cerebral arteries were failed to show statistical significances.

Conclusion : To prevent postoperative brain swelling in olfactory groove meningioma surgery, unilateral approach to preserve frontal base venous channels or temporary bone flap removal is recommended when it is indicated.

KEY WORDS : Olfactory groove meningioma · Postoperative complication · Brain edema · Cerebral veins.

Introduction

Olfactory groove meningiomas account for 8% to 18% of all intracranial meningiomas^{5,7,9,11,14}. Olfactory groove meningiomas originate from the dura over the cribriform plate of the ethmoid bone and are usually diagnosed when the tumor is large in size extending to anterior fossa laterally and the sphenoid bone posteriorly. Because of their slow growth, frequent manifestations may include psychological symptoms, nonspecific headache, or anosmia rather than focal neurological deficits in spite of severe brain compression at presentation.

Olfactory groove meningiomas have been reported to be successfully removed with relative low operative mortality in most circumstances^{4,7,17}. However, it is also advocated that olfactory groove meningiomas showed high incidence of peritumoral edema¹⁵. In our experience, not a few numbers of

cases of olfactory groove meningioma showed severe postoperative brain swelling either radiologically or clinically, which sometimes resulted in significant mortality or morbidity. In this article, we report the surgical experiences of 18 patients of olfactory groove meningioma placing emphasis on postoperative brain swelling. The incidence, prognostic factors and possible mechanisms of postoperative brain swelling is discussed.

Materials and Methods

Clinical evaluation

From 1998 to 2004, a total of 18 patients were diagnosed as olfactory groove meningiomas after surgery and their clinical and radiological data were retrospectively reviewed in this study. The mean age of patients was 48.6 years (range; 37~75). The male-to-female ratio was 5:13.

• Received : July 18, 2006 • Accepted : October 2, 2006

• Address for reprints : Young Seob Chung, M.D., Department of Neurosurgery, Seoul National University College of Medicine, 425 Sindaebang 2-dong, Dongjak-gu, Seoul 156-707, Korea Tel : +82-2-840-2435, Fax : +82-2-842-9145, E-mail : yschung@snu.ac.kr

The chief complaints that led to evaluation were psychological or personality problem in 5 patients, visual disturbance in 5, seizure in 4, headache only in 3, and anosmia in 1. All patients showed anosmia in neurological examination which was bilateral in 15 patients and unilateral in 3. Preoperative Karnofsky performance scale(KPS) was 100 in 3 patients, 90 in 9, 80 in 2, 70 in 1, and 60 in 3.

Radiological evaluation

All patients underwent preoperative magnetic resonance(MR) imaging. The volume of edema surrounding meningioma and tumor ($V_{tumor+edema}$) was estimated by measuring the volume of the high signal intensity area around the tumor mass in T2-weighted images. Tumor volume (V_{tumor}) was also measured in gadolinium-enhanced T1-weighted images. The volumes were determined by using volumetric program (Osiris[®] version 3.1, Digital Imaging Unit, University Hospital of Geneva). The percentage of error associated with the repeated measurements of the volume of the same MRI was within $\pm 2\%$. The edema index(EI) was defined as follows;

$$EI = \frac{V_{tumor+edema}}{V_{tumor}}$$

Edema index correlates with the severity of peritumoral edema and EI=1 indicates no peritumoral edema. Relationship between preoperative EI and postoperative brain swelling was investigated.

Fourteen patients were available for the analysis of preoperative transfemoral cerebral angiography(TFCA). In all cases, preoperative embolization had not been indicated because selection of tumor supplying vessels for embolization was difficult. Evidence of pial tumor supplying vessels from anterior cerebral arteries and venous drainage patterns were investigated to find out the predictive factors for the postoperative brain swelling.

Surgery

In all patients, intravenous steroids had been administered at least 24 hours before operation and continued postoperatively until there is radiological evidence of improvement of peritumoral edema. Bifrontal interhemispheric transbasal approach was used in all patients. Bicornal skin incision was made behind the hairline and pericranial tissue was incised. The skin flap and the pericranial tissue were then turned down together. Bifrontal craniotomy was performed just above the supraorbital ridge. Superior sagittal sinus and falx were ligated and a few frontal polar draining vein was coagulated at the frontal base to approach to the tumor in all cases. In 3 patients, attempted bone flap removal was done by way of prevention of increased intracranial pressure resulted from intractable brain swelling. The decision for bone flap removal was rendered during the operation based on the condition of brain after tumor

resection. Postoperative sedation using propofol or pentothal was performed in 13 patients for a couple of days. Among them intracranial pressure was continuously measured with electronic monitoring device in 6 patients.

Statistics

Statistical analyses were performed using SPSS software (version 10.5; SPSS, Chicago, IL). For analyzing predictive factors, the chi-square test and the Mann-Whitney test were used for parametric comparisons. Statistical significance was accepted at $p < 0.05$.

Results

Surgical outcome

Gross total removal of tumor was achieved in 17 of 18 patients (94%). The origin of the tumor was intensively coagulated instead of the complete resection of involved dura. In one patient, a small amount of residual mass attached to anterior cerebral artery was left due to risk of vascular injury. Histological diagnosis of meningiomas included meningothelial type in 15 patients, transitional type in 2 and atypical type in one. Postoperative performance status interpreted in KPS demonstrated worsening in 6 patients (33%) including 2 surgical mortality cases, while 12 patients (67%) showed improved or stationary compared with preoperative value. No tumor recurrence was observed during the mean follow-up period of 21 months (range 4~48).

Seven patients (39%) eventually developed clinically overt brain swelling after surgery. Among them, 4 patients had to be underwent decompression surgery and the result was 3 (1 major and 2 minor) surgical morbidity and one mortality. Other 3 patients including 2 patients, whose bone flap had already been removed prophylactically, were successfully recovered after conservative management.

Complications other than symptomatic brain swelling included combined pneumothorax and postoperative fungal infection of central nervous system in one patient who eventually died. There was one patient with postoperative epidural hemorrhage associated worsening of performance status after surgery. Otherwise, no cerebrospinal fluid leakage or development of cranial neuropathy after surgery was observed.

Radiological Investigations

The result of radiological investigation is summarized in Table 1. The mean tumor volume was 58.9cc (range; 12.9 to 171.7). There was no tumor without peritumoral edema and the mean EI was 4.4 (range 1.4 to 9.8). No significant differences were observed in tumor volume (mean 58.4cc vs 60.5cc, $p=0.618$) and EI (mean 3.7 vs 4.8, $p=0.751$) between

Table 1. Summary of radiological characteristics

Patient number	Sex	age	Tumor volume (cc)	Edema index	Frontal base venous channel	Pial blood supply	Postoperative brain swelling	Management
1	F	39	71.7	1.5	yes	yes	yes	CM, PS
2	F	40	14.9	8.9	yes	no	yes	DS, PS
3	F	65	61.0	4.1	yes	yes	yes	DS, PS
4	F	38	59.0	3.3	no	yes	yes	DS, PS
5	F	37	125.2	1.5	NA	NA	yes	DS, PS
6	M	44	47.6	4.3	yes	yes	yes	PBFR, PS
7	M	75	29.3	2.7	yes	no	yes	PBFR, PS
8	F	37	23.3	7.1	NA	NA	no	–
9	M	38	12.9	9.8	NA	NA	no	–
10	F	41	17.9	9.0	NA	NA	no	–
11	F	45	156.6	1.4	yes	yes	no	PS
12	F	46	24.0	3.2	no	no	no	–
13	F	52	19.4	7.8	no	no	no	–
14	M	55	171.7	1.5	no	yes	no	PS
15	F	68	87.4	2.5	no	yes	no	PBFR, PS
16	M	32	42.5	3.8	no	no	no	PS
17	F	62	47.4	3.2	yes	yes	no	PS
18	F	61	63.0	3.8	no	yes	no	PS

Abbreviations : F: female, M: male, CM: conservative management, PS: postoperative sedation, DS: decompression surgery, PBFR: prophylactic bone flap removal, NA: not available

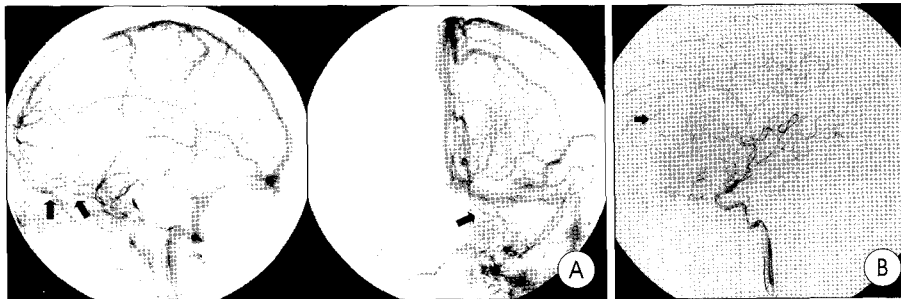


Fig. 1. Preoperative angiography. A : Abnormal frontal base venous channels (arrows) in lateral (left) and Towne's view (right). B : Pial tumor supplying vessels (arrows) in lateral view.

7 patients with postoperative brain swelling and 11 patients without swelling. Six of 7 patients with postoperative brain swelling and 8 of 11 patients without swelling could be evaluated with TFCA. In all cases, main tumor supplying vessels were the branches of the ethmoidal, meningeal, and ophthalmic arteries. In addition, tumors were also supplied by branches of anterior cerebral arteries such as frontopolar artery if the tumor was large. Abnormal frontal base venous channel was observed in 7 patients and pial tumor supplying vessels in 9 patients (Fig. 1). Five patients with abnormal frontal base venous channel in angiography were related to postoperative brain swelling and their relationship had significant predictive value ($p=0.031$) with odds ratio 15. However, pial tumor supplying vessels, only 4 of 9 patients being related to postoperative brain swelling, was insignificant predictive value ($p=0.872$, odds ratio 1.2).

Discussion

Abnormal frontal base venous channel and surgical approach

Surgical approach for olfactory groove meningiomas have evolved considerably since last two decades. For many years, frontal pole resection was considered necessary to expose these tumors. This strategy has become obsolete following the introduction of modern microsurgical techniques, which can access to the tumor without damaging normal brain even for large olfactory groove meningiomas⁸. When considering approach for olfactory groove meningiomas, the following maneuvers should be considered : early interruption of the blood supply to the tumor; nontraumatic separation of the frontal lobes from the tumor; dissection of the anterior cerebral arteries, optic nerves, and chiasm; and excellent visualization of the anterior cranial fossa floor to permit tumor resection and repair of defects¹. The bifrontal interhemispheric transbasal approach is the route preferred by most neurosurgeons⁸. The main advantage of this approach is that it provides early access to the dural attachment of the tumor, thus allowing devas-

cularization and reduction of the tumor mass before the boundaries are dissected. However, postoperative brain swelling is the most serious problem associated with this approach. It has been generally considered as a complication due to brain retraction during surgery¹⁶. Another possible cause of intractable postoperative brain swelling is that venous injuries during the surgery. This is well known phenomenon in the subtemporal approach that one should preserve the vein of Labbe to avoid brain swelling. Venous infarction will probably develop on the basis of venous stasis or venous hypertension related to obstruction of the venous outflow tract.

The bridging veins of the frontal region can be sacrificed with little trouble in cases of pituitary adenoma or craniopharyngioma operated on via the interhemispheric approach¹³. Although the sacrifice of frontal venous vessels is safe and free from any sequelae, there are reported clinical experience of

venous infarction after a bifrontal interhemispheric approach for various indications such as craniopharyngioma, anterior communicating aneurysms^{1,10,16}. Tsutsumi et al.¹⁶ reported that in the circumstance of increased intracranial pressure, edematous brain, and venous thromboses caused by the compression of subarachnoid clots, postoperative venous infarction could result from the sacrifice of frontal bridging vein. He suggested that it is important to preserve the venous system and in some instances, one should select another surgical approach based on the pattern of venous drainage in the frontal lobe. Auque, et al.¹¹ published interesting results about surgical treatment of olfactory groove meningioma in a series of 53 cases (Table 2). They treated 39 patients with interhemispheric bifrontal approach as initial procedure, with a mortality rate of 12.8% and a morbidity rate of 7.6%. Mortality and morbidity were all due to frontal venous infarction. To avoid this complication, 14 patients were successively treated by the subfrontal-pterional approach, which led to an excellent outcome without post-operative mortality in all. In our series, superior sagittal sinus were ligated and divided at the frontal base and frontal cortical vein was coagulated partially to approach to the tumor in all cases. In cases of abnormal frontal venous channel, 75% (6 patients in 8 patients whose angiography showed prominent frontal base venous channel) showed postoperative brain swelling. Postoperative brain swelling was manifested during the first to the third day after surgery. This strongly implies frontal venous infarction was primary cause of postoperative brain swelling. Paterniti, et al.¹⁰ emphasized the significance of venous saving in the surgery of olfactory groove meningioma. They criticized that bifrontal interhemispheric transbasal approach, does not allow a view of posterior pole, and, provides for an anatomical sacrifice of frontal bridging veins, which resulted in venous infarction. So they preferred the pterional approach and they recommended pterional approach on the basis of following advantages over interhemispheric approach : (I) it provides early visualisation and easy dissection of delicate neurovascular structures involved with the back portion of the tumor; (II) the surgeon avoids prolonged brain retraction with the opening of the parasellar cisterns; and (III) the risk of venous damage is absent because this approach doesn't involve the sacrifice of the sagittal sinus and the bridging veins.

However, pterional approach for olfactory groove meningiomas may also have several inherent disadvantages : (I) the

Table 2. Results of treatment of olfactory groove meningiomas : Reports in the Literature

Authors (years)	No. of case	Surgical approach	Mortality rate	Cause of mortality
Rha HK. (1999)	10	9 case : subfrontal approach 1 case : pterional approach	20%	Postoperative brain swelling, major artery injury
Hentchel SJ. (2003)	13	Bifrontal subfrontal approach	0%	-
Paterniti S. (1999)	20	Pterional approach	10%	Extraneurological complications
Auque J. (1996)	39	Bifrontal interhemispheric approach	12.8%	Frontal venous infarct
	14	Pterional approach	0%	-
Solero C. (1983)	98	-	17.3%	Clipping of major artery (5 cases) Postoperative brain swelling (3 cases) Postoperative hematoma (1 case) Postoperative meningitis (2 cases) Medical problem (6 cases)

exposure of the portions of the tumor extending into the olfactory rim and to the contralateral side may be handicapped and makes exaggerated retraction of the frontal lobes (II) the removal of tumor which has invaded the ethmoid sinus, and the closure of dural defects of the cribriform plate and ethmoid may be difficult to perform^{6,17}.

In our series, frontal base venous channel in angiographic finding is significant prognostic factor for postoperative brain swelling after olfactory groove meningioma surgery. Careful evaluation of preoperative angiographic finding can provide critical informations at choosing surgical approach for olfactory groove meningiomas. In case of prominent frontal base venous channel, unilateral subfrontal approach or pterional approach should be considered.

Temporary bone flap removal

There was no factor which can predict postoperative brain swelling except the abnormal frontal base venous channel. This problem can be solved by choosing appropriate surgical approach. In our series, temporary bone flap removal was done at 3 patients. All 3 patients showed serious brain swelling intraoperatively and 2 of them continued to show brain swelling postoperatively. In such conditions, temporary bone flap removal can be helpful tactic for relief from increased intracranial pressure. The decision for temporary bone flap removal should be considered during the operation based on the condition of brain after tumor resection to prevent the catastrophic increased intracranial pressure resulted from intractable brain swelling.

Conclusion

The most popular surgical approach to olfactory groove meningioma is bifrontal interhemispheric transbasal approach, which can sometimes be accompanied with serious postoperative brain swelling. Thorough investigation of venous system in angiographic findings can be helpful to predict such

a complication. In case of olfactory groove meningioma whose surrounding frontal base venous channel is prominent, unilateral approach to preserve frontal base venous channels is recommended to prevent postoperative brain swelling. Temporary bone flap removal also can be helpful to the prevention of increased intracranial pressure resulted from intractable postoperative brain swelling.

References

1. Auque J, Civit TH : Les Dangers du sacrifice du sinus longitudinal superieur dans son tiers anterieur lors de la chirurgie des meningiomes olfactifs. *Neurochirurgie(suppl 1)* 42 : 84-87, 1996
2. Babu R, Barton A, Kasoff SS : Resection of olfactory groove meningiomas. Technical note revisited. *Surg Neurol* 44 : 567-572, 1995
3. Bakay L : Olfactory meningiomas. The missed diagnosis. *JAMA* 251 : 53-55, 1984
4. DeMonte F : Surgical treatment of anterior basal meningiomas. *J Neurooncol* 29 : 239-248, 1996
5. Ei Gindi S : Olfactory groove meningioma. Surgical techniques and pitfalls. *Surg Neurol* 54 : 415-417, 2000
6. Hassler W, Zentner J : Pterional approach for surgical treatment of olfactory groove meningiomas. *Neurosurgery* 25 : 942-945, 1989
7. Hentschel SJ, DeMonte F : Olfactory groove meningiomas. *Neurosurg Focus* 14, 2003
8. Mayfrank L, Gilsbach JM : Interhemispheric approach for microsurgical removal of olfactory groove meningiomas. *Br J Neurosurg* 10 : 541-545, 1996
9. Ojemann RG : Olfactory groove meningiomas. In : Al-Mefty O, ed. *Meningiomas*. New York : Raven Press, 1991, pp383-393
10. Paterniti S, Fiore P, Levita A, La Camera A, Cambria S : Venous saving in olfactory meningioma's surgery. *Clin Neurol Neurosurg* 101 : 235-237, 1999
11. Rha HK, Lee KJ, Cho KK, Park SC, Park HK, Jo JK, et al : Surgical Approach to Large Anterior Basal Meningioma. *J Korean Neurosurg Soc* 28 : 817-822, 1999
12. Rubin G, Ben David U, Gornish M, Rappaport ZH : Meningiomas of the anterior cranial fossa floor. Review of 67 cases. *Acta Neurochir (Wien)* 129 : 26-30, 1994
13. Salibi BS, Myers WO, Gildersleeve JW : En bloc removal of large bilateral olfactory groove meningioma. *Surg Neurol* 9 : 264-266, 1978
14. Solero CL, Giombini S, Morello G : Suprasellar and olfactory meningiomas. Report on a series of 153 personal cases. *Acta Neurochir (Wien)* 67 : 181-194, 1983
15. Tamiya T, Ono Y, Matsumoto K, Ohmoto T : Peritumoral brain edema in intracranial meningiomas : effects of radiological and histological factors. *Neurosurgery* 49 : 1046-1051, 2001
16. Tsutsumi K, Shiokawa Y, Sakai T, Aoki N, Kubota M, Saito I : Venous infarction following the interhemispheric approach in patients with acute subarachnoid hemorrhage. *J Neurosurg* 74 : 715-719, 1991
17. Turazzi S, Cristofori L, Gambin R, Briolo A : The pterional approach for microsurgical removal of olfactory groove meningiomas. *Neurosurgery* 45 : 821-825, 1999
18. Welge-Luessen A, Temmel A, Quint C, Moll B, Wolf S, Hummel T : Olfactory function in patients with olfactory groove meningioma. *J Neurol Neurosurg Psychiatry* 70 : 218-221, 2001

Commentary

With current microsurgical techniques, the complication rates associated with resection of olfactory groove meningiomas is very low. The most common surgical approaches are variants of either the standard pterional or subfrontal exposures, although some authors have advocated an interhemispheric approach. The subfrontal approach may incorporate a uni- or bifrontal craniotomy and orbital osteotomies. Orbital osteotomy and subperiosteal orbital dissection make the anterior and posterior ethmoidal arteries coagulated and divided. The tumor's primary blood supply is from these arteries, and preoperative embolization is not usually done. Angiography is no longer necessary in most of these cases, and MR or CT angiography could replace the conventional angiography. And orbital osteotomy can make the frontal lobe retraction minimized.

Postoperative brain swelling after resection of olfactory groove meningiomas cannot be fully expected preoperatively. Draining veins are thought to be very important, even coagulation of a very small draining vein from the frontal lobe pole can make massive venous infarction of the frontal lobe.

Heon Yoo, M.D., Ph.D.
Department of Neurosurgery
National Cancer Center