

Posterior C1-2 Stabilization Using Translaminar Screw Fixation of the Axis

Jae Taek Hong, M.D.,¹ Sang Won Lee, M.D.,¹ Byung Chul Son, M.D.,¹ Chun Kun Park, M.D.²

Department of Neurosurgery,¹ St. Vincent Hospital, The Catholic University of Korea, Suwon, Korea

Department of Neurosurgery,² Kang Nam St. Mary's Hospital, The Catholic University of Korea, Seoul, Korea

We report a case of C1-2 instability with a bilateral high-riding transverse foramen that was treated with rod-screw fixation using a technique of translaminar rigid screw fixation of the axis. It is believed that a C1-2 fixation with bilateral C-2 translaminar screws has an important advantage over previously reported techniques of C1-2 fixation by eliminating the risk of injury to the vertebral artery during C2 screw placement.

KEY WORDS : C1-2 instability · Rod-screw fixation · Translaminar screw.

Introduction

Many techniques have been described for C1-C2 fixation. Rigid fixation with transarticular screws have been reported to be a safe and highly effective for stabilizing the C1-C2 vertebrae in most patients with the final result being fusion^{2,4}. This procedure results in immediate rigid fixation, which is stiffer in rotation and anteroposterior translation than posterior wiring techniques, such as the Gallie or Brooks fusion, and obviates the need for halo vest immobilization^{2,13}. The use of transarticular screws is biomechanically desirable but the procedure is not easily performed clinically in some cases. In particular, a safe screw trajectory is either impossible or carries a substantial risk of iatrogenic artery damage in up to 20% of cases where there is the presence of a larger groove of the vertebral artery (VA) in the axis, which is often called "a high-riding transverse foramen"^{12,17}. In addition, patients with thoracic kyphosis, obesity, or a fixed cervical deformity that prohibits the correct angle of attack for screw placement⁵ are also poor candidates for C1-C2 transarticular screw fixation. The screw fixation method of a C1 lateral mass with a connection to the C2 pedicle or pars screws is becoming increasingly popular because rod/cantilever constructs for C1-2 have been suggested to be a safer and technically simpler procedure to accomplish than

transarticular screw fixation^{9,15}. However, C2 pedicle screw placement still carries a risk of violating the foramen transversarium, with the possible risk of injury to the VA. We report a case of C1-2 instability with a bilateral high riding transverse foramen, which was stabilized by translaminar screw fixation of the axis to avoid VA injury.

Case Report

Clinical and radiological findings

A 67-year-old woman was admitted with a history of neck pain and progressive quadriparesis over 2 months. The neurological examination revealed bilateral Babinski signs and increased tendon reflexes in both the upper and lower extremities, with limb weakness grade IV-. The lateral cervical film in flexion and extension showed atlantoaxial instability (Fig. 1A), increasing during flexion and producing a deterioration of the anteroposterior diameter of the spinal canal to one third of its initial length at the neutral position. Flexion-extension radiography demonstrated 5mm of motion in the atlantodental interval.

Computed tomography (CT) and magnetic resonance imaging (MRI) showed increased atlantodental interval and spinal cord compression at the cervicomedullary junction during flexion (Fig. 1B, C). Computed tomography (CT) showed a

• Received : February 28, 2006 • Accepted : June 15, 2006

• Address for reprints : Jae Taek Hong, M.D., Department of Neurosurgery, St. Vincent Hospital, The Catholic University of Korea, 93-6 Ji-dong, Paldal-gu, Suwon 442-723, Korea Tel : +82-31-249-7190, 7114, Fax : +82-31-245-5208, E-mail : jatagi15@paran.com

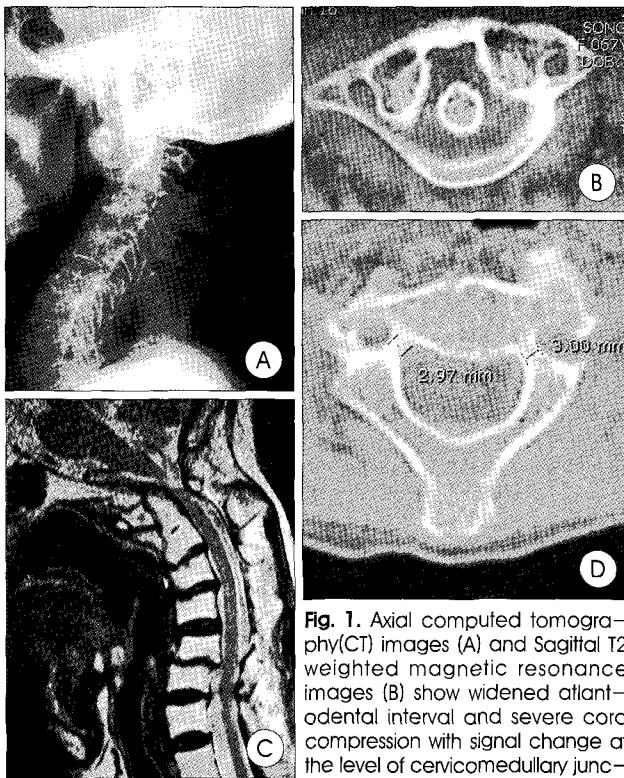


Fig. 1. Axial computed tomography(CT) images (A) and Sagittal T2 weighted magnetic resonance images (B) show widened atlanto-odontal interval and severe cord compression with signal change at the level of cervicomedullary junction. Axial CT (C) demonstrates that the maximum width of bilateral C1-2 pedicle is less than 3.0mm.

maximum width of the bilateral C2 pedicle of <math>< 3.0\text{mm}</math> (Fig. 1D).

Surgery

The patient was positioned prone in a Mayfield headholder. A standard midline skin incision was made from the occiput to C3. The soft tissue from the C1 lateral masses and the C2 posterior arch was removed. The C2 nerve roots were dissected and retracted to create a wide exposure of the C1 lateral masses, C1-2 junction, C1 pars and posterior arch. A C1 laminectomy and suboccipital craniectomy were performed in order to decompress the spinal cord at the cervicomedullary junction. Atlantal screws were placed under fluoroscopic guidance according to the Harms-Melcher technique. A small cortical window was then made at the junction of the C-2 spinous process and lamina on the right, close to the rostral margin of the C-2 lamina, using a high-speed drill. The contralateral lamina was carefully drilled along the angle of the exposed contralateral laminar surface using a hand drill. A 3.5 × 26mm polyaxial screw was then carefully inserted along the same trajectory. A small cortical window was then made at the junction of the spinous process and lamina of C2 on the left, close to the caudal aspect of the lamina. A 3.5 × 26mm screw was then placed into the right lamina with the screw head remaining on the left side of

the spinous process using the same technique reported above. Rods were then inserted. For the constructs including C1, each C1 lateral mass screw was connected to the ipsilaterally projecting screw head of the C2 laminal screws, which fixed each C1 lateral mass to the contralateral C2 lamina (Fig. 2). After instrumentation, all the exposed surfaces of the C1-2 lamina and lateral masses were decorticated with a high-speed drill, and a morcellized autologous iliac bone graft was then harvested and packed around the decorticated bone surfaces between C1 and C2.

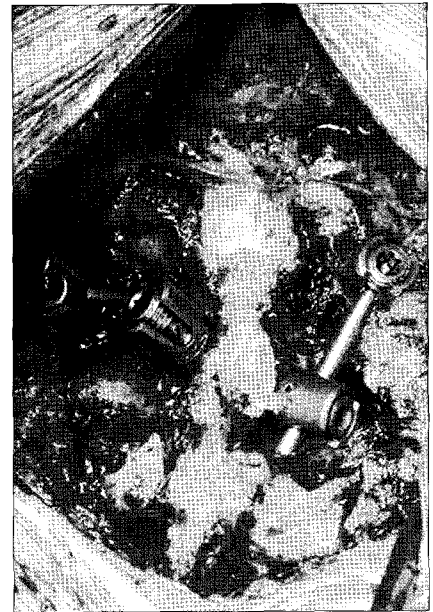


Fig. 2. Intraoperative photograph demonstrates a rod-screw fixation in bilateral C2 laminae and C1 lateral masses.

Postoperative course

Postoperative radiographs, MRI and CT scanning demonstrated almost complete reduction of the ADI and a good position of all instruments (Fig. 3). A Philadelphia collar was used for postoperative neck immobilization. The patient was discharged 10 days after surgery with significant improvement in neck pain. In addition, her motor weakness improved from grade IV- to grade IV+. At the 4-month follow-up examination, the patient reported no neck pain or limb weakness. Radiological study of the cervical spine performed 4 months after surgery revealed evidence of sound bone fusion mass and no cervical instability (Fig. 4).

Discussion

Atlantoaxial fusion is a challenging procedure for most spine surgeons due to the variable anatomy of this region and its proximity to important structures¹⁶. Over the past three decades, there have been significant improvements in atlantoaxial fusion, and various techniques of atlantoaxial fixation have been described in the literature¹⁰. Since Magerl and Seemann introduced the technique of C1-2 transarticular screw fixation in 1979, it is widely accepted that C1-2 transarticular fixation is the strongest construct for treating patients

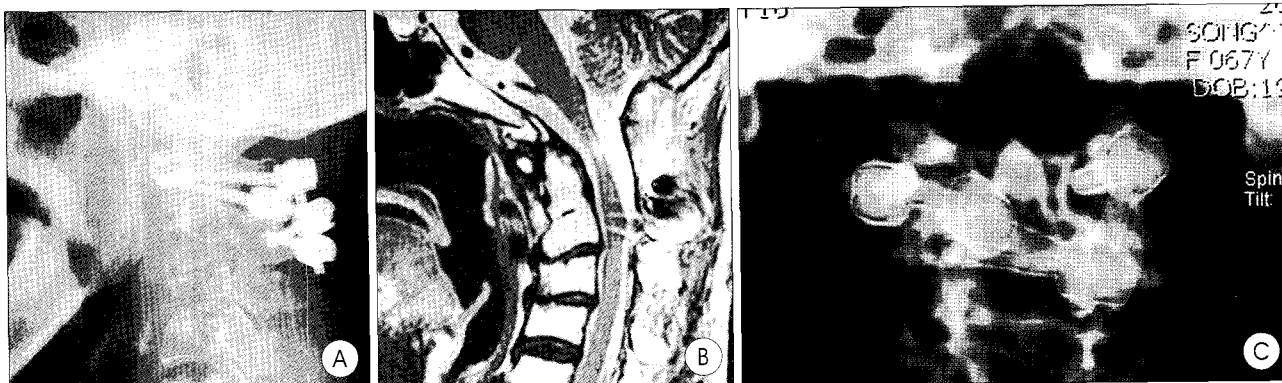


Fig. 3. Postoperative lateral radiograph (A) and Sagittal T2 weighted magnetic resonance image (B) show full reduction of the subluxation and widened upper cervical spinal canal. Three dimensional computed tomography (C) demonstrates bilateral C1-2 screws are well positioned in the C1 lateral mass and C2 lamina.

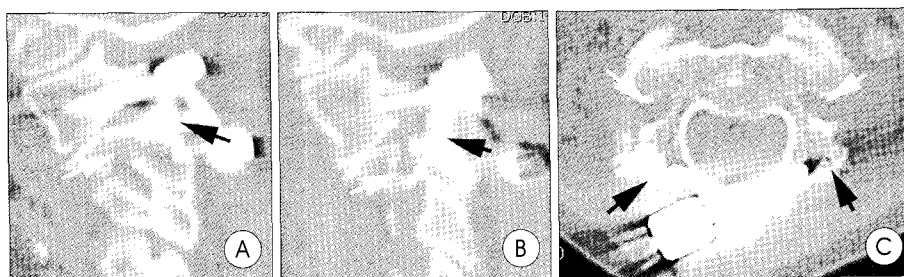


Fig. 4. Postoperative sagittal reconstruction computed tomography (A, B) and axial image (C) performed at 4 months after surgery demonstrate sound bone fusion mass (black arrow) and bilateral narrow pedicle of C2 due to the high riding vertebral artery (white arrow).

with a C1-2 instability^{4,9}). However, C1-2 transarticular screw fixation has serious complications with respect to a VA injury. Furthermore, body habitus (obesity or thoracic hyperkyphosis) may impede the achievement of the low angle needed for the correct placement of the screw across C1 and C2⁵). Goel and Harms separately introduced a procedure in which a C1 lateral mass screw and C2 pedicle screw are placed individually^{3,5}). This procedure increases the feasibility of a reduction during surgery and imposes very little restrictions on inserting the C2 pedicle screws because of the large trajectory angles compared with transarticular screws^{5,14}). Many biomechanical studies agree that the C1-2 rod-screw fixation technique is comparable to C1-2 transarticular screw fixation with respect to the biomechanical stability^{7,9,10}). The more superior and medial trajectory of C2 pedicle screw placement during C1-2 rod-cantilever fixation, compared with the transarticular screw placement, decreases the risk of VA injury⁵). However, C2 pedicle screw placement is still technically challenging, and there is still a risk of VA injury. Smaller C2 pedicles or a high riding transverse foramen may preclude the safe placement of a C2 pedicle screw¹¹).

Magerl et al. first described the translaminar screw fixation of the lumbar spine⁶). Since then, this technique has been considered to be an effective method of posterior stabilization of an unstable lumbar or lumbosacral segment^{1,8}).

significantly easier learning curve⁶).

Although Wright recently introduced the translaminar screw fixation technique in cervical spine disorders¹⁶), there is little information and only short-term follow-up data available^{16,17}). However, there are several potential drawbacks to be solved before this technique can be widely accepted as a standard treatment of C1-2 instability^{16,17}). First, the contralaterally projecting screw heads interfere with the placement of a supplementary posterior wiring procedure. Second, an unrecognized laminar screw can breakout ventrally into the spinal canal. Third, excessively long screws might compromise the C2-3 facet. Fourth, the biomechanical properties of this technique of C2 fixation have not been formally established. However, the elimination of the risk of injury to the VA during C2 screw placement is a significant advantage of C1-2 fixation using bilateral C-2 translaminar screws compared with previously reported techniques of C1-2 fixation.

Conclusion

We presented a case of C1-2 instability treated using C2 translaminar screw fixation. The patient recovered well without any complications. Although there is no biomechanical data available for C2 translaminar screw fixation, it appears that bilateral C2 translaminar screw

fixation technique might be a good alternative for fixing C1-2 instability. The avoidance of injury to the VA is main advantage of this technique.

References

1. Deguchi M, Cheng BC, Sato K, Matsuyama Y, Zdeblick TA : Biomechanical evaluation of translaminar facet joint fixation. A comparative study of poly-L-lactide pins, screws, and pedicle fixation. *Spine* 23 : 1307-1312; discussion 1313, 1998
2. Farey ID, Nadkarni S, Smith N : Modified Gallie technique versus transarticular screw fixation in C1-C2 fusion. *Clin Orthop Relat Res* : 126-135, 1999
3. Goel A, Laheri V : Plate and screw fixation for atlanto-axial subluxation. *Acta Neurochir (Wien)* 129 : 47-53, 1994
4. Haid RW Jr : C1-C2 transarticular screw fixation : technical aspects. *Neurosurgery* 49 : 71-74, 2001
5. Harms J, Melcher RP : Posterior C1-C2 fusion with polyaxial screw and rod fixation. *Spine* 26 : 2467-2471, 2001
6. Heggeness MH, Esses SI : Translaminar facet joint screw fixation for lumbar and lumbosacral fusion. A clinical and biomechanical study. *Spine* 16 : S266-269, 1991
7. Hott JS, Lynch JJ, Chamberlain RH, Sonntag VK, Crawford NR : Biomechanical comparison of C1-2 posterior fixation techniques. *J Neurosurg (Spine)* 2 : 175-181, 2005
8. Humke T, Grob D, Dvorak J, Messikommer A : Translaminar screw fixation of the lumbar and lumbosacral spine. A 5-year follow-up. *Spine* 23 : 1180-1184, 1998
9. Kim SM, Lim TJ, Paterno J, Hwang TJ, Lee KW, Balabhadra RS, et al : Biomechanical comparison of anterior and posterior stabilization methods in atlantoaxial instability. *J Neurosurg* 100 : 277-283, 2004
10. Kuroki H, Rengachary SS, Goel VK, Holekamp SA, Pitkanen V, Ebraheim NA : Biomechanical comparison of two stabilization techniques of the atlantoaxial joints : transarticular screw fixation versus screw and rod fixation. *Neurosurgery* 56 : 151-159; discussion 151-159, 2005
11. Lee DY, Chung CK, Jahng TA : Atlantoaxial fixation using rod and screw for bilateral high-riding vertebral artery. *J Korean Neurosurg Soc* 37 : 380-382, 2005
12. Madawi AA, Casey AT, Solanki GA, Tuite G, Veres R, Crockard HA : Radiological and anatomical evaluation of the atlantoaxial transarticular screw fixation technique. *J Neurosurg* 86 : 961-968, 1997
13. Naderi S, Crawford NR, Song GS, Sonntag VK, Dickman CA : Biomechanical comparison of C1-C2 posterior fixations. Cable, graft, and screw combinations. *Spine* 23 : 1946-1955; discussion 1955-1946, 1998
14. Shin DA, Kim KN, Yoon DH : Posterior atlantoaxial fixation with lateral mass screw in the atlas and pedicle screw in the axis. *J Korean Neurosurg Soc* 34 : 491-494, 2003
15. Tan M, Wang H, Wang Y, Zhang G, Yi P, Li Z, et al : Morphometric evaluation of screw fixation in atlas via posterior arch and lateral mass. *Spine* 28 : 888-895, 2003
16. Wright NM : Posterior C2 fixation using bilateral, crossing C2 laminar screws : case series and technical note. *J Spinal Disord Tech* 17 : 158-162, 2004
17. Wright NM : Translaminar rigid screw fixation of the axis. *J Neurosurg* 3 : 409-414, 2005