

Dorsal Short-Segment Fixation for Unstable Thoracolumbar Junction Fractures

Kwan Sik Kim, M.D., Sung Han Oh, M.D., Ji Soon Huh, M.D.,
Jae Sub Noh, M.D., Bong Sub Chung, M.D.

Department of Neurosurgery, Bundang Jesaeng General Hospital, Seongnam, Korea

Objective : This study is to evaluate the efficacy of dorsal short-segment fixation in unstable thoracolumbar junction fractures.

Methods : The cases of 20 patients who underwent dorsal short-segment fixation were reviewed retrospectively. Clinical outcomes were analysed using Sonntag's pain level, work status, and neurological scale according to the modified Frankel classification. Radiological outcomes were analysed using Mumford's anterior body compression(%), canal compromise ratio, and Cobb's kyphotic angle.

Results : At the latest clinical follow-up (average=14.6 months), there were 19 (95.0%) in group I and 1 patient (5.0%) in II in pain level³⁵. The postoperative work status were 17 (85.0%) in group I, 2 patients (10.0%) in II, and 1 patient (5.0%) in V. Surgery brought to improve the neurologic status. In success group (19 cases, 95%), the average canal compromise ratio was reduced from 0.57 (± 0.07) to 0.05 (± 0.08) ($P < 0.05$), the average anterior body compression (%) was reduced from 41% (± 17) to 18% (± 14) ($P < 0.05$), and the average preoperative kyphotic angle was 20.0° (± 9.0), and corrected to 5.7° (± 7.1) postoperatively, and progressed to 7.8° (± 6.2) at the latest follow-up. There was a case of implantation failure in an elderly osteoporotic patient.

Conclusion : Although there are limitations in the patient number and follow-up period, the present study favors dorsal short-segment fixation for selective cases in unstable thoracolumbar junction fractures.

KEY WORDS : Unstable thoracolumbar junction fracture · Articulotomy · Dorsal reduction · Dorsal short-segment fixation.

Introduction

The thoracolumbar junction vertebrae make up the "hinge junction" of the thoracic and lumbar spine and are particularly vulnerable to traumatic injury. Non-operative management has been shown to be effective if there is minimal spinal canal compromise, intact dorsal elements, and no neurologic deficit¹⁰.

Although surgical intervention is generally considered if the neurological deficits are progressive or imminent³⁸, the optimal treatment strategy for the full spectrum of all thoracolumbar junction fractures is still under debate. There are several surgical options in these injuries, for example ventral or dorsal approach, short- or multi-segmental fixation, bone graft or not, and so forth^{1,2,17,22,23,32,37}.

Ventral approach is available for adequate decompression and the ventral strut for axial loading, but requires extensive

surgical procedure with morbidity of thoracostomy and may be necessary for staged dorsal procedure. Medical complications are relative contraindication³⁰. Lateral extracavitary approach requires extensive muscle dissection and has difficulty to visualize the contra-lateral pedicle by unilateral approach.

Multi-segmental fixation can achieve firmer fixation, but may result in stiffness and discomfort.

The main advantages of the dorsal approach with short-segment fixation is to preserve motion segment, and to have the simplicity and the familiarity to the spine surgeon, but a recognized disadvantage is the difficulty in restoring the anterior column. Failure to restore the anterior column support can lead to secondary kyphosis, instability, pain, and late onset neurological deficit, depending primarily on the residual load transfer capacity of the fractured vertebral body²². This study is to evaluate the efficacy of dorsal short-segment fixation in unstable thoracolumbar junction fracture.

• Received : April 26, 2006 • Accepted : May 29, 2006

• Address for reprints : Sung Han Oh, M.D., Department of Neurosurgery, Bundang Jesaeng General Hospital, 255-2 Sechyeon-dong, Bundang-gu, Seongnam 463-050, Korea Tel : +82-31-779-0285, Fax : +82-31-779-0895, E-mail : shoh1@dmc.or.kr

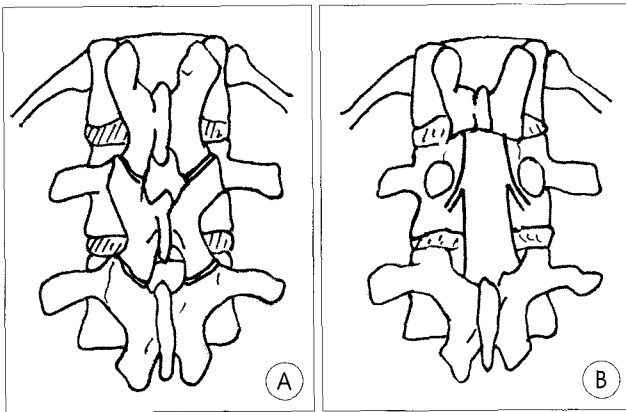


Fig. 1. Illustration showing the extent of dorsal decompression. A : Preoperative. B : Postoperative.

Materials and Methods

This is a retrospective review of 20 patients with unstable thoracolumbar junction fractures managed by dorsal short-segment fixation. There were 12 males and 8 females. Their average age at the time of surgery was 37.3 years (range : 20~62 years). The majority of the injuries resulted from fall from a height (16 cases, 80.0%) and 4 cases (20.0%) from vehicle accidents. There were 18 cases (90.0%) in one level injury and 2 cases (10.0%) in two levels injury. Their injury levels were T12 in 5, L1 in 11, and L2 in 6 cases. The most recent clinical follow-up assessment was attempted and the average follow-up period was 14.6 months.

Indications for surgical instrumentation in this entire series included the presence of any one or more of the followings : presence of neurologic involvement caused by the fracture, kyphosis more than 20°, loss of vertebral body height by more than 50%, compromise of spinal canals, or any other instability which are based on the criteria of unstable thoracolumbar fracture by McAfee et al²¹.

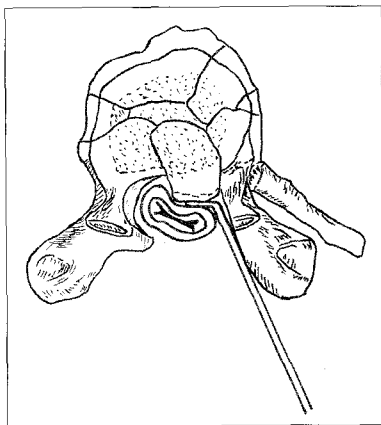


Fig. 2. Illustration of injured segment showing reimpaction of the retropulsed bony fragments anteriorly into the vertebral body using reverse-angled curet.

In highly comminuted fractures and severely midline retracted fragments (canal compromise ratio >0.70) with anticipated load sharing, we performed ventral approach with strut grafting. In cases of pedicle fracture(s), “two above and one below” pedicle screw constructs were per-

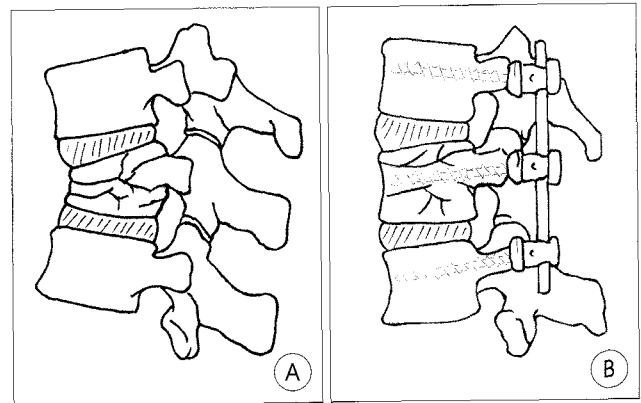


Fig. 3. Illustration of dorsal short-segment fixation. A : Injured segment showing bursting fracture, canal compromise and kyphotic deformity. B : Dorsal short-segment fixation confined to a level above and below the injured segment including the injured segment.

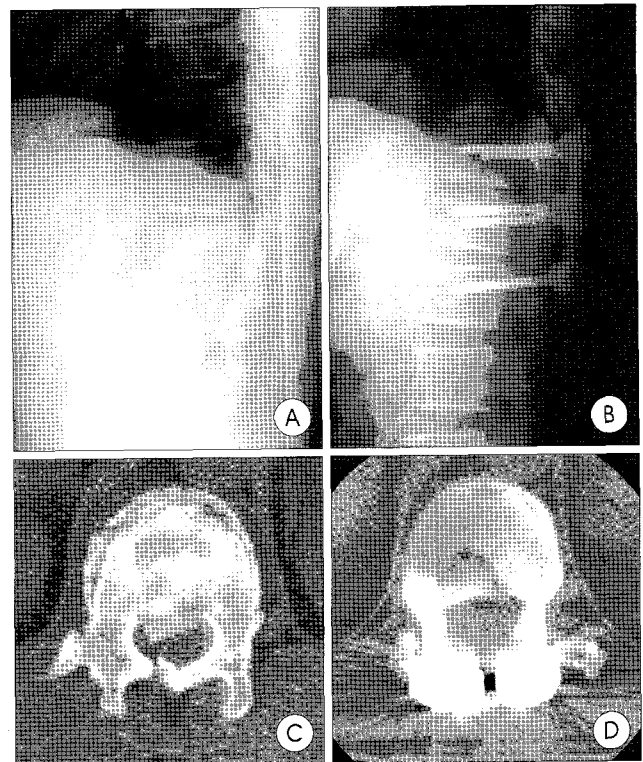


Fig. 4. A case of 36-year-old male patient with T12 bursting fracture. A : Preoperative plain radiograph. B : Postoperative plain radiograph showing dorsal short-segment pedicle screw fixation on T11, T12 and L1 at 7 months. C : Preoperative computed tomography(CT) scan showing apposition of bony fragments into the spinal canal with laminar impingement. D : Postoperative CT scan showing restoring the bony fragments into the original position.

formed. We excluded these cases in this study.

Operations were performed by standard dorsal midline approach. In 13 cases of anterior canal compromise due to bone fragments into the spinal canal, wide bilateral total laminectomy of injured segment and partial laminectomy of adjacent upper segment so far as articulectomy were performed, according to circumstances partial pediclectomy was performed (Fig. 1),

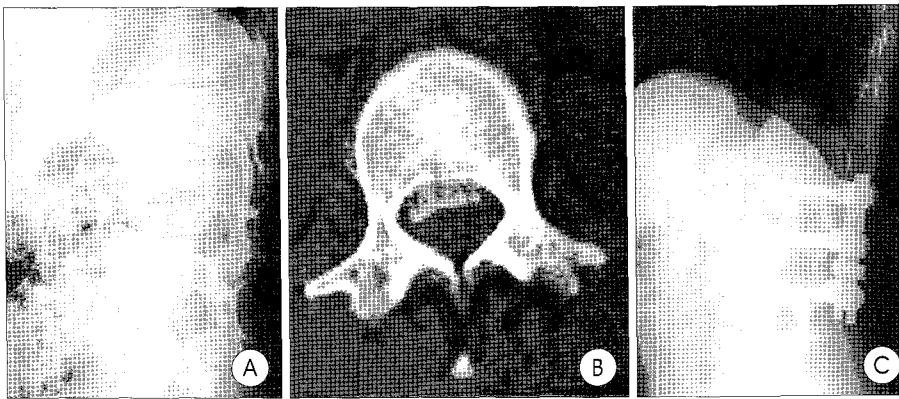


Fig. 5. A case of 26-year-old female patient with L1 bursting fracture. A : Preoperative plain radiograph. B : Preoperative computed tomography(CT) scan showing apposition of bony fragments into the spinal canal. C : Postoperative plain radiograph showing dorsal short-segment pedicle screw fixation on T12, L1 and L2 at 27 months.

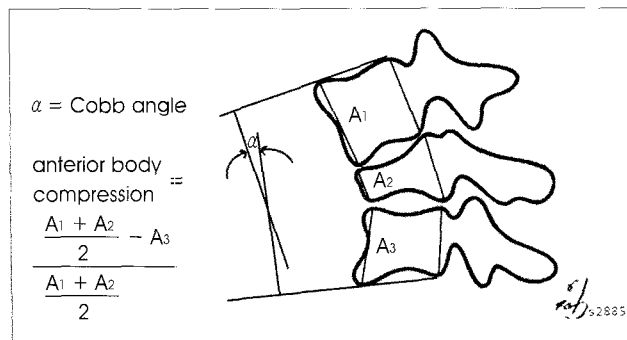


Fig. 6. Illustration of Cobb angle and formula used to measure anterior body compression using the formula by Mumford et al.²⁵⁾ from plain radiograph.

then worked laterally, or infero- or supero-laterally to the thecal sac to dissect fragments off the cord and to reimpact bone fragments anteriorly into the vertebral body by using reverse-angle curet or small impactor (Fig. 2). There were 2 cases of dura repair for dorsal dural laceration. Fundamentally, the pedicle screw fixation was comprised on one level above and below the injured segment including the injured segment itself, if the pedicles were intact (Fig. 3). Correction of the kyphotic deformity and restoration of the body height were performed by this cantilever beam fixation system. After completion of decompression and fixation procedure, in-situ postero-lateral bone grafts obtained from the autogenous iliac, laminae and spinous of the patient, or xenograft were performed (Fig. 4, 5). Rigid orthosis were routinely used for 3 months after the operation.

Clinical and imaging follow up

We use three clinical parameters, the postoperative pain level using Sonntag's method³⁵⁾, the postoperative work status, and the pre- and postoperative neurologic status according to the modified Frankel classification³⁾. As radiological parameters, the canal compromise ratio was measured from preoperative

and postoperative computed axial tomography, the anterior body compression (%) was calculated by anterior body heights of the injured vertebra and the non-injured, adjacent vertebrae above and below the injured level using the formula by Mumford et al.²⁵⁾ (Fig. 6), and the kyphotic angle was measured between the superior end-plate of the upper and the inferior end-plate of the lower non-injured vertebra by Cobb's method from the preoperative, postoperative, and follow-up lateral views of the plain

radiographs³⁶⁾ (Fig. 6). The paired t-test for analysis by applying SPSS (ver. 11.0) program was performed and the p-value <0.05 was considered to be significant.

Results

Postoperative pain and work level

At the latest clinical follow-up, there were 19 patients (95.0%) in group I and 1 patient (5.0%) in group II in pain level according to Sonntag's method³⁵⁾ (Table 1). The postoperative work status were 17 patients (85.0%) in group I, 2 patients (10.0%) in group II, and 1 patient (5.0%) in group V (Table 2).

Neurological status

According to the modified Frankel scale³⁾, preoperative neurological status were group E in 5 patients (25.0%), group Db in 2 patients (10.0%), group Da in 8 patients (40.0%), and group C in 5 patients (25.0%). No patient lost neural function after the operation. Surgery brought to improve the

Table 1. Postoperative pain level according to Sonntag's method

Group	Criteria	No. (%)
I	Pain free	19 (95.0%)
II	Mild pain, no medication	1 (5.0%)
III	Moderate pain, intermittent medication	
IV	Severe pain, continuous medication	
Total		20 (100%)

Table 2. Postoperative work status

Group	Criteria	No. (%)
I	Same or better work status	17 (85.0%)
II	Working but at a lower level	2 (10.0%)
III	Unable to work	
IV	Not working prior to operation	
V	Retired state prior to operation	1 (5.0%)
Total		20 (100%)

Table 3. Preoperative and postoperative neurological status according to the Modified Frankel Scale

Group	Criteria	Pre-operation	Post-operation
		No (%)	No (%)
A	No neurological function		
B	Preservation of sensory		
C	Inadequate motor function	5 (25.0%)	
Da	Allowing ambulation with assistance	8 (40.0%)	
Db	Self ambulation with minor difficulty	2 (10.0%)	2 (10.0%)
E	Normal neural status	5 (25.0%)	18 (90.0%)
Total		20 (100%)	20 (100%)

Table 4. Preoperative and postoperative canal compromise ratio and anterior body compression (ABC %) according to Mumford's method

	Canal compromise ratio*	Anterior body compression (ABC%)†
	N=8/13	N=19 (Success group)
Preoperative	0.57 ± 0.07	41% ± 17
Postoperative	0.05 ± 0.08	18% ± 14

*† P < 0.05

neurological status from group C to group E in 3 patients, from group C to group Db in 2 patients, from group Da to group E in 8 patients, from group Db to group E in 2 patients (Table 3).

Canal Compromise

Preoperatively all patients were measured the canal compromise ratio by using computed axial tomography. We pushed back the communited bony fragments into the original position by using reverse-angle curet or angled small impactor in 13 patients (65.0%). The average canal compromise ratio in 8 patients of them who were carried out postoperative computed axial tomography was reduced from 0.57 (±0.07) to 0.05 (±0.08) (P < 0.05) (Table 4).

Table 5. Preoperative kyphosis and postoperative kyphotic correction

	Total (N=20)	Success Group (N=19)	Failed Case (N=1)
Preoperative (A)	19.7° ± 8.9	20.0° ± 9.0	14
Postoperative (B)	5.5° ± 7.0	5.7° ± 7.1	1
Follow up (C)	8.2° ± 6.3	7.8° ± 6.2	16
Initial correction (A-B)	14.2	14.3	13
Loss of correction (C-B)	2.7	2.1	15
Overall correction (A-C)	11.5	12.2	-2

Anterior Body Compression²⁴⁾

The average anterior body compression (ABC%) of all patients was corrected from 41% (± 17) to 18% (± 14) (P < 0.05) in success group (Table 4).

Kyphotic Correction and Loss of Correction^{1,24)}

The average preoperative kyphotic angle of all patients was 19.7° (± 8.9), and corrected to 5.5° (± 7.0) post-operatively, and progressed to 8.2° (± 6.3) at the latest follow-up. Their initial correction was 14.2°, loss of correction was 2.7°, and overall correction was 11.5°. The average preoperative kyphotic angle of success group (19 cases, 95%) was 20.0° (± 9.0), and corrected to 5.7° (± 7.1) post-operatively, and progressed to 7.8° (± 6.2) at the latest follow-up. Their initial correction was 14.3°, loss of correction was 2.1°, and overall correction was 12.2° (Table 5)¹⁾.

Complication and implant failure

There was no surgery related complication, but a screw pull-out with delayed kyphosis in an elderly osteoporotic patient with diabetes mellitus and internal malignancy. His initial correction was 13.0° and loss of correction was 15.0° at 3 months after the operation, which has not been further aggravating

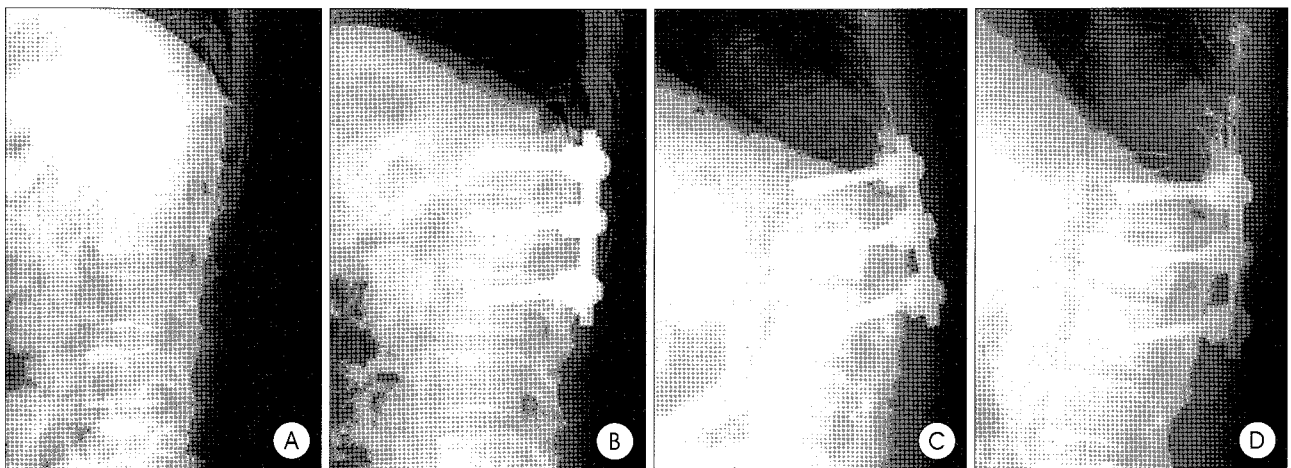


Fig. 7. A case of 62-year-old male patient with L1 bursting fracture. A : Preoperative plain radiograph. B : Immediate postoperative plain radiograph showing segment pedicle screw fixation on T12, L1 and L2. C, D : Postoperative plain radiograph showing screw pull-out and delayed kyphosis at 8 month. C : flexion view. D : extension view.

up to 8 months (Table 5) (Fig. 7). We regarded it as a case of implant failure^{22,23,32,37}.

Discussion

The surgical goals for unstable thoracolumbar junction fractures are adequate decompression of neural element, restoration of vertebral body height and alignment, and mechanical stability, but there is still controversy in choosing operative procedure^{1,2,8,17,22,23,32,37}. Multi-segmental fixation (instrumentation two segments above and below the fracture) can achieve relatively closer alignment to a normal spine and firmer fixation. The multi-segmental fixation is indicated for patients with complete cord injury, elderly patients, and patients with poor compliance to wear postoperative spinal brace^{22,23,28}, but cannot preserve the motion segments. Several reports suggested dorsal short-segment fixation as an efficient and safe method for the thoracolumbar fractures^{15,17,18,28,29}. However, delayed as well as early failure, such as screw breakage, bending, loosening, pull-out, or delayed kyphosis had been reported to be 40~45% in early studies^{1,7,23}.

The loss of kyphotic correction

In general, the pedicle screw system resists both bending and axial loading, can be used to correct angulation deformity and restore the height as a cantilever beam fixation system. However, when the vertebral body is significantly compromised and associated with a considerable loss of height or abnormal angulation, the biomechanics of the system are altered significantly.

The changes in interbody height and angle cause the neural axis and instantaneous axial rotation(IAR) to be shifted posteriorly away from the injury and kyphotic angulation is inevitable. Therefore, the constructive ventral strut should be considered in the anticipated load sharing, such as highly comminuted fractures and severely midline retropulsed fragments. Needless to say, in the highly comminuted fractures and severely midline retropulsed fragments (canal compromise ratio >0.70) with anticipated load sharing, we performed ventral approach with strut grafting. Generally, the criteria as correction loss or implant failure is considered to be 10° or more and the critical period appears to be the 6 months after the procedure^{22,23,32,37}. Lee et al.¹⁸ reported 6 cases of implantation failure out of 48 patients who underwent dorsal short-segment fixation in thoracolumbar bursting fractures. They divided into two groups for thoracolumbar burst fractures; a group with screws on the injured vertebra and the other group without screws on the injured vertebra. The latter group showed poor initial correction as well as deterioration in the overall correction.

In our study, there was a case of loss of kyphotic correction, in an elderly osteoporotic patient, out of 20 patients over the

latest follow up (Fig. 7). Lee et al's.¹⁸ result is similar to ours. However, in our study, the pedicle screw fixation was included the injured segment itself as well as one level above and below it, if its pedicles were intact, which could be considered to reduce the failure rate. The failed cases, 2 in Lee et al's and 1 in ours, were in osteoporotic patients. Therefore, in the osteoporotic patients, certain principles should be considered, such as multiple site fixations, accepting lesser degrees of deformity correction, and avoiding ending the instrumentation within kyphotic segment¹¹. Oertel J et al.²⁶ reported 3 cases of progressive kyphosis in 133 patients underwent surgery after removal of fixator and recommended the ventral approach in fractures with initial kyphotic deformation or wedge angle of 20° or more. However, besides the initial kyphotic angle, it is more reasonable to add other factors to choose ventral approach, such as the comminution of the fractured body, apposition of fragments and patient's status^{22,28}.

The apposition of bone fragments (Fig. 4)

There were 13 cases (65.0%) of canal compromise in our series. Preoperatively all patients were measured the canal compromise ratio by using computed axial tomography, their average ratio was 0.38 (± 0.24). We pushed back the comminuted bony fragments into the original position by using reverse-angle curet or small impactor in them after adequate decompression. The average canal compromise ratio in 8 patients of them who were carried out postoperative computed axial tomography was reduced from 0.57 (± 0.07) to 0.05 (± 0.08) ($P < 0.05$) without any further aggravation of neurological status after the operation (Table 4).

Ligamentotaxis was previously thought to be dependant on an intact posterior longitudinal ligament, which would reimpact bone fragments into the vertebral body following operative distraction. In fact, the fibers necessary for reduction of these bone fragments originate in the annulus of the superior vertebra in the midportion of the end plate of the spine (Annulotaxis)⁸. Pitfalls to restore the apposed bony fragments by the dorsal approach are neural injury, incomplete decompression⁸, and bleeding. However, partial laminectomy of the adjacent upper segment add to wide bilateral total laminectomy of the injured segment so far as articulectomy, according to circumstances partial pediculectomy, was available for working space to reimpact the bone fragments anteriorly. Profuse bleeding from the venous plexus can be avoidable by gentle procedure with applying a sheet of cottonoid and Gelfoam-Aviton packing.

The posterior comminution (Fig. 4)

In case of thoracolumbar fracture with associated laminar fracture, there is the possibilities of dorsal dural laceration, CSF

leakage or neural entrapment by impaction of the dural sac into the gap of the fractured lamina, so the dorsal approach is favored in that case. Kim¹³⁾ reported posterior dural laceration in 16 cases out of a total 36 patients with spinal bursting fractures during operation. In that study, the statistical analysis revealed significant associations of dural laceration with pre-operative neurologic deficits, high grade spinal canal compromise, and comminuted fracture. He recommended that these patients should undergo posterior exploration of the spinal canal, extraction of neural elements, and repair of the lacerated dura before any spinal reconstruction maneuver.

In our series, there were 2 cases (10%) of dorsal dural laceration and 4 cases (20%) of laminal impingement on the spinal cord.

Less invasive anterior reconstruction

Up to now less invasive anterior column reconstruction technique has been developed to provide the ventral strut's role in unstable thoracolumbar junction fractures to avoid extensive surgery by some authors^{4,6,15,27)}.

In the mid 1980s, Daniaux^{4,5)} proposed a new technique, transpedicular spondyloplasty, as a relatively undemanding to augment the anterior column by autografting cancellous and cortical chip bones through the pedicle(s) into the vertebral body defect. However, this technique has not been able to prevent secondary kyphosis reliably in traumatic thoracolumbar fractures, as several authors had shown, largely due to aseptic bone necrosis of the grafted materials^{1,16,19,38)}.

Oner FC et al²⁷⁾ developed a technique to restore and augment the fractured anterior column through a transpedicular approach in 20 patients with unstable thoracolumbar fractures. They used Ballon-assisted-endplate-reduction(BAER) followed by vertebroplasty with calcium phosphate cement in combination with short-segment pedicle screw construct. In that study, there was no neurological complication. The average Cobb angle was corrected from 11° (± 9.2) to -1.6° (± 9.5). The average central body height increased from 66% (± 10.7) to 81% (± 10.4) of the estimated intact height. The average anterior vertebral body height increased from 71% (± 14.9) to 92% (± 10.3) of the estimated intact height. There was also promising cadaver study of augmented vertebroplasty in traumatic thoracolumbar fractures²⁷⁾.

Oertel²⁶⁾, Daniaux^{4,5)} and Oner's²⁷⁾ dorsal instrumentation sites were limited on the above and below the fracture level, exclusive of the fractured segment^{5,6)}. On the contrary, our trial sites included the injured segment, if the pedicles were intact (Fig. 4, 5). Several authors demonstrated one stage posterolateral decompression and stabilization via the transpedicular route for unstable thoracolumbar fractures and metastatic vertebral tumors^{9,12,14,34)}. After achieving the canal decompression

by wide laminectomy, arcticlectomy and pediclectomy, they removed all the retropulsed bony fragments and ventral column support was performed using cage(s)^{9,14)}. However, our decompression was attained not by removing the retropulsed bony fragments, but just reimpacting those anteriorly into the vertebral body, which would make the cord be less damaged and support ventral strut (Fig. 4, 5). With the short-segment pedicle screw constructs on above and below the injured segment including the injured vertebra itself, if the pedicles were intact, and just reimpaction the fragmented bones into the original position may participate in load sharing onto the injured vertebral body and preventing delayed kyphosis during the follow-up. Lee et al's.¹⁸⁾ data supports us. In-situ posterolateral bone grafts and postoperative rigid orthosis may be also important for providing stability, but there has been still some controversies^{1,31)}.

Generally, the ventral constructs can be applied to provide load sharing to reduce the magnitude of the bending moment experienced by the hardware in flexion-compression²⁰⁾. However, the most reliable and least invasive technique to achieve a good realignment of the spine is with the use of pedicle screw construct³⁸⁾. But to restore ventral column is the utmost challenge of dorsal short segment fixation in unstable vertebral injuries^{22,28)}. Traditionally, the injured segment was excluded in the dorsal short-segment fixation for unstable thoracolumbar bursting fractures and the failure rate was reported highly^{1,7,23)}. Lee et al.¹⁸⁾ also reported that a group without screws on the injured vertebra showed poor initial correction as well as deterioration in the overall correction. However, our technique included on the injured segment, if the pedicles were intact, and performed reimpaction the protruded bony fragments into the original position, which may have gained time up to fusion and grant the stability without extensive surgical procedure, nor neurological aggravation in selective unstable thoracolumbar junction fractures. We think that the posterior communitation may more justify the dorsal approach¹³⁾.

Conclusion

Although more follow-up periods and patients are needed to elute solid conclusion, the present study favors dorsal short-segment fixation for selective cases in unstable thoracolumbar junction fractures.

• Acknowledgement

This article was presented at the annual spring meeting of the Korean Neurosurgical Society in 2006.

References

1. Alanay A, Acaroglu E, Yazici M, Ozmur A, Surat A : Short-segment pedicle instrumentation of thoracolumbar burst fractures : does transpedicular intracorporeal grafting prevent early failure? *Spine* 26 : 213-217, 2001
2. Alvine GF, Swain JM, Asher MA : The safety and efficacy of variable

- screw placement (VSP) and Isola spinal implant systems for the surgical treatment of thoracolumbar burst fractures. *J Bone Joint Surg (Suppl)* 79B : 306, 1997
3. Bradford DS, McBride GG : Surgical management of thoracolumbar spine fractures with incomplete neurologic deficits. *Clin Orthop* 218 : 201-216, 1987
 4. Daniaux H : Transpedicular repositioning and spongiosplasty in fractures of the vertebral bodies of the lower thoracic and lumbar spine. *Unfallchirurg* 89 : 197-213, 1986
 5. Daniaux H, Seykora P, Genelin A, Lang T, Kathrein A : Application of posterior plating and modifications in thoracolumbar spine injuries. Indication, techniques, and results. *Spine (Suppl 3)* 16 : S125-133, 1991
 6. Danisa OA, Shaffrey CI, Jane JA, Whitehill R, Wang GJ, Szabo TA, et al : Surgical approaches for the correction of unstable thoracolumbar burst fractures : a retrospective analysis of treatment outcomes. *J Neurosurg* 83 : 977-983, 1995
 7. Ferguson RL, Allen BL Jr : A mechanistic classification of thoracolumbar spine fractures. *Spine* 15 : 667-673, 1990
 8. Fredrickson B, Mann K, Yuan H, Lubicky JP : Reduction of the intracanal fragment in experimental burst fractures. *Spine* 13 : 267-271, 1988
 9. Hahn KH, Lee SG, Jeong JH, Yoo CJ, Kim WK, Kim YB : One Stage Decompression and Circumferential Stabilization by Posterior approach in the Unstable Burst Fracture of Thoracolumbar and Lumbar Spine. *J Korean Neurosurg Soc* 32 : 112-117, 2002
 10. Hitchon PW, Torner JC : Recumbency in thoracolumbar fractures. *Neurosurg Clin North Am* 8A : 509-517, 1997
 11. Hu, Serena S : Internal Fixation in the Osteoporotic Spine. *Spine* 22 : 43S-48S, 1997
 12. Kaya RA, Aydin Y : Modified transpedicular approach for the surgical treatment of severe thoracolumbar or lumbar burst fractures. *Spine* 4 : 208-217, 2004
 13. Kim SH : Surgical approach of thoracolumbar or lumbar burst fracture with associated laminar fracture. *J Korean Neurosurg Soc* 25 : 2455-2464, 1996
 14. Kim YS, Cho YW : One Stage Three Column Fixation by Posterior Approach in Thoracolumbar Junction Lesion. *J Korean Neurosurg Soc* 27 : 222-228, 1998
 15. Kim YW, Oh SH, Yoon DH, Chin DG, Cho YE, Kim YS : Short segment pedicle screw fixation with augmented intra-operative vertebroplasty in unstable thoraco-lumbar fracture. *J Korean Neurosurg Soc* 30 : 1271-1277, 2001
 16. Knop C, Fabian HF, Bastian L, Blauth M : Late results of thoracolumbar fractures after posterior instrumentation and transpedicular bone grafting. *Spine* 26 : 88-99, 2001
 17. Kramer DJ, Rodgers WB, Mansfield FL : Transpedicular instrumentation and short-segment fusion of thoracolumbar fractures. *J Orthop Trauma* 9 : 499-506, 1995
 18. Lee YS, Sung JK : Long-term follow-up results of short segment pedicle screw fixation for thoracolumbar burst fractures. *J Korean Neurosurg Soc* 37 : 416-421, 2005
 19. Leferink VJ, Zimmerman KW, Veldhuis EF, ten Vergert EM, ten Duis HJ : Thoracolumbar spinal fractures : radiological results of transpedicular fixation combined with transpedicular cancellous bone graft and posterior fusion in 183 patients. *Euro Spine J* 10 : 517-523, 2001
 20. Maiman DJ, Fintar F, Yoganandan N, Reinartz J : Effects of anterior vertebral grafting on the traumatized lumbar spine after pedicle screw fixation. *Spine* 18 : 2423-2430, 1993
 21. McAfee PC, Yuan HA, Fredrickson BE, Lubicky JP : The value of computed tomography in thoracolumbar fractures. *J Bone Joint Surg* 65A : 461-473, 1983
 22. McCormack T, Karaiovic E, Gaines RW : The load-shearing classification of spine fractures. *Spine* 19 : 1741-1744, 1994
 23. McLain RF, Sparling E, Benson DR : Early failure of short segment pedicle instrumentation for thoracolumbar fractures. *J Bone Joint Surg* 73A : 162-167, 1993
 24. Mermelstein LE, McLain RF, Yerby SA : Reinforcement of thoracolumbar burst fractures with calcium phosphate cement. *Spine* 23 : 664-671, 1998
 25. Mumford J, Weinstein JN, Spratt KF : Thoracolumbar burst fractures : The clinical efficacy and outcome of nonoperative management. *Spine* 8 : 955-970, 1993
 26. Oertel J, Niendorf WR, Darwish N, Schroeder HWS, Gaab MR : Limitation of dorsal transpedicular stabilization in unstable fractures of the lower thoracic and lumbar spine : an analysis of 133 patients. *Acta Neurochir (Wien)* 146 : 771-777, 2004
 27. Oner FC, Dhert WJ, Verlaan JJ : Less invasive anterior reconstruction in thoracolumbar fractures. *Injury (Suppl 2)* 36 : B82-89, 2005
 28. Parker JW, Lane JR, Karaiovic E, Gaines RW : Successful short segment instrumentation and fusion for thoracolumbar spine fractures : A consecutive 4 1/2 year series. *Spine* 25 : 1157-1169, 2000
 29. Razak M, Mahmud MM, Hyzan MY, Omar A : Short segment posterior instrumentation, reduction and fusion of unstable thoracolumbar burst fractures - A review of 26 cases. *Med J Malaysia (Suppl 1)* 55 : 9-13, 2000
 30. Resnick DK, Benzel EC : Lateral extracavitary approach for thoracic and thoracolumbar spine trauma : operative complications. *Neurosurgery* 43 : 628-637, 1998
 31. Sanderson PL, Fraser RD, Hall DJ, Cain CMJ, Osti OL, Potter GR : Short segment fixation of thoracolumbar burst fractures without fusion. *Eur Spine J* 8 : 495-500, 1999
 32. Sasso RC, Cotler HB, Reuben JD : Posterior fixation of thoracic and lumbar spine fractures using DC plates and pedicle screws. *Spine* 16S : 134-139, 1996
 33. Schneec CL, Ansell LV : Selection criteria and outcome of operative approaches for thoracolumbar burst fractures with and without neurological deficit. *J Neurosurg* 86 : 48-55, 1997
 34. Shaw B, Mansfield FL, Borges L : One-stage posterolateral decompression and stabilization for primary and metastatic vertebral tumors in the thoracic and lumbar spine. *J Neurosurg* 70 : 405-410, 1989
 35. Sonntag VHR, Hadley MN : Surgical approaches to the thoracolumbar spine. *Clin Neurosurg* 36 : 168-185, 1988
 36. Soshi S, Shiba R, Kondo H : An experimental study on transpedicular spine using AO DC plate internal fixation. *Spine* 14 : 91, 1989
 37. Stephens GC, Devito DP, McNamara MJ : Segmental fixation of lumbar burst fractures with Cotrel-Dubousset instrumentation. *J Spinal Disord* 5 : 344-348, 1992
 38. Verlaan JJ, Diekerson CH, Buskens E, van der Tweel I, Verbout AJ, Dhert WJ : Surgical treatment of traumatic fractures of the thoracic and lumbar spine : a systemic review of the literature on techniques, complications, and outcome. *Spine* 29 : 803-814, 2004

Commentary

The authors reported excellent results of short-segment fixation for thoracolumbar burst fractures especially in aspects of instrumentation failure rate and kyphosis correction. Biomechanically short-segment pedicle fixation is a fixed moment arm cantilever beam fixation, and this type of fixation may result in construct failure at screw-rod interface due to significant load bearing. Disadvantages of short-segment pedicle fixation was early instrument failure and kyphosis progression.

I agree to author's opinion that fixation including injured vertebra showed good results in kyphosis correction and less instrument failure; biomechanically stiffness is significantly increased by adding intermediate screw on injured vertebra. There are still controversy in outcome of short-segment fixation versus long-segment fixation. Although this paper showed excellent results in instrument failure rate and good kyphosis correction, some limitations are present due to short follow-up and small number of patients. We anticipate more papers to confirm the efficacy of short-segment fixation for spinal disorders.

Jae-Won Doh, M.D.

Department of Neurosurgery
Soonchunhyang University Chonan Hospital