

---

가 , 5  
 : 1995 3 2003 8 35 ( 17 , 18 )  
 2 cm  
 dacarbazine (DTIC) 400 mg - 300 IU  
 III , 2002  
 AJCC  
 5  
 : 가 15 (42.8%) 가 5 (14.2%), 2 (5.7%), 2 (5.7%), 5 (14.2%)  
 IA 8 (22.8%), IB 9 (25.7%), IIA 4 (11.4%), IIB 2 (5.7%), IIIA 1 (2.8%), IIIB 2 (5.7%), IIIC 2 (5.7%) IV 7 (20.0%)  
 5 I 94.1%, II 66.8%, III 40%, IV 14.3%  
 : III 5  
 1~3 cm

---



---

: 34

Tel: 051) 990-6467, Fax: 051) 243-0181, E-mail: jdkim@kosinmed.ns.or.kr  
 \*

0.2%

1

가

가 가

가

가 (1,2,7,11)

5

5%

가

80%

가

가

7)

5

(melanocyte)

가

3,6,10)

3,11,18)

1995 3

2003 8

가

35 ( 17 , 18 )

, 2004

6.1

**Table1.** Clinical stage of malignant melanoma (American Joint Committee on Cancer: AJCC 2002)

Stage	Histological Feature/ TMN classification
0	Intraepidermal/in situ melanoma (TisN0M0)
IA	1 mm without ulceration and Clark level II/III (T1aN0M0)
IB	1 mm with ulceration and Clark level IV/V (T1bN0M0)
	1.01~2 mm without ulceration (T2aN0M0)
IIA	1.01~2 mm with ulceration (T2bN0M0)
	2.01~4 mm without ulceration (T3aN0M0)
IIB	2.01~4 mm with ulceration (T3bN0M0)
	> 4 mm without ulceration (T4aN0M0)
IIC	> 4 mm with ulceration (T4bN0M0)
IIIA	Single regional nodal micrometastasis non-ulcerated primary (T1-4aN1M0)
	2~3 microscopic regional nodes, non-ulcerated primary (T1-4aN2aM0)
IIIB	Single regional nodal micrometastasis, ulcerated primary (T1-4bN1aM0)
	2~3 microscopic regional nodes, ulcerated primary (T1-4bN2aM0)
	Single regional nodal macrometastasis, non-ulcerated primary (T1-4aN1bM0)
	2~3 macroscopic regional nodes, non-ulcerated primary (T1-4bN2bM0)
	In-transit met (s)/satellite lesion (s) without metastatic lymph node (T1-4a/bN2cM0)
IIIC	Single microscopic regional noda, ulcerated primary (T1-4bN1bM0)
	2~3 macroscopic regional nodes, ulcerated primary (T1-4bN2bM0)
	4 or more metastatic nodes, matted nodes/gross extracapsular extension, or in-transit mets (s)/satellite (s) and metastatic nodes (any TN3M0)
IV	Distant skin, subcutaneous or nodal mets with normal LDH (anyTanyNM1a)
	Lung mets with normal LDH (anyTanyNM1b)
	All other visceral mets with normal LDH or any distant mets with increased

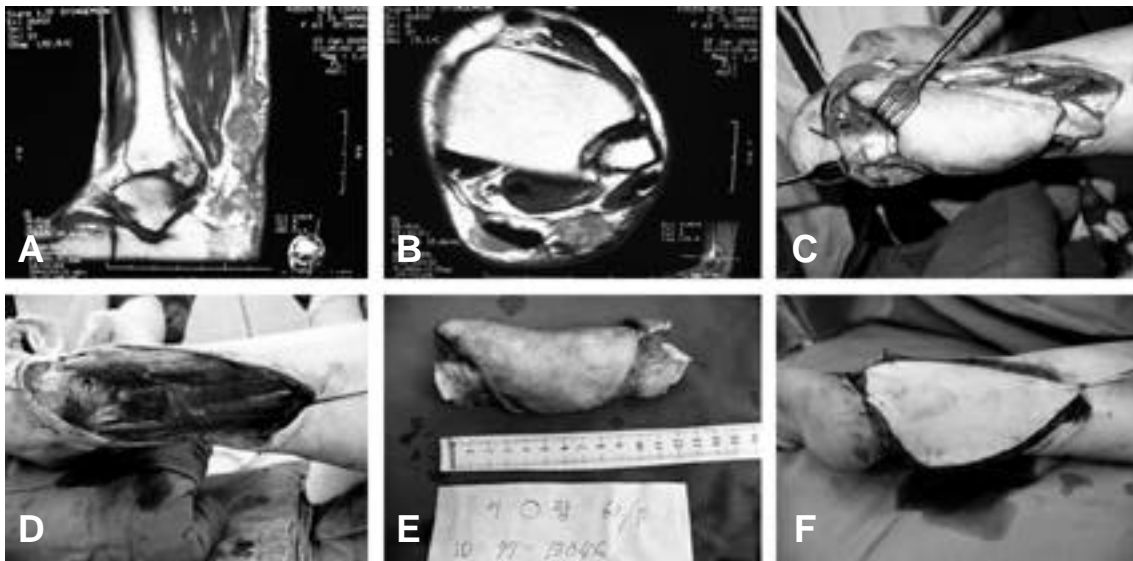
AJCC (American Joint Committee on Cancer) system<sup>5)</sup>  
 (Table 1), 가 stage IIC  
 Breslow 1 mm 1  
 2 mm, 2 4 mm, 4 mm 34 71  
 , a,b 55.2 . 29 (82.8%)  
 가 III ,  
 A, B, C , IV ,  
 가 가 6 (17.1%) .  
 1 가 35 23 (65.7%) 가  
 , 2 3 가 7 (20.0%), 6 1  
 2 cm , III 3 (8.6%), 3 2 (5.7%) .  
 35 17 , 11  
 , 6  
 dacarbazine (DTIC) 400 mg 13 , 5  
 - 300 IU 6  
 8 ,  
 Hydration 7 4 6 3 ,  
 III 1 .  
 , II (stage) IA 8 (22.8%),  
 가 IB 9 (25.7%), IIA 4 (11.4%), IIB 2  
 (5.7%), IIIA 1 (2.8%), IIIB 2 (5.7%),  
 가 IIC 2 (5.7%) IV 7 (20.0%)  
 , 3 .

**Table 2.** Recurrence and metastasis of melanoma

unit: cases (%)

Stage	No Recurrence	Local Recurrence	Reginal Metastasis	Distant Metastasis
IA	7 (87.5)	1 ( 12.5)	0 ( 0.0)	0 ( 0.0)
IB	8 (88.9)	1 ( 11.1)	1 (11.1)	0 ( 0.0)
IIA	2 (50.0)	1 ( 25.0)	1 (25.0)	0 ( 0.0)
IIB	1 (50.0)	1 ( 50.0)	0 ( 0.0)	1 (50.0)
IIC	-	-	-	-
IIIA	0 ( 0.0)	1 (100.0)	0 ( 0.0)	1 (100.0)
IIIB	1 (50.0)	1 ( 50.0)	0 ( 0.0)	1 ( 50.0)
IIIC	1 (50.0)	1 ( 50.0)	0 ( 0.0)	1 ( 50.0)
IV	1 (14.3)	6 ( 85.7)	0 ( 0.0)	6 ( 85.7)

. IA 8 7 가 가 14  
 (87.5%) , . I II  
 1 (12.5%) . IB 9 5  
 가 가 1 (11.1%) , IA 8 5 가  
 , IIA 4 1 (25.0%) , 1  
 가 가 1 (25.0%) . IIB . 5 5 4 가  
 2 1 7 가 80% , 3  
 , IIIA 1 1 , IIIB 2 1 . IB 9 5  
 , IIIC 2 1 ,  
 가 , IV 7 6 가 .  
 (85.7%) 가 가 1  
 (Table 2). 25% ,  
 69.8 , 5 75% . IIA 4 2  
 IA 100% IB 88.9% I 5 , 가  
 94.1% , IIA 75.0% ,  
 IIB 50.0% II 66.7% . IIIA 가 1 . IIB 2  
 100%, IIIB 50%, IIIC 0% III ,  
 40% 5 IV 7 6 .  
 14.3% 5 . 35 24 (68.5%)  
 III , I II (42.8%) , 5 (14.2%) , 2



**Fig. 1.** 63 year-old female was surgical operated for malignant melanoma at ankle left and treated immunochemotherapy. After 2 years later, malignant melanoma was local recurred with tendocalcaneus. Reoperation was done by wide excision and recycled autogenous tendocalcaneus graft with extracorporeal irradiation and free flap. (A and B) are MR images after recurrence. (A) Axial T1 weighted MR image. (B) Coronal T1 weighted MR image. (C, D, E, F) are operation findings.

(5.7%), 2 (5.7%), 1  
 11 (31.4%) 5  
 (14.2%), 3 (8.6%), 2 (5.7%), 가 Rhee<sup>18)</sup> 1 3  
 1 (2.9%) 5 cm  
 3 , Maurice Y.<sup>17)</sup>  
 melanoma in situ 5 mm , 1  
 mm 1 cm, 1~2 mm 1~2 cm, 2~4  
 mm 2 cm ,  
 가 2 , IV가 1 , 가 4 mm 2 cm  
 2 IA 1 IV 1 , Webster<sup>21)</sup> 4 mm  
 2 cm 4 cm  
 가 19 (73.1%) ,  
 가 24 (92.3%),  
 6 (23.1%) .  
 2 (7.6%),  
 1 (3.8%) .  
 가 ,  
 가 2 cm Balch<sup>5)</sup> 5  
 , IIB  
 가 , III ,  
 가  
 가 4 mm 2 cm  
 가 , (sentinel lymph node  
 biopsy; SLNB) 1,12,13,  
 가 13-15)  
 가 16,19,20) 1990  
 Morton<sup>3)</sup>  
 B-cell lymphoma (delayed lymph node dissection;  
 derived protein 2(Bcl-2) Bcl-xL DLND)  
 (apoptosis)  
 10,19)  
 가 , , , , ,  
 11,14),  
 가  
 , 가  
 가 4 mm  
 Clark Breslow 가 4,6) 12)  
 Clark 가  
 가 , Breslow  
 가  
 , dacarbazine - 5  
 , III 40%, IV 14.3%  
 4,5,6), Breslow Balch<sup>5)</sup> III 45%, IV

11%

I, II

III

가  
가

AJCC

III

5

40%

가

Breslow

1 mm

1

cm, 1~4 mm

2 cm, 4 mm

3

cm

가

REFERENCES

1) **Ackerman LV** Malignant melanoma of the skin, *Amer J Clin Path*, 18:602-604, 1948.  
 2) **Alexander M.M.** Eggermont European approach to the treatment of malignant melanoma, *Current Opinion in Oncology*, 14:205-211, 2002.  
 3) **Bostick PJ, Morton DL, Turner RR, Huynh KT and Wang HJ**: Prognostic significance of occult metastases detected by sentinel lymphadenectomy and reverse transcriptase-polymerase chain reaction in early -stage melanoma patients. *J Clin Oncol*, 17:3228-3244, 1999.  
 4) **Breslow A**: Thickness, cross-sectional areas and depth of invasion in the prognosis of cutaneous melanoma. *Ann Surg*, 172:902-908, 1970.  
 5) **Charles M.** Balch The new melanoma staging system, *European Journal of Cancer*, 37(6): S6, 2001.  
 6) **Clark WH**: A classification of malignant melanoma in man correlated with histogenesis and

biologic behavior. *Adv Biol Skin*, 8:621-647, 1967.  
 7) **Elwood J.M.** Melanoma and sun exposure. *Semin Oncology*, 23:650, 1996.  
 8) **Fletcher WS, Pommier RF, Lum S and Wilmarth TJ**: Surgical treatment of metastatic melanoma. *Am J Surg*, 175:413-417, 1998.  
 9) **Jiachun X, Kung, A. Bernard Ackerman BX**: A critique of the most recent(2002) system propped by cancer, *Am J Dermatology*, 27(2): 165-167, 2005.  
 10) **John F Thompson, Richard A Scolyer and Richard F Kefford**: Cutaneous melanoma. *The Lancet*, Volume, 365(9460): 687-701, 2005  
 11) **Kim DS and Kim BJ**: Malignant melanoma : 2 case report. *J of Korean Orthop Assoc*, 11:397-402,1976.  
 12) **Larg PG Jr**: Malignant melanoma. *Med Clin North AM*, 82:1325-1358, 1998.  
 13) **Lieber KA, Standiford SB, Kuvshinor BW and Ota** Surgical management of aberrant sentinel lymph node drainage in cutaneous melanoma. *Surgery*,124:757-761, 1998.  
 14) **Lim CW**: Melanoma. In : *Dermatology* . 3rd ed. *J of Korean Dermatol*, 452-456, 1994.  
 15) **Matthew F. Kalady Rebekah R. White, Jeffrey L. Johnson, Douglas S. Tyle, Hillad F. B** Thin Melanomas Predictive lethal characteristics from a 30-year clinical experience. *Annals of Surgery*, 238(4): 221-230, 2003.  
 16) **Matthew T. Ballo Gunar K. B A** Critical assessment of adjuvant radiotherapy for inguinal lymph node metastasis from melanoma. *Annals of Surgical Oncology*, 11(12): 1097-1084, 2004.  
 17) **Maurice Y. B** Melanoma Clinics in Plastic Surgery, 32: 249-259, 2005.  
 18) **Seung-Koo Rhee, Yong-Koo Kang, Won-Jong Park, Yang-Guk Chung, Hyuk-Je Lee**: Malignant Melanoma. *J Korean Bone & Joint Tumor Soc*, 7: 13-19, 2001.  
 19) **Tuker M.A.** Clinically recognized dysplastic nevi A central risk factor for cutaneous melanoma, *JAMA*, 277:1439, 1997.  
 20) **Wagner JD, Gordon MS, Chuang TY and Coleman JJ 3rd**: Current therapy of cutaneous melanoma. *Plast Reconstr Surg*, 105:1774-1799, 2000.  
 21) **Webster JP, Stevenson TW and Stout**: The surgical treatment of malignant melanoma of skin. *Surg Clin N Amer*, 24 : 319-339, 1944.

## Analysis of Treatment and Prognosis in Malignant Melanoma

Young Ho Kwon, M.D., Jeong Ryoul Kim, M.D., Young Gu Lee, M.D., Jae Do Kim, M.D.

*Department of Orthopedic Surgery, Kosin University Gospel Hospital, Busan, Korea*

**Purpose:** The most important thing in curing Malignant melanoma is surgical excision, operating method is wide excision. The author et al. studied 5-year survival rate of each stage and appropriate surgical margin after operating wide excision and immuno-chemotherapy.

**Materials and methods:** From March 1995 to August 2003, wide excision and immuno-chemotherapy were operated to 35 patients (17 males and 18 females) who were diagnosed as malignant melanoma and followed up.

Excision was done around 2 cm from edge of tumor regardless of the size or effected degree of the skin, and flap or full thickness skin graft was used for skin deficit that was not covered after excision. As for immuno-chemotherapy, method that prescribes 400 mg of dacarbazine (DTIC) and 3 million IU of interferone- in combination was used. Immuno-chemotherapy was operated to patients in over stage III. We used AJCC stage that was revised in 2002.

Local recurrence, local metastasis and distant metastasis were investigated for these patients as well as the 5-year survival rate of each stage.

**Results:** Most frequently 15 cases(42.8%) occurred in foot, 5 cases(14.2%) occurred in ankle, 2 cases(5.7%) in leg, 2 cases(5.7%) in thigh and 5 cases(14.2%) in hand.

The incidence of each stage were 8 cases(22.8%) in IA, 9 cases(25.7 %) in IB, 4 cases(11.4%) in IIA, 2 cases(5.7%) in IIB, 1 cases(2.8%) in IIIA, 2 cases(5.7%) in IIIB, 2 cases(5.7%) in IIIC and 7 cases(20.0%) in stage IV.

5-year survival rate of each stage were 94.1% in stage I, 66.8% in stage II, 40% in stage III and 14.3% in stage IV.

**Conclusion:** 5-year survival rate of stage IV was low in malignant melanoma. In treatment of malignant melanoma, staging before operation is important as operation methods are different from each stage. We recommend wide excision which remove around 1 ~ 3 cm from margin of tumor up to each thickness

**Key Words:** Malignant melanoma, Wide excision, Immuno-chemotherapy

**Address reprint requests to**

Jae Do Kim, M.D.

Department of Orthopedic Surgery, Kosin University Gospel Hospital

Am-Nam Dong 34, Seo-Gu, Busan, Korea

TEL: 82-51-990-6467, Fax: 82-51-243-0181, E-mail: jdkim@kosinmed.ns.or.kr