

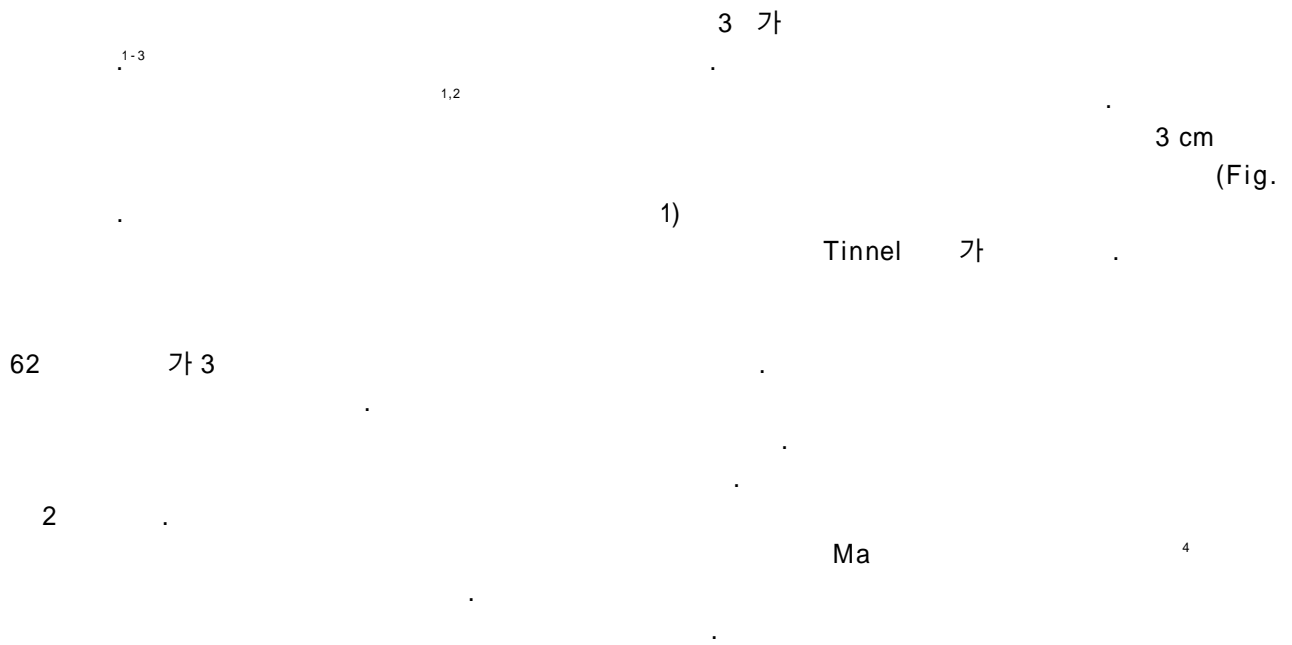
## A Case of Posterior Antebrachial Cutaneous Neuropathy After Injection Therapy

Jong Seok Bae, M.D., Min Uk Jang, M.D., Min Ky Kim, M.D.,  
Gyong Jae Yoon, M.D.\*, Byoung Joon Kim, M.D.†

Department of Neurology and Department of Rehabilitation Medicine\*, Seoul Medical Center,  
Department of Neurology Samsung Medical Center Sungkyunkwan University School of Medicine†, Seoul, Korea

Isolated posterior antebrachial cutaneous (PABC) neuropathy is rare. A 62 year-old man presented with hypesthesia over the skin region of PABC nerve territory after an injection at the proximal to the lateral epicondyle. Antidromic sensory nerve conduction studies of PABC nerve was not evoked on the affected side. Our case showed that sensory nerve conduction of PABC nerve can be performed without much difficulty and that this test is useful in confirming PABC neuropathy.

**Key Words:** Posterior Antebrachial Cutaneous Nerve, Injection, Neural Conduction



Address for correspondence

**Byoung Joon Kim, M.D., Ph.D.**

Department of Neurology, Samsung Medical Center,  
Sungkyunkwan University School of Medicine,  
50 Irwon-dong, Gangnam-gu, Seoul, 135-710, Seoul, Korea,  
Tel: +82-2-3410-3594 Fax: +82-2-3410-0052  
E-mail : bjkim@smc.samsung.co.kr

가 (Fig. 2).  
(Extensor digitorum communis), (brachioradialis)



## REFERENCES

1. Chang CW, Oh SJ. Posterior antebrachial cutaneous neuropathy. Case report. *Electromyogr Clin Neurophysiol* 1990;30:3-5.
2. Doyle JJ, David WS. Posterior antebrachial cutaneous neuropathy associated with lateral elbow pain. *Muscle Nerve* 1993;16:1417-1418.
3. Chang CW, Cho HK, Oh SJ. Posterior antebrachial cutaneous neuropathy: case report. *Electromyogr Clin Neurophysiol* 1989;29:109-111.
4. Oh SJ. Uncommon nerve conduction studies. In: Oh SJ?ditor. *Clinical electromyography nerve conduction studies*. 3rd ed. Philadelphia:Lippincott Williams & Wilkins,2003;151-309.
5. Prakash KM, Leoh TH, Dan YF, Nurjannah S, Tan YE, Xu LQ, et al. Posterior antebrachial cutaneous nerve conduction studies in normal subjects. *Clin Neurophysiol* 2004;115:752-754.
6. Horowitz SH. Iatrogenic causalgia. Classification, clinical findings, and legal ramifications. *Arch Neurol* 1984;41:821-824.
7. Ling CM, Loong SC. Injection injury of the radial nerve. *Injury* 1976;8:60-62.