

가

---

## Bilateral Femoral Neuropathy Combined with Multifocal Abscesses

Chul Hyun Kim, M.D., Yang Soo Lee, M.D., Seung Deuk Byun, M.D., Zee Ihn Lee, M.D.\*

*Department of Rehabilitation Medicine, School of Medicine, Kyungpook National University  
Department of Rehabilitation Medicine, School of Medicine, Catholic University of Daegu\**

We report a 29-year old female who developed bilateral femoral neuropathy combined with multiple abscesses in both thigh muscles. She was present with weakness in both lower extremities for 15 days and intermittent chilling sense for 3 months. Nerve conduction study showed complete absence of compound muscle action potentials in bilateral femoral nerves when stimulated at inguinal area. Electromyographic examination revealed no motor unit action potentials in both rectus femoris and vastus medialis muscles. CT revealed multifocal abscesses in bilateral thigh muscles. After antibiotic treatment, the patient's neurologic symptoms were improved.

**Key Words:** Bilateral femoral neuropathy, Multifocal abscesses

---

15  
가 (Table 1).  
14 cm  
(Table 1).  
가 가  
29 3 가  
15  
(Table 2).  
3-4 (Fig. 1),  
2  
2  
가 4/5, 4/5, 0/5  
(Table 1, 2).

---

Address for correspondence

**Zee Ihn Lee, M.D.**

Department of Rehabilitation Medicine, School of Medicine,  
Catholic University of Daegu

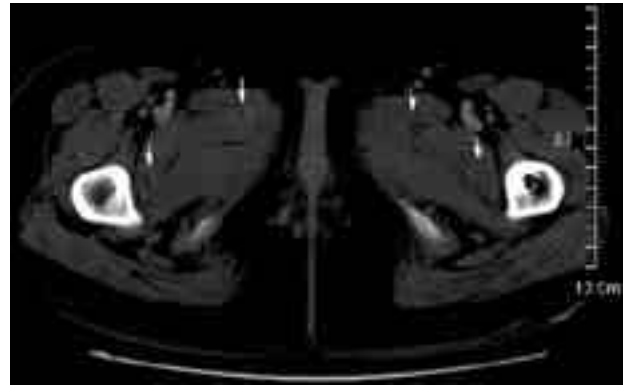
3056-6 Daemyung 4-dong, Nam-gu, Daegu, 705-718, Korea

Tel: +82-53-650-4688 Fax: +82-53-622-4688

E-mail : zilee@cu.ac.kr

(lithothomy position)

가 . 2 가  
 가 , 가  
 (vasa  
 nervorum)  
 .<sup>2-5</sup> Hickman<sup>6</sup>  
 가  
 . White<sup>7</sup>  
 가  
 1  
 4 cm  
 가



**Figure 1.** Pelvis computed tomography showing multiple abscesses in both thigh adductor muscles (arrow).

**Table 1.** Results of Nerve Conduction Study

Nerve	Latency (msec)		Amplitude	
	Onset 15th day	2 months later	Onset 15th day	2 months later
Femoral motor				
Right	No response	5.10	No response	5.22 mV
Left	No response	8.16	No response	0.49 mV
Saphenous				
Right	4.16	4.12	5.22 $\mu$ V	7.28 $\mu$ V
Left	4.36	4.30	4.32 $\mu$ V	4.45 $\mu$ V

**Table 2.** Results of Electromyography

Muscles	Fib*		PSW <sup>†</sup>		MUAP <sup>‡</sup>		Recruitment	
	15th day <sup>§</sup>	2 mos	15th day <sup>§</sup>	2 mos	15th day <sup>§</sup>	2 mos	15th day <sup>§</sup>	2 mos
Rt. rectus femoris	- / -	- / -	- / -	- / -	- / Polyphasic	- / -	- / decrease	- / -
Rt. vastus medialis	- / -	- / -	- / -	- / -	- / Polyphasic	- / -	- / decrease	- / -
Rt. iliacus	- / -	- / -	- / -	- / -	Normal / Normal	Normal / Normal	full / full	full / full
Lt. rectus femoris	- / 2+	- / 2+	- / 1+	- / 1+	- / Polyphasic	- / -	- / decrease	- / -
Lt. vastus medialis	- / 2+	- / 2+	- / 1+	- / 1+	- / Polyphasic	- / -	- / decrease	- / -
Lt. iliacus	- / -	- / -	- / -	- / -	Normal / Normal	Normal / Normal	full / full	full / full

\*Fib: Fibrillation Potentials

<sup>†</sup>PSW: Positive Sharp Wave

<sup>‡</sup>MUAP: Motor Unit Action Potential

<sup>§</sup>15th day: Onset 15th day

2 mos: 2 months later

## REFERENCES

1. Lee SH, Kim KH, Jo GY. Bilateral Femoral Neuropathy Secondary to Unilateral Retroperitoneal Hematoma. *J Korean Acad Rehab Med* 2001;25:168-172.
2. Lejman T, Strong M, Michno P. Septic arthritis of the shoulder during the first eighteen months of life. *J Pediatr Orthop* 1994;15:172-175.
3. Lejman t, Strong M, Nichno P. Radial nerve palsy associated with septic shoulder in neonates. *J Pediatr Orthop* 1995;15:169-171.
4. Clay SA. Osteomyelitis as a cause of brachial plexus neuropathy. *Am J Dis Child* 1982;136:1054-1056.
5. Gabriel SR, Thometz JG, Jaradeh S. Septic arthritis associated with brachial plexus neuropathy: A case report. *J Bone Joint Surg Am* 1996;78:103-105.
6. Hickman SJ, Godwin-Austen RB, Henderson LM. Poststreptococcal neuropathy. *J Neurol Neurosurg Psychiatry* 1999;66:690-691.
7. White AA III, Crelin ES, McIntosh S. Septic arthritis of the hip joint secondary to umbilical artery catheterization associated with transient femoral and sciatic neuropathy. *Clin Orthop* 1974;100:190-194.
8. Hakim MA, Katirji MB. Femoral mononeuropathy induced by the lithotomy position: A report of 5 cases with a review of literature. *Muscle Nerve* 1993;16: 891-895.
9. Liveson JA. *Peripheral neurology: Case studies in electrodiagnosis*. 2nd ed. Philadelphia: FA Davis. 1991;46-48.